

## Assessment of Pterygomaxillary Region for Insertion of Pterygoid Implants - A Cone Beam Computed Tomography (CBCT) Study

Research Article

Baburajan Kandasamy<sup>1\*</sup>, R Naveen Reddy<sup>2</sup>, Majo Ambooken<sup>3</sup>, Jeethu John Jerry<sup>4</sup>

<sup>1</sup> Professor and HOD, Department of Prosthodontics, RVS Dental College and Hospital, Coimbatore, Tamilnadu, India.

<sup>2</sup> Assistant Professor, Department of Prosthodontics, College of Dentistry, Jazan University, Saudi Arabia.

<sup>3</sup> Professor and HOD, Department of Periododontics Oral Implantology, Mar Baselios Dental College, Kothamangalam, 686691, Kerala, India.

<sup>4</sup> Reader, Department of Periodontics, Malabar Dental College and Research Centre, Eddappal, Malappuram, Kerala, India.

### Abstract

**Background:** Recently pterygoid implants have revolutionized the field of implant dentistry. This study was done to assess pterygomaxillary region for pterygoid implants using cone beam computed tomography (CBCT).

**Materials & Methods:** 62 patients (dentate and edentulous) selected for pterygoid implants were undergone for cone beam computed tomography (CBCT) evaluation of the pterygomaxillary region. Joint height, width, bone volume was calculated. Bone density was measured at two points each at the superior part, medium and on inferior part of the pterygomaxillary column.

**Results:** We found mean  $\pm$  SD height of pterygomaxillary joint (dentate- $12.9 \pm 7.3$  mm, edentulous-  $12.5 \pm 7.1$  mm), the mean width of pterygomaxillary joint (dentate-  $8.16 \pm 7.2$  mm, edentulous-  $8.16 \pm 7.2$  mm). The mean volume of pterygomaxillary joint in dentate patients was  $288.4 \pm 194.2$  mm<sup>3</sup> and edentulous was  $256.6 \pm 172.4$  mm<sup>3</sup>. There was significantly higher bone density in dentate patients as compared to edentulous patients ( $P < 0.05$ ).

**Conclusion:** Bone density was found to be higher in dentate as compared to edentulous patients. CBCT is a new diagnostic tool which assess pterygoid region effectively. Pterygoid implants may be considered as treatment option for atrophic maxilla.

**Keywords:** Cone Beam Computed Tomography; Edentulous; Pterygoid Implants.

### Introduction

Teeth are necessary for eating and for esthetics. Loss of teeth can lead to poor profile and diminished mastication. Replacement of missing teeth with complete denture or with removable and fixed partial denture solves the purpose [1]. However, selection of artificial prostheses is the choice of patient and dentist preference. Missing maxillary posterior teeth have negative impact on alveolar bone [2]. There has been loss of vertical bone height in long standing edentulism. Research have demonstrated that ageing also contribute to decrease bone height. Pneumatization of maxillary sinus in edentulous site is quite obvious. Replacement of missing teeth in maxillary posterior region remains a challenge for dentist [3].

The quality and quantity of bone determines the success of prosthetics. Dental implants have become popular worldwide.

Though, the success rate of dental implants is quite high, the insertion of dental implant in maxillary posterior region is still considered to be challenging. Type IV bone and insufficient bony dimensions are considered to be limiting factors. In cases of less vertical height, direct or indirect sinus lift is possible. However, it cannot be performed in all cases [4]. Short dental implants are other alternative treatment options in such cases. Recently pterygoid implants have revolutionized the field of implant dentistry. It has overcome the shortcomings of maxillary posterior implants [5]. They are substitute for conventional and tuberosity implants. The insertion of pterygoid implants is technique sensitive. Dental surgeon should be aware of anatomical landmarks such as pterygomaxillary fossa and maxillary artery. Careful assessment of greater palatine nerve is essential to prevent iatrogenic injuries [6]. Radiographic evaluation of pterygomaxillary region provides useful information before planning implants in this region. Two dimensional radiographs such as panoramic radiographs do not

#### \*Corresponding Author:

Baburajan Kandasamy,  
Professor and HOD, Department of Prosthodontics, RVS Dental College and Hospital, Coimbatore, Tamilnadu, India.  
E-mail: baburajankandasamy@gmail.com

**Received:** October 18, 2020

**Accepted:** November 06, 2020

**Published:** November 11, 2020

**Citation:** Baburajan Kandasamy, R Naveen Reddy, Majo Ambooken, Jeethu John Jerry. Assessment of Pterygomaxillary Region for Insertion of Pterygoid Implants - A Cone Beam Computed Tomography (CBCT) Study. *Int J Dentistry Oral Sci.* 2020;S9:02:001:1-4. doi: <http://dx.doi.org/10.19070/2377-8075-S102-09001>

**Copyright:** Baburajan Kandasamy<sup>©</sup>2020. This is an open-access article distributed under the terms of the Creative Commons Attribution License, which permits unrestricted use, distribution and reproduction in any medium, provided the original author and source are credited.

provide necessary information. The use of cone beam computed tomography (CBCT) in implant planning may be helpful in ensuring success of pterygoid implants [7]. This study was conducted to assess pterygomaxillary region for pterygoid implants using cone beam computed tomography (CBCT).

## Materials and Methods

This study was conducted in Department of Prosthodontics and Oral Implantology on 62 patients of both genders selected for pterygoid implants, after obtaining ethical clearance from ethical committee of the institute. Patients selected for the study were well informed in vernacular language and their consent was obtained. The time period of the study was April 2018 to November 2019. Inclusion criteria were dentate or edentulous patient age ranged 18-58 years and patients with poor quantity and quality of bone in maxillary posterior and tuberosity region. Exclusion criteria were history of diabetes, hypertension, traumatic injury to the region, non-diagnostic CBCT images.

Demographic profile such as name, age, gender etc. of each patient was recorded. Assuming (p) = 90 as the incidence of implant

survival with 9% margin of error, formula used was  $n = \frac{Z_{\alpha/2}^2 pq}{d^2}$

where p is implant survival, q = 1 - p, d is the margin of error,  $Z_{\alpha/2}$  is the ordinate of standard normal allocation at  $\alpha\%$  level of implication. A sample of 62 was selected. All selected patients underwent oral examination by dental surgeon. Depending upon the side, patients were subjected to cone beam computed tomography (CBCT) of the pterygomaxillary region.

All patients were made to remove artificial prostheses, necklace, ear rings or any metallic object in head and neck region. Patient's frankfurt horizontal plane was adjusted parallel to the floor and were advised to bite on bite block. Newtom CBCT machine was

used for the study. Sectional CBCT was taken by adjusting parameters at 100 kVp, 10 mA and exposure time of 18 seconds. Image resolution was 0.3 $\mu$ m. After obtaining the primary image, multi-planar reformation was done. All the planes such as axial, coronal and sagittal planes were obtained.

Joint height ie pterygomaxillary column between the most cranial and caudal points of the pterygomaxillary joint was calculated (Fig- 1). Joint width of the pterygoid process calculated (Fig- 2). Bone density was measured at two points each at the superior part, medium and on inferior part of the pterygomaxillary column in gray scale values (GSD). Total bone volume was also calculated (mm<sup>3</sup>). All the CBCT image analysis was performed by two independent radiologists using Newtom new technology (NNT) software.

## Statistical Analysis

Data thus obtained were entered in MS excel sheet for statistical analysis using IBM SPSS® (version 20.0). Joint height and width, bone volume were expressed as mean  $\pm$  SD. Bone density were expressed in GSD. Kolmogorov-Smirnov test was used for comparing the parameters. Level of significance was set below 0.05.

## Results

Table 1 shows that there were 38 (61.2%) dentate and 24 (38.8%) were completely edentulous patients. In dentate patients, males were 20 (52.6%) and females were 18 (47.4%) and in completely edentulous patients, males were 14 (58.3%) and females were 10 (41.7%).

Table 2, graph 1 shows that the mean  $\pm$  SD height of pterygomaxillary joint in dentate patients was 12.9  $\pm$  7.3 mm and in edentulous patients was 12.5  $\pm$  7.1 mm. The mean width of pterygomaxillary joint in dentate patients was 8.16  $\pm$  7.2 mm and

Figure 1. Height of pterygomaxillary process in sagittal plane.



Figure 2. Width of pterygomaxillary process in axial plane.

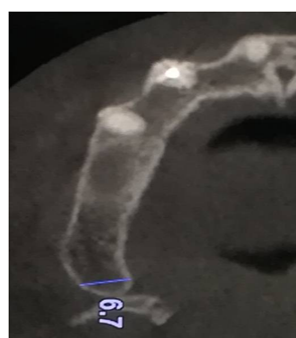


Table 1. Distribution of patients.

Gender	Dentate (38)	Completely edentulous (24)
Male	20 (52.6%)	14 (58.3%)
Female	18 (47.4%)	10 (41.7%)

Table 2. Measurement of parameters in dentate and edentulous patients.

Parameters (Mean)	Dentate		Edentulous		P value
	Mean	SD	Mean	SD	
Height of pterygomaxillary joint	12.9	7.3	12.5	7.1	0.17
Width of pterygomaxillary joint	8.16	7.2	7.46	6.1	0.01
Volume of pterygomaxillary joint	288.4	194.2	256.6	172.4	0.001

Table 3. Measurement of bone densities in dentate and edentulous patients.

Region	Dentate		Edentulous		P value
	Mean	SD	Mean	SD	
Superior section					
AL	462.4	120.4	438.2	112.2	0.05
PMJ	564.2	131.2	520.2	142.4	0.01
PL	702.8	104.2	668.6	106.2	0
Middle section					
AL	484.6	94.2	406.8	110.2	0.04
PMJ	624.8	88.6	520.4	94.6	0.001
PL	718.4	82.4	652.2	82.4	0.01
Inferior section					
AL	378.4	84.4	350.2	94.6	0.05
PMJ	534.2	94.2	588.8	92.4	0.03
PL	664.2	96.6	630.4	99.2	0.05

AL - anterior limit, PMJ, Pterygomaxillary Joint, PL, Posterior limit

in edentulous patient was  $8.16 \pm 7.2$  mm and in edentulous patients was  $7.46 \pm 6.1$  mm. The mean volume of pterygomaxillary joint in dentate patients was  $288.4 \pm 194.2$  mm<sup>3</sup> and edentulous was  $256.6 \pm 172.4$  mm<sup>3</sup>. There was significant difference in width and volume of pterygomaxillary joint in dentate and edentulous patients ( $P < 0.05$ ).

Table 3 shows that in dentate patients, at superior section, mean bone density (GSD) at anterior limit of the pterygoid process was 462.4 and in edentulous patients was 438.2, at pterygomaxillary joint was 564.2 in dentate patients and 520.2 in edentulous patients, at posterior limit in dentate patients was 702.8 and in edentulous patients was 668.6. At middle section, mean bone density (GSD) at anterior limit of the pterygoid process dentate patients was 484.6 and in edentulous patients was 406.8, at pterygomaxillary joint was 624.8 in dentate patients and 652.2 in edentulous patients, at posterior limit in dentate patients was 718.4 and in edentulous patients was 652.2. At inferior section, mean bone density (GSD) at anterior limit of the pterygoid process in dentate patients was 378.4 and in edentulous patients was 350.2, at pterygomaxillary joint was 534.2 dentate patients and 588.8 in edentulous patients, at posterior limit in dentate patients was 664.2 and in edentulous patients was 630.4. The difference was

significant ( $P < 0.05$ ).

## Discussion

Dental implants insertion in maxillary posterior region remains a topic of discussion. Most of the dental surgeon prefers direct or indirect sinus lift, use of bone grafts or short implants owing to diminished bone height. All these surgical interventions require long healing periods. There is larger fatty marrow space and of cortical bone covering the alveolus in maxillary posterior region [8]. Moreover, the use of longer posterior cantilevers may lead to fracture of prosthesis and failure of osseointegration. Pterygoid implants may be used in patients with less bone dimension in maxillary posterior region. The success of pterygoid implants depends on clinical skill and expertise of the dental surgeon [9]. This study utilized cone beam computed tomography (CBCT) in assessing pterygomaxillary region for placement of pterygoid implants.

There were there were 34 males and 28 females. Of this, 20 (52.6%) males and 18 (47.4%) females were dentate and 14 (58.3%) males and 10 (41.7%) females were edentulous. Lee et al., [9] found 13.1 mm of the height of the pterygopalatine suture in

study patients. We found that the mean height of pterygomaxillary joint was 12.7 mm. The mean height in edentulous patients was 12.9 mm and in completely edentulous patients was 12.5 mm. Dentate patients had more mean height as compared to edentulous patients. However, the difference was non-significant.

We observed that mean width of pterygomaxillary joint was 7.81 mm. In dentate patients, it was 8.16 mm and in edentulous patients was 7.86 mm. Our results are in consistency with the results obtained in study by Chin et al., [10] Curi et al., [11] evaluated 3 years' survival rate of 238 pterygoid implants in 56 patients. They found that the survival rate of pterygoid implants was 99% and prosthesis survival rate was 97.7%.

We found that the mean volume of pterygomaxillary joint was 272.5 mm<sup>3</sup>. It was 288.4 mm<sup>3</sup> in dentate patients and 256.6 mm<sup>3</sup> in edentulous patients which was statistically significant ( $P < 0.05$ ). Rodríguez et al., [12] in their study assessed 202 CBCT images of pterygoid region. Density in the tuberosity region varies from 285.8 to 329.1 DV units and density in the pterygoid plate area from 602.9 to 661.2 DV units. Authors found that the density in the pterygoid area was 139.2% greater than in the tuberosity zone. In present study we found that mean bone density at middle section was maximum followed by superior section and inferior section. Middle section provides anchorage for pterygoid implants. In our study values were slightly higher. It was higher in dentate patients as compared to edentulous patients. This is due to the fact that dentate patients have greater muscular strength which develops into a mayor osseous density.

Balshi et al., [13] in their study evaluated 1817 implants in the completely edentulous maxillae of 189 patients which were inserted into the pterygomaxillary area, and all patients were restored with complete-arch fixed detachable prostheses. The survival rate of pterygoid implants found to be 88.2% in edentulous maxillary arches. Valerón et al., [14] found a success rate of 94.7% in 152 implants placed in pterygomaxillary pyramidal region. Authors suggested that pterygoid implants can be effectively used in place of conventional and zygomatic implants. Bidra et al., [15] in their systematic review suggested that pterygoid implants offer higher survival and success rate as compared to conventional implants.

In present study cone beam computed tomography (CBCT) was used. CBCT offers advantages over two dimensional radiographs such as orthopantomography (OPG). CBCT is useful in providing three dimensional images. All the planes can be utilized for assessing potential implant site. Pre- surgical determination of pterygomaxillary region with CBCT is effective in reducing complications of incorrect dental implant insertion. Moreover, CBCT reduces patients exposure significantly as compared to CT scan [16, 17].

The limitation of the study is small sample size. The angulation of pterygoid implants in pterygoid region was not determined.

## Conclusion

Bone density was found to be higher in dentate as compared to edentulous patients. CBCT is a new diagnostic tool which assess pterygoid region effectively. Pterygoid implants may be considered as treatment option for atrophic maxilla.

## References

- [1]. Jivraj S, Chee W, Corrado P. Treatment planning of the edentulous maxilla. *Br Dent J.* 2006 Sep;201(5):261-79.
- [2]. Tadinada A, Fung K, Thacker S, Mahdian M, Jadhav A, Schincaglia GP. Radiographic evaluation of the maxillary sinus prior to dental implant therapy: A comparison between two-dimensional and three-dimensional radiographic imaging. *Imaging Sci Dent.* 2015 Sep;45(3):169-74. Pubmed PMID: 26389059.
- [3]. Candel E, Peñarrocha D, Peñarrocha M. Rehabilitation of the atrophic posterior maxilla with pterygoid implants: a review. *J Oral Implantol.* 2012 Sep;38:461-6. Pubmed PMID: 21568718.
- [4]. Apinhasmit W, Methathrathip D, Ployubtim S, Chompoong S, Ariyawatkul T, Lertsirithong A. Anatomical study of the maxillary artery at the pterygomaxillary fissure in a Thai population: its relationship to maxillary osteotomy. *J Med Assoc Thai.* 2004 Oct;87(10):1212-7. Pubmed PMID: 15560700.
- [5]. Scarfe WC, Farman AG, Sukovic P. Clinical applications of cone-beam computed tomography in dental practice. *J Can Dent Assoc.* 2006 Feb 1;72(1):75.
- [6]. Balshi TJ, Wolfinger GJ, Slauch RW, Balshi SF. Brånemark system implant lengths in the pterygomaxillary region: a retrospective comparison. *Implant Dent.* 2013 Dec;22(6):610-2. Pubmed PMID: 24177279.
- [7]. Graves SL. The pterygoid plate implant: a solution for restoring the posterior maxilla. *Int J Periodontics Restorative Dent.* 1994 Dec;14(6):512-23. Pubmed PMID: 7751116.
- [8]. Balshi TJ, Wolfinger GJ, Balshi SF. Analysis of 356 pterygomaxillary implants in edentulous arches for fixed prosthesis anchorage. *Int. J. Oral Maxillofac. Implants.* 1999 Jun;14(3):398-406.
- [9]. Lee SR, Paik KS, Kim MK. Anatomical study of the pyramidal process of the palatine bone in relation to implant placement in the posterior maxilla. *J Oral Rehabil.* 2001 Feb;28(2):125-32. Pubmed PMID: 11298260.
- [10]. Chin YB, Leno MB, Dumrongwongsiri S, Chung KH, Lin HH, Lo LJ. The pterygomaxillary junction: An imaging study for surgical information of LeFort I osteotomy. *Sci Rep.* 2017 Aug 30;7(1):9953. Pubmed PMID: 28855714.
- [11]. Curi MM, Cardoso CL, Ribeiro Kde C. Retrospective study of pterygoid implants in the atrophic posterior maxilla: implant and prosthesis survival rates up to 3 years. *Int J Oral Maxillofac Implants.* 2015 Mar-Apr;30(2):378-83. Pubmed PMID: 25830398.
- [12]. Rodríguez X, Lucas-Taulé E, Elnayef B, Altuna P, Gargallo-Albiol J, Peñarrocha Diago M, et al. Anatomical and radiological approach to pterygoid implants: a cross-sectional study of 202 cone beam computed tomography examinations. *Int J Oral Maxillofac Surg.* 2016 May;45(5):636-40. Pubmed PMID: 26768019.
- [13]. Balshi TJ, Wolfinger GJ, Balshi SF. Analysis of 356 pterygomaxillary implants in edentulous arches for fixed prosthesis anchorage. *Int J Oral Maxillofac Implants.* 1999 Jun;14(3):398-406.
- [14]. Valerón JE, Valerón PE. Long-term results in placement of screw-type implants in the pterygomaxillary-pyramidal region. *Int J Oral Maxillofac Implants.* 2007 Mar-Apr;22(2):195-200. Pubmed PMID: 17465343.
- [15]. Bidra AS, Huynh-Ba G. Implants in the pterygoid region: a systematic review of the literature. *Int J Oral Maxillofac Surg.* 2011 Aug;40(8):773-81. Pubmed PMID: 21601424.
- [16]. Khongkhunthian P, Jomjunyong K, Reichart PA. Accuracy of cone beam computed tomography for dental implant treatment planning. *CMU J Nat Sci.* 2017 Jan 1;16(1):51-62.
- [17]. Alamri HM, Sadrameli M, Alshalhooob MA, Alshehri MA. Applications of CBCT in dental practice: a review of the literature. *General dentistry.* 2012 Sep 1;60(5):390-400.