

Knowledge and Awareness about Resin Infiltration: A Micro-Invasive Treatment for White Spot Lesions

Research Article

Minal Tulsani^{1*}, Subhabrata Maiti², Divya Rupawat³

¹ Postgraduate Student, Department of Prosthodontics, Saveetha Dental College and Hospitals, Saveetha Institute of Medical and Technical Sciences Saveetha University, Chennai-600077, Tamilnadu, India.

² Senior Lecturer, Department of Prosthodontics, Saveetha Dental College And Hospitals, Saveetha Institute Of Medical And Technical Sciences, Saveetha University, Chennai-600077, Tamilnadu, India.

³ Postgraduate Student, Department of Prosthodontics, Saveetha Dental College and Hospitals, Saveetha Institute of Medical and Technical Sciences Saveetha University, Chennai-600077, Tamilnadu, India.

Abstract

Objective: Resin infiltration is a micro-invasive technique which aids in preserving sound enamel and has cariostatic properties which makes it a radical treatment option of white spot lesions. This survey was done to evaluate the awareness about resin infiltration: a micro-invasive treatment for white spot lesions. This survey intended to know the knowledge of the dentist about the protocol and applications of resin infiltration, as it is a technique sensitive procedure which aids in arresting the non-carious enamel lesions, reverting back the structure to normal and helps in procuring better esthetic results.

Materials and Methods: A cross-sectional survey was formulated for the dentist of India. 234 volunteers participated in this study between January to February of 2020. A validated questionnaire consisting of 10 close ended questions which helped to know the level of participants' knowledge about resin infiltration: a micro-invasive treatment for white spot lesions was circulated using online social media. The questions were graded using 'bipolar scaling method' or 'even scale method'. The responses were collected using web protocol forms that enabled quick and secure access to data. Chi-square test was done.

Results: The knowledge about resin infiltration: a micro-invasive treatment for white spot lesions is very less, mainly in individuals pursuing only bachelors in dental surgery and an increase in the awareness should be considered mainly during the dental school education and even during continuing dental education as it might help dental surgeons who are not aware of this conservative procedure.

Conclusion: Awareness about resin infiltration: a micro-invasive treatment available for treating white spot lesions like hypomineralization, fluorosis, initial cavitation, white spots caused due to debonding of orthodontic brackets is very less.

Keywords: Acid Etching; Resin Infiltration; Secondary Caries; Viscosity; White Spot Lesions.

Introduction

Dentists frequently have to treat various colour aberrations of teeth like extrinsic or intrinsic staining or white spot lesions (WSL's). WSL's can occur due to demineralisation of enamel, initial proximal caries and labial white spots occur frequently due to fixed orthodontic treatment, fluorosis, hypo-plastic enamel, etc. WSL's have prevalence of 50% [1], 60% [2] or even 97% [3] after debonding once the orthodontic treatment has been done, affect-

ing mainly the labial surfaces of maxillary incisors. WSL's have an outer intact surface layer, which is covering an underneath more porous body of lesion. An active WSL has a chalky white, opaque appearance, this is seen due to light scattering within the body of the lesion. Scattering of light mainly occurs at the interfaces, due to difference in the refractive indices (RI) of enamel (1.62–1.65), water (1.33) and air (1.00). Thus, visual detection of early WSL needs drying of the lesion, as the RI of water is closer to that of enamel so the WSL might appear as normal enamel to naked eyes

*Corresponding Author:

Minal Tulsani,
Postgraduate Student, Department of Prosthodontics, Saveetha Dental College And Hospitals, Saveetha Institute Of Medical And Technical Sciences, Saveetha University, Chennai-600077, Tamilnadu, India.
Tel: +919921181287
E-mail: minaltulsani23@gmail.com

Received: November 12, 2020

Accepted: November 27, 2020

Published: December 03, 2020

Citation: Minal Tulsani, Subhabrata Maiti, Divya Rupawat. Knowledge and Awareness about Resin Infiltration: A Micro-Invasive Treatment for White Spot Lesions. *Int J Dentistry Oral Sci.* 2020;55:02:009:46-53. doi: <http://dx.doi.org/10.19070/2377-8075-SI02-05009>

Copyright: Minal Tulsani ©2020. This is an open-access article distributed under the terms of the Creative Commons Attribution License, which permits unrestricted use, distribution and reproduction in any medium, provided the original author and source are credited.

[3-6]. Except for air content, light scattering in WSL was shown to be dependent on mineral content of enamel as well [7].

There are various treatment options available for WSL's which include fluoride application which will help in enhancing remineralisation or casein phosphopeptide amorphous calcium phosphate [8], low viscosity composite resins, micro-abrasion, polyurethane foils [9], different sealants and resin infiltration. These all are considered as micro-invasive treatments as they are more conservative than standard restorative treatments, these were introduced as alternative treatment options for the management WSL's, which extend up to the outer part of dentin.

Remineralisation using fluoride is the most commonly used method. But it has the following disadvantages: no cosmetic improvement [10, 11], in deeper lesions the surface layer gets mineralised and the subsurface layer remains un-mineralized [12, 13], results are not predictable, long time of treatment, patient compliance [7, 14] is necessary, etc. Micro-abrasion is usually effective for small WSL's [15], but it removes more amount of mineralized enamel and it is technically demanding, hence all cannot have successful outcome with micro-abrasion [9, 15, 16]. Restorative techniques that use veneers, laminates or crowns have been extensively used and have shown to have excellent esthetic results [17, 18] but these procedures lead to loss of a lot of dental hard tissue mainly enamel. Due to the reversible nature of WSL's, less invasive treatment options should be considered. These micro-invasive treatments help to preserve dental hard tissues structures like enamel and therefore retreatment associated with the restorative dentistry can be avoided [7].

Charite Berlin developed the concept of resin infiltration as a micro-invasive approach for the management of smooth surface WSL's and interproximal non-cariou lesions [7]. This concept aims at creating a porous surface which helps in infiltrating the body of the lesion with low viscosity resin and helps in creating a diffusion barrier within the tooth. It helps to block the diffusion pathways for acids and dissolved minerals causing caries, this helps to stop the demineralization process before it reaches cavitation [7, 19]. It is produced by DMG America Company, Englewood, NJ, product name is Icon. It is available in two forms, one is a proximal surface kit and another is vestibular surface kits. Low viscosity resin infiltrants were developed so that they had better penetration and infiltration of resin within the porous body of the lesion [20, 21], when compared to the regular composite resin [22, 23]. This is achieved by capillary action technique, which helps to carry low viscosity resins into the porous body of lesion, as they have high penetration coefficients, low contact angle and high surface tension [24]. Acid used to etch enamel is 15% HCl and not 37% phosphoric acid, as pseudo-intact surface layer of enamel is removed with help of HCl more easily than phosphoric acid [25]. Resin infiltration is a promising micro-invasive technique that could help preserve the remaining dental hard tissue and reduce the treatment cost [26].

There are many *in-vitro* studies and reviews on resin infiltration: a micro-invasive treatment for white spot lesions, but there are very few surveys conducted to know the knowledge of the dentist on resin infiltration as a treatment option. Hence, this study aims to evaluate the awareness about resin infiltration: a micro-invasive treatment for white spot lesion.

Material and Method

A cross-sectional questionnaire survey was conducted among the dentists in India between January to February of 2020. A structured online questionnaire comprising 10 closed-ended questions regarding the participant's demographic details (age, gender and profession) and knowledge about resin infiltration: a micro-invasive treatment for white spot lesions. The majority of questions were graded using 'Even scale method' to avoid central tendency bias and social desirability bias. Validation was done among post-graduate students and staff of the Department of Prosthodontics in xxx Dental College, India. Changes in the questions regarding technique of resin infiltration was done according to the suggestion of the validation committee.

Survey sample size calculator was used for calculating the sample size, confidence interval was kept as 95% and 5% margin error, with an estimated 20% dropout, which was up to 384 samples. A questionnaire was sent to 480 dentist participants selected using online social media snowball sampling method. Out of 480, 234 participants voluntarily participated in the survey (response rate - 48.75 %). The responses were collected using web protocol forms that enabled quick and secure access to data. Ethical clearance was obtained from SRB xxx Dental College, India. Guidelines were followed as per the Helsinki declaration.

All the collected data was then tabulated and analysed and using-SPSS Statistics software for windows, version 20.0. Descriptive data was obtained. Chi square test was done for frequency analysis and Pearson's correlation coefficient was done for comparison of awareness between males and females, different age groups and between professions.

Results

A total of 234 participants were questioned out of which 30.8% were male and 69.2% were females. The age range of the study individuals were from 21 to 50 years with 50% of individuals in the age range of 25-30 yrs. All the results have been summarised in Table 1, 2 and 3 (Figure 1-6).

Discussion

Fluorosis, hypo-mineralization due to trauma, amelogenesis imperfecta, and molar-incisor hypo mineralization are the most commonly observed white spot lesions caused in enamel before tooth eruption. Opaque enamel lesions caused after tooth eruption are initial carious lesions and post-orthodontic lesions. These conditions are together called as white spot lesions (WSL) and are of esthetic concern mainly when affecting children and young adults [27]. The frequency of WSLs ranges between 8.3 and 51.6% [28]. Incidence of post-orthodontic WSLs has been reported as 96% [29]. The prevalence of MIH is different in various age groups, ranging from 2.8% to 40% 30. The prevalence of fluorosis in children and adults ranges between 4% and 70% [30, 31]. Amelogenesis imperfecta prevalence is up to 0.14% [32].

G.V. Black in 1908 defined WSLs as "occasional white or grey spots that are small and are covered with the glazed surface of normal enamel, so that an exploring tip glides over white spots the same way as it glides over normal enamel" [32]. Silverstone

Table 1. All the questions of the survey, options for the responses, the percentage of responses by males and females, cumulative percentage of responses, chi square value and P value have been tabulated.

Question	Options	Response by Females (%)	Response by Males (%)	Cumulative response (%)	Chi square value	P Value
If there is a white spot lesion, what treatment would you prefer?	Fluoride application	18.5	29.2	21.8	6.562	0.255
	Composite restoration	20.4	16.7	19.2		
	Resin infiltration	25.9	29.2	26.9		
	Veneers	16.7	12.5	15.4		
	Crowns	3.7	0	2.6		
	Micro-abrasion	14.8	12.5	14.1		
Do you know the procedure of resin infiltration?	Yes	44.4	37.5	42.3	0.985	0.321
	No	55.6	62.5	57.7		
Which acid should be used for etching non-cariou lesions for resin infiltration?	37% Phosphoric acid	46.3	58.3	50	3.114	0.374
	15% Hydrochloric acid	24.1	20.8	23.1		
	10% Hydrofluoric acid	24.1	16.7	21.8		
	Others	5.6	4.2	5.1		
For how long will you etch?	1 min	16.7	4.2	12.8	21.888	0.000*
	30 sec	55.6	37.5	50		
	2 min	7.4	16.7	10.3		
	20 sec	20.4	41.7	26.9		
What should be the viscosity of the resin used for infiltration?	High	18.5	33.3	23.1	8.08	0.018*
	Medium	46.3	45.8	46.2		
	Low	35.2	20.8	30.8		
According to you, will resin infiltration help in reducing secondary carious lesions?	Yes	83.3	79.2	82.1	0.588	0.443
	No	16.7	20.8	17.9		
In which case, you would prefer resin infiltration?	Fluorosis	35.8	27.8	33.3	1.985	0.575
	Attrition	11.7	16.7	13.2		
	Initial carious lesion	21.6	22.2	21.8		
	Hypo-mineralization	30.9	33.3	31.6		

*The chi square statistic is significant at the 0.05 level.

confirmed the work done by Applebaum in 1932, using polarized microscopy and microradiography, which showed an intact outer layer as the outer surface of these lesions always remained unaltered [20, 33]. A porous demineralized enamel layer was found under this intact outer layer which was called 'body of lesion' by Silverstone [20, 33]. The body of the lesion contains 25%-50% porous enamel structures and 40-45 μm thick outer layer contains 82%-84% of mineral content [25, 31], the outer layer is then covered with an "acquired cuticle" [34] that can vary from one specimen to another in ultrastructure and mineralization [35].

WSLs white and opaque lesion commonly seen on the labial surface of anterior teeth and as incipient class II lesions in the interproximal region in posterior teeth [35]. Refractive index of hydroxyapatite in sound enamel is 1.62 [20, 36]. When a WSL is covered with saliva, the RI of saliva and the hydroxyapatite of enamel lesion together is 1.33. WSL looks slightly opaque as the light scattering is affected due to the difference in RI of saliva and hydroxyapatite. In dry conditions, saliva is replaced with air which has a refractive index of 1.0. The difference between the refrac-

tive index of air and hydroxyapatite is more than the difference between refractive index of saliva and hydroxyapatite, due to this difference in refractive index the WSL is more prominent when the teeth are dried [20, 35, 36].

The treatment options for the WSLs are micro-abrasion, external bleaching, resin infiltration, composite resin restoration, veneers and crowns and bridges [27]. Treatment options selected for younger individuals should be the least invasive, as the expected life span of the tooth is more. Micro-abrasion and resin infiltration techniques, are the techniques which have least effect on enamel and help in preserving the tooth structure, hence, are considered as the most conservative treatment options available in recent years [28]. Resin infiltration technique has shown better esthetic results when compared to fluoride application or amorphous calcium phosphate treatment for white spot lesions [35, 37].

In 1976, a cariostatic treatment was introduced, according to which enamel has to be etched with HCl followed by the infiltra-

Table 2. All the questions of the survey, options for the responses, the percentage of responses according to age range, cumulative percentage of responses, chi square value and P value have been tabulated.

Question	Options	20-25 year (%)	25-30 year (%)	30-35 year (%)	35-40 year (%)	40-45 year (%)	Cumulative response (%)	Chi square value	P Value
If there is a white spot lesion, what treatment would you prefer?	Fluoride application	20.5	29	0	0	0	21.8	48.9	0.000*
	Composite restoration	17.9	16.1	50	0	0	19.2		
	Resin infiltration	23.1	22.6	50	100	100	26.9		
	Veneers	17.9	16.1	0	0	0	15.4		
	Crowns	5.1	0	0	0	0	2.6		
	Micro-abrasion	15.4	16.1	0	0	0	14.1		
Do you know the procedure of resin infiltration?	Yes	43.6	32.3	66.7	100	100	42.3	16.484	0.002*
	No	56.4	67.7	33.3	0	0	57.7		
Which acid should be used for etching non-cariou lesions for resin infiltration?	37% Phosphoric acid	43.6	58.1	50	0	100	50	53.66	0.000*
	15% Hydrochloric acid	28.2	9.7	50	100	0	23.1		
	10% Hydrofluoric acid	28.2	19.4	0	0	0	21.8		
	Others	0	12.9	0	0	0	5.1		
For how long will you etch?	1 min	15.4	12.9	0	0	0	12.8	56.42	0.000*
	30 sec	53.8	51.6	33.3	0	0	50		
	2 min	2.6	12.9	33.3	100	0	10.3		
	20 sec	28.2	22.6	33.3	0	100	26.9		
What should be the viscosity of the resin used for infiltration?	High	25.6	22.6	16.7	0	0	23.1	18.72	0.016*
	Medium	41	54.8	50	0	0	46.2		
	Low	33.3	22.6	33.3	100	100	30.8		
According to you, will resin infiltration help in reducing secondary carious lesions?	Yes	82.1	83.9	66.7	100	100	82.1	4.414	0.353
	No	17.9	16.1	33.3	0	0	17.9		
In which case, you would prefer resin infiltration?	Fluorosis	27.7	46.2	16.7	0	0	33.3	33.01	0.001*
	Attrition	17.1	7.5	22.2	0	0	13.2		
	Initial carious lesion	18.8	22.6	27.8	100	0	21.8		
	Hypo-mineralization	36.8	23.7	33.3	0	100	31.6		

*The chi square statistic is significant at the 0.05 level.

Table 3. All the questions of the survey, options for the responses, the percentage of responses according to profession, cumulative percentage of responses, chi square value and P value have been tabulated.

Question	Options	Under-graduate (%)	Dental Practitioner (%)	PG Prosthodontic (%)	PG other than Prosthodontic (%)	Prosthodontists (%)	Cumulative response (%)	Chi square value	P Value
If there is a white spot lesion, what treatment would you prefer?	Fluoride application	50	22.2	15	25	0	21.8	97.72	0.000*
	Composite restoration	0	22.2	20	17.9	0	19.2		
	Resin infiltration	0	18.5	35	28.6	100	26.9		
	Veneers	0	22.2	25	3.6	0	15.4		
	Crowns	50	0	0	3.6	0	2.6		
	Micro-abrasion	0	14.8	5	21.4	0	14.1		
Do you know the procedure of resin infiltration?	Yes	0	29.6	45	53.6	100	42.3	18.36	0.001*
	No	100	70.4	55	46.4	0	57.7		
Which acid should be used for etching non-cariou lesions for resin infiltration?	37% Phosphoric acid	100	66.7	25	50	0	50	57.28	0.000*
	15% Hydrochloric acid	0	11.1	45	17.9	100	23.1		
	10% Hydrofluoric acid	0	18.5	30	21.4	0	21.8		
	Others	0	3.7	0	10.7	0	5.1		
For how long will you etch?	1 min	0	7.4	25	10.7	0	12.8	76.57	0.000*
	30 sec	0	63	60	35.7	0	50		
	2 min	0	11.1	0	14.3	100	10.3		
	20 sec	100	18.5	15	39.3	0	26.9		
What should be the viscosity of the resin used for infiltration?	High	0	14.8	40	21.4	0	23.1	30.3	0.000*
	Medium	50	51.9	25	57.1	0	46.2		
	Low	50	33.3	35	21.4	100	30.8		
According to you, will resin infiltration help in reducing secondary carious lesions?	Yes	50	77.8	95	78.6	100	82.1	13.36	0.010*
	No	50	22.2	5	21.4	0	17.9		
In which case, you would prefer resin infiltration?	Fluorosis	66.7	38.3	26.7	32.1	0	33.3	30.55	0.002*
	Attrition	16.7	16	10	13.1	0	13.2		
	Initial carious lesion	16.7	21	11.7	27.4	100	21.8		
	Hypo-mineralization	0	24.7	51.7	27.4	0	31.6		

*The chi square statistic is significant at the 0.05 level.

Figure 1. Bar graph showing association between profession of participant's and response to the question "If there is a white spot lesion, what treatment would you prefer?" X-axis represents profession of participants and Y-axis represents percentage of responses. According to percentage of responses 100% prosthodontists choose resin infiltration (Grey) as treatment for white spot lesions. Chi-square value: 97.72, P value: 0.000 (>0.05).

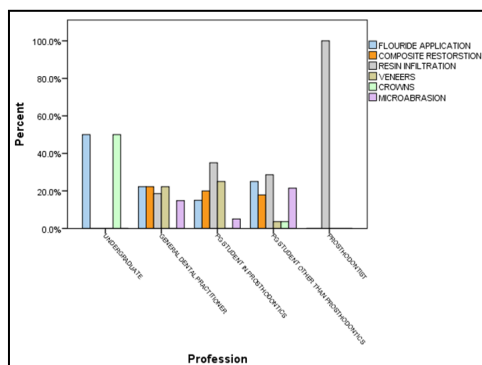


Figure 2. Bar graph showing association between profession of participant's and response to the question "Do you know the procedure of resin infiltration?" X-axis represents profession of participants and Y-axis represents percentage of responses. According to percentage of responses 100% undergraduates responded No (Grey) and 100% prosthodontists responded Yes (Blue). Chi-square value: 18.36, P value: 0.001 (>0.05).

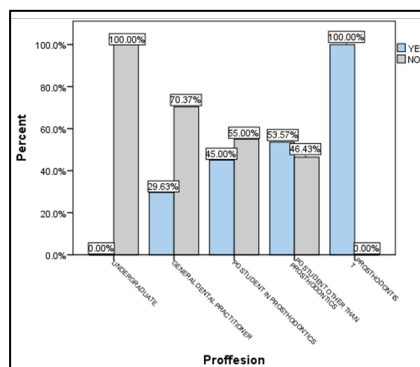
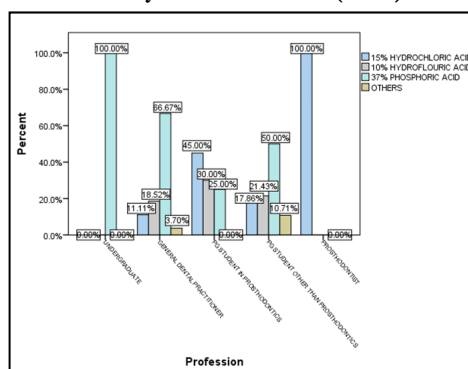


Figure 3. Bar graph showing association between profession of participant's and response to the question "Which acid should be used for etching non-carious lesions for resin infiltration?" X-axis represents profession of participants and Y-axis represents percentage of responses. According to percentage of responses 100% undergraduates choose 37% phosphoric acid (Green) and 100% prosthodontists choose 15% hydrochloric acid (Blue). Chi-square value: 57.28, P value: 0.000 (>0.05).



tion with a low-viscosity resin by capillary action [35, 38]. Enamel build-up and cariostatic properties can be achieved by infiltrating WSLs with 15% HCl etching which makes the surface layer porous, this porous layer is then dried using ethanol which removes the excess water, followed by application of a low-viscosity light-cured resin (tetra-ethylene glycol di-methacrylate [TEGDMA]), this technique has shown to prevent light scattering inside the WSL and hence helps to mask the lesion. As low viscosity resin exhibits low contact angles to the enamel and high surface tension due to their very low viscosity. This properties of low viscosity resin helps in penetration of the resin into the body of the lesion which helps in preventing micro leakage. In addition, resin filled

porosities reinforces the unsupported enamel, which makes the inner enamel structure stronger and resistant to acid dissolution. According to our study 57.7% didn't know about the procedure of resin infiltration and only 30.8% knew that low viscosity resin is used in this. One of the study, revealed that resin infiltration results in more penetration and less micro-leakage than conventional resin when applied on non-carious white spot lesions seen in pits and fissure of permanent teeth. The mean resin penetration value in teeth treated with resin infiltration was $104.8571 \pm 7.63360 \mu\text{m}$ which was significantly higher than that in teeth treated with conventional procedure which was $5.3158 \pm 3.83825 \mu\text{m}$. The mean micro-leakage value in enamel treated with convention-

Figure 4. Bar graph showing association between profession of participant’s and response to the question “For how long will you etch?” X-axis represents profession of participants and Y-axis represents percentage of responses. According to percentage of responses 100% undergraduates choose 20 seconds (Cream) and 100% prosthodontists choose 2 minutes (Green). Chi-square value: 76.57, P value: 0.000 (>0.05).

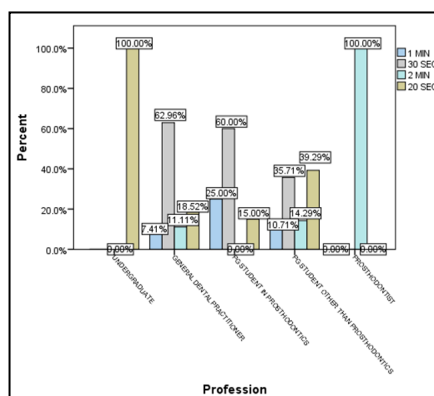


Figure 5. Bar graph showing association between profession of participant’s and response to the question “What should be the viscosity of the resin used for infiltration?” X-axis represents profession of participants and Y-axis represents percentage of responses. According to percentage of responses 100% prosthodontists choose low viscosity resin (Blue), while percentage of responses varied according to different educational level. Chi-square value: 30.30, P value: 0.000 (>0.05).

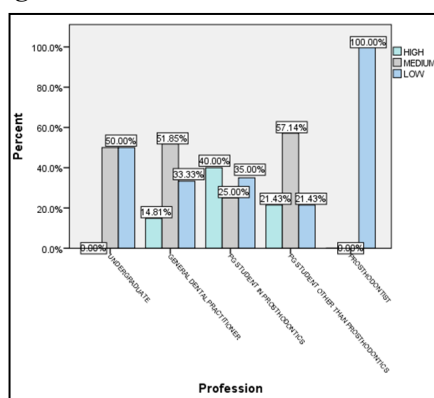
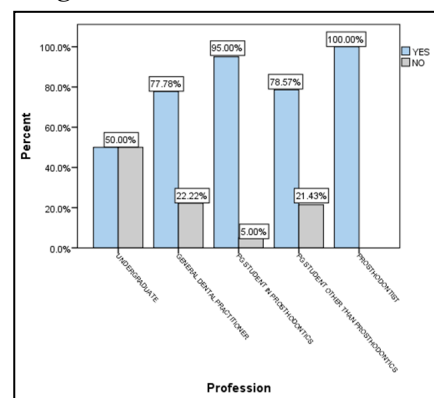


Figure 6. Bar graph showing association between profession of participant’s and response to the question “According to you, will resin infiltration help in reducing secondary carious lesions?” X-axis represents profession of participants and Y-axis represents percentage of responses. According to percentage of responses 100% prosthodontists responded yes (Blue), while percentage of responses varied according to different educational level. Chi-square value: 13.36, P value: 0.01 (>0.05).



al resin was 0.2238 ± 0.12561 which was significantly greater than that in enamel treated with resin infiltration (0.0119 ± 0.0097). Some other studies have reported that resin infiltration could be used to prevent microleakage near the margins of restorations [39, 40] or used as a replacement for the materials used to restore a superficial enamel lesion [41, 42].

The WSL-mineralized outer layer has scarce porosities which hampers resin penetration. Adequate porosities for resin infiltration are not achieved when etching is done using a conventional

phosphoric acid gel, with 15% HCl wider surface porosities can be achieved and it effectively removes the partially mineralized layer [43]. This fact is not known by all, as in this study 50% choose etching with phosphoric acid and only 23.1% choose hydrochloric acid for etching during resin infiltration technique. According to the Icon (DMG America Company, Englewood, NJ) instructions 15% HCl should be used for etching the WSL for 2 minutes. In our study only 10.3% knew that enamel has to be etched for 2 minutes for resin infiltration. However, if the whitish-opaque appearance still persists after applying Icon-Dry (DMG Ameri-

ca Company, Englewood, NJ), the manufacturer recommended etching for one or two times more with each etching cycle of 2 minutes till the opaque appearance is lost. It has been reported that the surface layer of 29% WLSs is thicker than 50 μm , hence the extra etching steps are recommended 25, 35. It has been said that the esthetic outcome can be increased by increasing the numbers of etching cycles or by increasing the duration of etching, as it will lead to better infiltration of the resin [44, 45].

In-vitro and clinical studies have confirmed that resin infiltration is not only an effective esthetic treatment but also a micro-invasive cariostatic procedure [46-50]. Clinical studies revealed that there can be 65–90 % reduction of caries after three years of follow-up in favour of the infiltration technique when compared with other non-invasive techniques [50-57]. Though resin infiltration has shown good results, as a procedure it has some limitations. The success of infiltration depends on the moisture control and depth of the lesion. Depth of lesion affects moisture content of the lesion, resin penetration and polymerization shrinkage. Moisture content can be reduced by following proper protocol of ethanol application, which helps in evaporating the water contents in the deep porosities. Survey done by Holcomb MJ et al., showed similar results like our study, only 9% of respondents knew about the procedure of resin infiltration. According to our study, knowledge of resin infiltration was more in participants of 35-40 years of age, this might be due to various courses conducted, continued dental education, etc. And when compared between different levels of profession, prosthodontists had complete knowledge about resin infiltration followed by post-graduates students in prosthodontics.

Hence, the knowledge about resin infiltration: a micro-invasive treatment for white spot lesions is very less mostly in individuals pursuing only bachelors in dental surgery and an increase in the awareness should be considered mainly during the dental school education and even during continuing dental education as it might help dental surgeons who are not aware of this conservative procedure.

Conclusion

Awareness about resin infiltration: a micro-invasive treatment available for treating white spot lesions like hypo-mineralization, fluorosis, initial cavitation, white spots caused due to debonding of orthodontic brackets is very less. Very few dentists know about the protocol followed for resin infiltration technique and in what cases it can be used. Though resin infiltration is non-invasive technique with better esthetic result and has good mechanical outcomes, its knowledge and practice is less. Hence, increase in the awareness about resin infiltration as a treatment option and its protocol should be considered mainly during the Dental school education and even during continuing dental education.

References

- [1]. Gorelick L, Geiger AM, Gwinnett AJ. Incidence of white spot formation after bonding and banding. *Am J Orthod.* 1982 Feb;81(2):93–8. Pubmed PMID: 6758594.
- [2]. Hadler-Olsen S, Sandvik K, El-Agroudi MA, Øgaard B. The incidence of caries and white spot lesions in orthodontically treated adolescents with a comprehensive caries prophylactic regimen—a prospective study. *Eur J Orthod.* 2012 Oct;34(5):633–9. Pubmed PMID: 21750245.
- [3]. Boersma JG, van der Veen MH, Lagerweij MD, Bokhout B, Prahl-Andersen

- B. Caries prevalence measured with QLF after treatment with fixed orthodontic appliances: influencing factors. *Caries Res.* 2005 Jan-Feb;39(1):41–7. Pubmed PMID: 15591733.
- [4]. Kidd EA, Fejerskov O. What constitutes dental caries? Histopathology of carious enamel and dentin related to the action of cariogenic biofilms. *J Dent Res.* 2004;83 Spec No C:C35–8. Pubmed . PMID: 15286119.
- [5]. Brodbelt RHW, O'Brien WJ, Fan PL, Frazer-Dib JG, Yu R. Translucency of Human Dental Enamel [Internet]. *Journal of Dental Research.* 1981; 60: 1749–53.
- [6]. Houwing B. The index of refraction of dental enamel apatite. *British dental journal.* 1974 Dec;137(12):472–5.
- [7]. Paris S, Schwendicke F, Keltsch J, Dörfer C, Meyer-Lueckel H. Masking of white spot lesions by resin infiltration in vitro. *J Dent.* 2013 Nov;41 Suppl 5:e28–34. Pubmed PMID: 23583919.
- [8]. Beerens MW, Van Der Veen MH, Van Beek H, Ten Cate JM. Effects of casein phosphopeptide amorphous calcium fluoride phosphate paste on white spot lesions and dental plaque after orthodontic treatment: a 3-month follow-up [Internet]. *Eur J Oral Sci.* 2010 Dec;118(6):610–7. Pubmed PMID: 21083623.
- [9]. Meireles SS, Andre Dde A, Leida FL, Bocangel JS, Demarco FF. Surface roughness and enamel loss with two microabrasion techniques. *J Contemp Dent Pract.* 2009 Jan 1;10(1):58–65. Pubmed PMID: 19142257.
- [10]. Bailey DL, Adams GG, Tsao CE, Hyslop A, Escobar K, Manton DJ, et al. Regression of post-orthodontic lesions by a remineralizing cream. *J Dent Res.* 2009 Dec;88(12):1148–53. Pubmed PMID: 19887683.<https://pubmed.ncbi.nlm.nih.gov/19887683/>
- [11]. Willmot DR. White lesions after orthodontic treatment: does low fluoride make a difference?. *Journal of orthodontics.* 2004 Sep 1;31(3):235–42.
- [12]. Cate JMT, ten Cate JM, Arends J. Remineralization of Artificial Enamel Lesions in vitro [Internet]. *Caries Research.* 1978;12: 213–22.
- [13]. Naumova EA, Niemann N, Aretz L, Arnold WH. Effects of different amine fluoride concentrations on enamel remineralization. *J Dent.* 2012 Sep;40(9):750–5. Pubmed PMID: 22677913.
- [14]. van der Veen MH, Mattousch T, Boersma JG. Longitudinal development of caries lesions after orthodontic treatment evaluated by quantitative light-induced fluorescence. *Am J Orthod Dentofacial Orthop.* 2007 Feb;131(2):223–8. Pubmed PMID: 17276863.
- [15]. Wong FSL, Winter GB. Effectiveness of microabrasion technique for improvement of dental aesthetics. *Br Dent J.* 2002 Aug 10;193(3):155–8. Pubmed PMID: 12213009.
- [16]. Dalzell DP, Howes RI, Hubler PM. Microabrasion: effect of time, number of applications, and pressure on enamel loss. *Pediatr Dent.* 1995 May;17(3):207–11. Pubmed PMID: 7617497.
- [17]. Sadowsky SJ. An overview of treatment considerations for esthetic restorations: a review of the literature. *J Prosthet Dent.* 2006 Dec;96(6):433–42. Pubmed PMID: 17174661.
- [18]. Dietschi D. Optimizing smile composition and esthetics with resin composites and other conserved esthetic procedures. *Eur J Esthet Dent.* 2008 Spring;3(1):14–29. Pubmed PMID: 19655556.
- [19]. Paris S, Meyer-Lueckel H, Coelfen H, Kielbassa AM. Resin infiltration of artificial enamel caries lesions with experimental light curing resins. *Dental materials journal.* 2007;26(4):582–8.
- [20]. Kielbassa AM, Muller J, Gernhardt CR. Closing the gap between oral hygiene and minimally invasive dentistry: a review on the resin infiltration technique of incipient (proximal) enamel lesions. *Quintessence Int.* 2009 Sep;40(8):663–81.
- [21]. Meyer-Lueckel H, Chatzidakis A, Naumann M, Dörfer CE, Paris S. Influence of application time on penetration of an infiltrant into natural enamel caries. *J Dent.* 2011 Jul;39(7):465–9. Pubmed PMID: 21549801.
- [22]. Meyer-Lueckel H, Paris S. Progression of artificial enamel caries lesions after infiltration with experimental light curing resins. *Caries Res.* 2008 Feb 28;42(2):117–24. Pubmed PMID: 18305389.
- [23]. Meyer-Lueckel H, Paris S. Improved resin infiltration of natural caries lesions. *J Dent Res.* 2008 Dec;87(12):1112–6. Pubmed PMID: 19029077.
- [24]. Meyer-Lueckel H, Paris S, Mueller J, Coelfen H, Kielbassa AM. Influence of the application time on the penetration of different dental adhesives and a fissure sealant into artificial subsurface lesions in bovine enamel. *Dent Mater.* 2006 Jan;22(1):22–8. Pubmed PMID: 16040112.
- [25]. Meyer-Lueckel H, Paris S, Kielbassa AM. Surface layer erosion of natural caries lesions with phosphoric and hydrochloric acid gels in preparation for resin infiltration. *Caries Res.* 2007;41(3):223–30. Pubmed PMID: 17426404.
- [26]. Chatzimakrou S, Koletsi D, Kavvadia K. The effect of resin infiltration on proximal caries lesions in primary and permanent teeth. A systematic review and meta-analysis of clinical trials. *J Dent.* 2018 Oct;77:8–17. Pubmed PMID: 30092238.
- [27]. da Cunha Coelho ASE, Mata PCM, Lino CA, Macho VMP, Areias CM-

- FGP, Norton APMAP, et al. Dental hypomineralization treatment: A systematic review. *J EsthetRestor Dent*. 2019 Jan;31(1):26–39. Pubmed PMID: 30284749.
- [28]. Gençer MDG, Kirzioğlu Z. A comparison of the effectiveness of resin infiltration and microabrasion treatments applied to developmental enamel defects in color masking. *Dent Mater J*. 2019 Mar 31;38(2):295-302. Pubmed PMID: 30713284.
- [29]. Kim S, KIM EY, JEONG TS, KIM JW. The evaluation of resin infiltration for masking labial enamel white spot lesions. *International journal of paediatric dentistry*. 2011 Jul;21(4):241-8.
- [30]. Gelani R, Zandona AF, Lippert F, Kamočka MM, Eckert G. In vitro progression of artificial white spot lesions sealed with an infiltrant resin. *Oper Dent*. 2014 Sep-Oct;39(5):481-8. Pubmed PMID: 25153897.
- [31]. Arends J, Christoffersen J. The nature of early caries lesions in enamel. *J Dent Res*. 1986 Jan;65(1):2–11. Pubmed PMID: 3510230. <https://pubmed.ncbi.nlm.nih.gov/3510230/>
- [32]. Black GV. The pathology of the hard tissues of the teeth. 1920.
- [33]. Silverstone LM. Observations on the dark zone in early enamel caries and artificial caries-like lesions. *Caries Res*. 1967;1(3):260-74. Pubmed PMID: 5238295.
- [34]. Palamara J, Phakey PP, Rachinger WA, Orams HJ. Ultrastructure of the intact surface zone of white spot and brown spot carious lesions in human enamel. *J Oral Pathol*. 1986 Jan;15(1):28-35. Pubmed PMID: 3080565.
- [35]. Perdigão J. Resin infiltration of enamel white spot lesions: An ultramorphological analysis. *J EsthetRestor Dent*. 2020 Apr;32(3):317–24. Pubmed PMID: 31742888.
- [36]. Denis M, Atlan A, Vennat E, Tirlot G, Attal JP. White defects on enamel: diagnosis and anatomopathology: two essential factors for proper treatment (part 1). *Int Orthod*. 2013 Jun;11(2):139-65. English, French. Pubmed PMID: 23597715.
- [37]. Yuan H, Li J, Chen L, Cheng L, Cannon RD, Mei L. Esthetic comparison of white-spot lesion treatment modalities using spectrometry and fluorescence. *Angle Orthod*. 2014 Mar;84(2):343-9. Pubmed PMID: 23984991.
- [38]. Robinson C, Hallsworth AS, Weatherell JA, Künzel W. Arrest and control of carious lesions: a study based on preliminary experiments with resorcinol-formaldehyde resin. *J Dent Res*. 1976 Sep-Oct;55(5):812-8. Pubmed PMID: 823185.
- [39]. Tulunoglu O, Tulunoglu IF, Antonson SA, Campillo-Funollet M, Antonson D, Munoz-Viveros C. Effectiveness of an infiltrant on sealing of composite restoration margins with/without artificial caries. *J Contemp Dent Pract*. 2014 Nov 1;15(6):717-25. Pubmed PMID: 25825096.
- [40]. Espigares J, Hayashi J, Shimada Y, Tagami J, Sadr A. Enamel margins resealing by low-viscosity resin infiltration. *Dent Mater J*. 2018 Mar 30;37(2):350–7. Pubmed PMID: 29515053.
- [41]. Kielbassa AM, Ulrich I, Schmidl R, Schüller C, Frank W, Werth VD. Resin infiltration of deproteinised natural occlusal subsurface lesions improves initial quality of fissure sealing. *International journal of oral science*. 2017 Jun;9(2):117-24.
- [42]. Al Tuwiriq AA, Alshammari AM, Felemban OM, Ali Farsi NM. Comparison of Penetration Depth and Microleakage of Resin Infiltrant and Conventional Sealant in Pits and Fissures of Permanent Teeth. *J Contemp Dent Pract*. 2019 Nov 1;20(11):1339–44.
- [43]. Meng Z, Yao XS, Yao H, Liang Y, Liu T, Li Y, Wang G, et al. Measurement of the refractive index of human teeth by optical coherence tomography. *J Biomed Opt*. 2009 May-Jun;14(3):034010. Pubmed PMID: 19566303.
- [44]. Paris S, Meyer-Lueckel H. Resin infiltration after enamel etching. In *Tooth Whitening 2016*; 211-222. Springer, Cham.
- [45]. Kobbe C, Fritz U, Wierichs RJ, Meyer-Lueckel H. Evaluation of the value of re-wetting prior to resin infiltration of post-orthodontic caries lesions. *J Dent*. 2019 Dec;91:103243. Pubmed PMID: 31730787.
- [46]. Landis JR, Koch GG. The measurement of observer agreement for categorical data. *Biometrics*. 1977 Mar;33(1):159-74. Pubmed PMID: 843571.
- [47]. Meyer-Lueckel H, Balbach A, Schikowsky C, Bitter K, Paris S. Pragmatic RCT on the Efficacy of Proximal Caries Infiltration. *J Dent Res*. 2016 May;95(5):531–6. Pubmed PMID: 26826108.
- [48]. Ammari MM, Jorge RC, Souza IPR, Soviero VM. Efficacy of resin infiltration of proximal caries in primary molars: 1-year follow-up of a split-mouth randomized controlled clinical trial. *Clin Oral Investig*. 2018 Apr;22(3):1355–62. Pubmed PMID: 28990122.
- [49]. Ekstrand KR, Bakhshandeh A, Martignon S. Treatment of proximal superficial caries lesions on primary molar teeth with resin infiltration and fluoride varnish versus fluoride varnish only: efficacy after 1 year. *Caries Res*. 2010;44(1):41-6. Pubmed PMID: 20090327.
- [50]. Paris S, Bitter K, Krois J, Meyer-Lueckel H. Seven-year-efficacy of proximal caries infiltration - Randomized clinical trial. *J Dent*. 2020 Feb;93:103277. Pubmed PMID: 31931026.
- [51]. Arslan S, Kaplan MH. The Effect of Resin Infiltration on the Progression of Proximal Caries Lesions: A Randomized Clinical Trial. *Med Princ Pract*. 2020;29(3):238-243. Pubmed PMID: 31476757.
- [52]. Peters MC, Hopkins AR Jr, Zhu L, Yu Q. Efficacy of Proximal Resin Infiltration on Caries Inhibition: Results from a 3-Year Randomized Controlled Clinical Trial. *J Dent Res*. 2019 Dec;98(13):1497-1502. Pubmed PMID: 31526071.
- [53]. Peters MC, Hopkins AR Jr, Yu Q. Resin infiltration: An effective adjunct strategy for managing high caries risk-A within-person randomized controlled clinical trial. *J Dent*. 2018 Dec;79:24-30. Pubmed PMID: 30227152.
- [54]. Arthur RA, Zenkner JE, d'Ornellas Pereira Júnior JC, Correia RT, Alves LS, Maltz M. Proximal carious lesions infiltration-a 3-year follow-up study of a randomized controlled clinical trial. *Clin Oral Investig*. 2018 Jan;22(1):469-474. Pubmed PMID: 28560502.
- [55]. Martignon S, Tellez M, Santamaria RM, Gomez J, Ekstrand KR. Sealing distal proximal caries lesions in first primary molars: efficacy after 2.5 years. *Caries Res*. 2010;44(6):562-70. Pubmed PMID: 21088401.
- [56]. Meyer-Lueckel H, Paris S, Ekstrand K. *Caries Management - Science and Clinical Practice*. Thieme; 2013. 436 p.
- [57]. Paris S, Hopfenmuller W, Meyer-Lueckel H. Resin infiltration of caries lesions: an efficacy randomized trial. *J Dent Res*. 2010 Aug;89(8):823-6. Pubmed PMID: 20505049.