

Incidence Of Miniplate Removal Following Its Fixation In Maxillofacial Surgery - A Retrospective Study

Research Article

Subhashini R¹, Abdul Wahab P U^{2*}, Santhosh Kumar M P³¹ Saveetha Dental College And Hospitals, Saveetha Institute Of Medical And Technical Sciences, Saveetha University, Chennai, 600050, India.² Professor, Saveetha Dental College and Hospitals, Saveetha Institute Of Medical And Technical Sciences, Saveetha University, Chennai, India.³ Reader, Saveetha Dental College and Hospitals, Saveetha Institute Of Medical And Technical Sciences, Saveetha University, Chennai, India.

Abstract

The aim of the study was to investigate the incidence and reasons for miniplate removal following maxillofacial surgery. The study was also aimed to identify risk factors predisposing miniplate removal and to assess if discomfort was reduced after plate removal. It was a retrospective study and data was collected from the hospital digital data registry with a total sample of 22 patients who were operated for plate removal from July 2019 - March 2020. Data from all the case sheets were retrieved and statistically analysed using SPSS version 23.0 and results obtained. A p value of <0.05 was considered as statistically significant. Males were most commonly affected (p=0.01); Plate removal after Trauma is more likely than after orthognathic surgery and cancer surgery (p=0.01); Stainless steel plates were infected more than titanium plates (p=0.01). All the results were statistically significant. Smoking plays a major role in infection (71.6%); 90% of the miniplates were removed due to infection. Smoking, Infection, type of plates influence the plate removal and almost all patients were relieved from discomfort due to the infected plate after hardware removal.

Keywords: Risk Factors; Miniplates; Hardware; Fixation; Oral and Maxillofacial Surgery.

Introduction

Every year nearly five thousand patients with Cranio-facial trauma are treated by open reduction and internal fixation [9, 4, 14, 11, 29, 16, 1]. Open reduction and internal fixation can be complicated by miniplate exposure, screw loosening or infection [31, 8]. Infection is usually associated with redness, inflammation and fever, which is Painful and pus may drain from the specified area [30].

Plate removal is a controversial topic in oral and maxillofacial surgery. Usually plate removal is done after completion of bone healing. Titanium plates have good tissue compatibility and it is considered to be non-carcinogenic, corrosion resistant and non toxic [13, 27]. Smoking has a strong association with hardware removal [5, 10]. In addition to rate of removal it is important to investigate the reason for the plate removal and the risk factors associated with it. Therefore the aim of this study was to investigate the incidence and reasons of removal of mini plates and to identify its risk factors.

This study states the clinical indications for removal of miniplates following their placement in trauma and orthognathic patients. It is of some importance to consider that the removal of plates is not necessarily synonymous with a failure of treatment. Union of segments may have occurred prior to removal, or may occur subsequent to removal. Miniplates may be removed for various reasons such as wound dehiscence, pain, interference with dentures and palpability. This retrospective study looks at the reasons for their removal and the possible causes for this, i.e. the determining factors of sex and age and the more specific ones of site from which the plate was removed, time lapse between injury and fixation and the time between plate insertion and its removal and the type of plate.

Materials and Methods

This was a retrospective study done in the department of oral and maxillofacial surgery, saveetha dental college, saveetha university from the records of patients available in the digital data registry. Data of patients who underwent surgeries including

*Corresponding Author:

Abdul Wahab P U,
Professor, Saveetha Dental College and Hospitals, Saveetha Institute Of Medical And Technical Sciences, Saveetha University, Chennai, India.
E-mail: abdulwahab@saveetha.com

Received: July 27, 2020

Accepted: August 22, 2020

Published: August 30, 2020

Citation: Subhashini R, Abdul Wahab PU, Santhosh Kumar MP. Incidence Of Miniplate Removal Following Its Fixation In Maxillofacial Surgery - A Retrospective Study *Int J Dentistry Oral Sci.* 2020;S5:02:0026:144-146. doi: <http://dx.doi.org/10.19070/2377-8075-SI02-050026>

Copyright: Abdul Wahab PU©2020. This is an open-access article distributed under the terms of the Creative Commons Attribution License, which permits unrestricted use, distribution and reproduction in any medium, provided the original author and source are credited.

trauma, orthognathic surgery and cancer surgery and were later operated for plate removal from July 2019 - March 2020 were retrieved from hospital records. Got Ethical clearance from the college ethical committee and the ethical clearance number is SDC/SIHEC/2020/DIASDATA/0619-0320. A total sample of 22 patients were retrieved for the study. It included 17 trauma patients (68%), orthognathic surgery patients (13%), and cancer surgery patients (9%). Types of miniplates used in these surgical procedures were Titanium plates (81%) and Stainless steel plates (19%). Data collected were statistically analysed using SPSS version 23 and results obtained. Categorical variables were expressed in frequency and percentage; and tests of association between categorical variables were done with chi square test. A p value of <0.05 was considered as statistically significant.

Result And Discussion

In our study among 22 patients, 18 were males and 4 females. 6 patients were non smokers (29%) and others had smoking habits (71%) (Figure 1). Infection rate and type of plate used had strong association and the results were statistically significant ($p < 0.05$) (Figure 2). Plate removal following trauma surgery is more likely (77%) than orthognathic surgery and cancer surgery and the results were statistically significant; Males were mostly affected (81%) ($p < 0.05$) (Figure 3). 90% of the plates were infected and two patients wanted to remove plates for screening purposes. Out of infected plates, 80% of the plates were stainless steel and plate

removal was done for those cases.

Plate removal after maxillofacial surgeries vary significantly. Studies reported [7, 21] a high rate of plate removal, but only 7% of the plates were infected. It was assumed that the reason was an active policy of plate removal.

In extreme cases where the miniplates are exposed or infected, the management depends on the duration of exposure, the amount of discomfort, screw loosening, and whether the bone is healed or stable [6, 24]. A prolonged exposure leads to contamination and infection secondary to exposure. Some authors [23, 18] reported a success rate of 83% when debridement of soft tissue was performed within 3 weeks. Infected hardware may loosen as well and it is one of the absolute indications for plate removal.

In case of orthognathic surgery, the stability of miniplate after BSSO [12, 25], and incidence of titanium plate removal have been discussed [17, 3, 28].

Smoking is a powerful risk factor for plate removal and it has been confirmed in previous studies [17, 3, 19]. In our study also there is a strong association between these two variables in accordance with other studies [27].

Bioresorbable plates might be a better solution for this problem. But the previous studies [20, 1] reported 9 % complication rates for bio resorbable plates. It was concluded that these plates cause

Figure 1. Pie Chart represents the Percentage of Smokers Vs Non Smokers and Infection rate in relation to miniplate fixation is more in smokers(Blue) (71%) than Non Smokers(Orange)(29%).

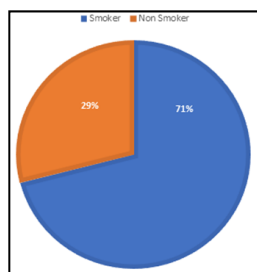


Figure 2. Bar Graph showing the association between type of plates and the infection rate where Red denotes due to infection and Green denotes patients wish for screening purpose. X-Axis represents type of plates and Y-Axis represents Infection Rate. Infection Rate is more with Stainless steel plates(80%) than titanium plates. Chi Square test done $p = 0.03$ ($p < 0.05$) and it is statistically significant.

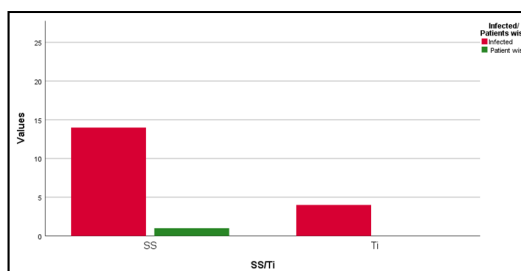
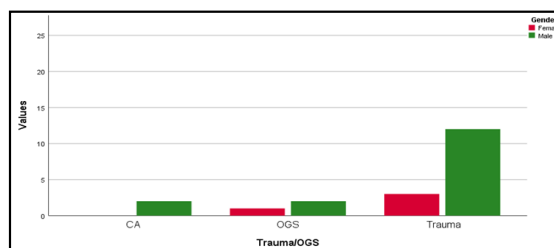


Figure 3. Bar Graph shows the association between type of maxillofacial surgeries and the rate of plate removal where Green denotes Males and Red denotes Females. X Axis represents type of surgery, Y-Axis represents infection rate. Male patients were infected more after trauma(70%) than Females (30%). Chi Square Test with $p = 0.03$ ($p < 0.05$) and it is statistically significant.



similar kinds of problems as metallic plates.

It is assumed that extensive jaw movements increase stress on miniplates. In our study we could not evaluate the relation between amount of movement and plate removal, whereas several other studies have explained them [3, 26]. Many studies have described that healing is affected by increasing age, whereas in our study we could not find any association between age and plate removal.

Role of infection is a major reason for plate removal [17, 3, 15]. In our study also 90.5% of the plates were infected and caused discomfort to the patients. The treatment of plate related infections in this study was retrospectively based on medical records and we did not do bacterial sampling.

Studies have shown that titanium plates are corrosion resistant, non carcinogenic and it won't cause progressive surface deterioration. Similarly in our study we found that 80 % of the infected plates were stainless steel plates and titanium plates had better success rates.

Conclusion

From our study it can be concluded that the reason for plate removal in most patients was related to discomfort and plate related complication. Smoking habits, gender, type of plates used have direct influence on the success of miniplate fixation. Most of the patients were relieved from discomfort after hardware removal.

References

- Abhinav RP, Selvarasu K, Maheswari GU, Taltia AA. The Patterns and Etiology of Maxillofacial Trauma in South India. *Ann Maxillofac Surg*. 2019 Jan-Jun;9(1):114-117. PubmedPMID: 31293938.
- Sweta VR, Abhinav RP, Ramesh A. Role of Virtual Reality in Pain Perception of Patients Following the Administration of Local Anesthesia. *Ann Maxillofac Surg*. 2019 Jan-Jun;9(1):110-113. PubmedPMID: 31293937.
- Alpha C, O'Ryan F, Silva A, Poor D. The incidence of postoperative wound healing problems following sagittal ramus osteotomies stabilized with miniplates and monocortical screws. *J Oral Maxillofac Surg*. 2006 Apr;64(4):659-68. PubmedPMID: 16546646.
- Andreasen JO, Storgård Jensen S, Kofod T, Schwartz O, Hillerup S. Open or closed repositioning of mandibular fractures: is there a difference in healing outcome? A systematic review. *Dent Traumatol*. 2008 Feb;24(1):17-21. PubmedPMID: 18173659.
- Bhatt V, Chhabra P, Dover MS. Does smoking affect the survival of miniplates in the oral and maxillofacial region? *J Oral Maxillofac Surg*. 2006 Sep;64(9):1462-3. PubmedPMID: 16916696.
- Bishop JA, Palanca AA, Bellino MJ, Lowenberg DW. Assessment of compromised fracture healing. *J Am Acad Orthop Surg*. 2012 May;20(5):273-82. PubmedPMID: 22553099.
- Borstlap WA, Stoelting PJ, Hoppenreijts TJ, van't Hof MA. Stabilisation of sagittal split advancement osteotomies with miniplates: a prospective, multi-centre study with two-year follow-up. Part I. Clinical parameters. *Int J Oral Maxillofac Surg*. 2004 Jul;33(5):433-41. PubmedPMID: 15183405.
- Brasileiro BF, Passeri LA. Epidemiological analysis of maxillofacial fractures in Brazil: a 5-year prospective study. *Oral Surg Oral Med Oral Pathol Oral Radiol Endod*. 2006 Jul;102(1):28-34. PubmedPMID: 16831669.
- Champy M, Loddé JP, Schmitt R, Jaeger JH, Muster D. Mandibular osteosynthesis by miniature screwed plates via a buccal approach. *J Maxillofac Surg*. 1978 Feb;6(1):14-21. PubmedPMID: 274501.
- Christabel A, Anantanarayanan P, Subash P, Soh CL, Ramanathan M, Muthusekhar MR, et al. Comparison of pterygomaxillary dysjunction with tuberosity separation in isolated Le Fort I osteotomies: a prospective, multi-centre, triple-blind, randomized controlled trial. *Int J Oral Maxillofac Surg*. 2016 Feb;45(2):180-5. PubmedPMID: 26338075.
- Danda AK. Comparison of a single noncompression miniplate versus 2 noncompression miniplates in the treatment of mandibular angle fractures: a prospective, randomized clinical trial. *J Oral Maxillofac Surg*. 2010 Jul;68(7):1565-7. PubmedPMID: 20430504.
- Frost D. Skeletal stability and relapse patterns after LeFort 1 osteotomy using miniplate fixation in patients with isolated cleft palate: J. C Posnick, M. Taylor. *Plast Reconstr Surg* 1994; 94: 51-60. *British Journal of Oral and Maxillofacial Surgery*. 1995 Dec 1;33(6):393.
- Haug RH. Retention of asymptomatic bone plates used for orthognathic surgery and facial fractures. *J Oral Maxillofac Surg*. 1996 May;54(5):611-7. PubmedPMID: 8632246.
- Hermund NU, Hillerup S, Kofod T, Schwartz O, Andreasen JO. Effect of early or delayed treatment upon healing of mandibular fractures: a systematic literature review. *Dent Traumatol*. 2008 Feb;24(1):22-6. PubmedPMID: 18173660.
- Vijayakumar Jain S, Muthusekhar MR, Baig MF, Senthilnathan P, Loganathan S, Abdul Wahab PU, et al. Evaluation of Three-Dimensional Changes in Pharyngeal Airway Following Isolated Lefort One Osteotomy for the Correction of Vertical Maxillary Excess: A Prospective Study. *J Maxillofac Oral Surg*. 2019 Mar;18(1):139-146. PubmedPMID: 30728705.
- Jesudasan JS, Wahab PU, Sekhar MR. Effectiveness of 0.2% chlorhexidine gel and a eugenol-based paste on postoperative alveolar osteitis in patients having third molars extracted: a randomised controlled clinical trial. *Br J Oral Maxillofac Surg*. 2015 Nov;53(9):826-30. PubmedPMID: 26188932.
- Kuhlefelt M, Laine P, Suominen-Taipale L, Ingman T, Lindqvist C, Thorén H. Risk factors contributing to symptomatic miniplate removal: a retrospective study of 153 bilateral sagittal split osteotomy patients. *Int J Oral Maxillofac Surg*. 2010 May;39(5):430-5. PubmedPMID: 20181459.
- Kumar S. Relationship between dental anxiety and pain experience during dental extractions. *Asian Journal of Pharmaceutical and Clinical Research*. 2017;10(3):458-.
- Kumar S. The emerging role of botulinum toxin in the treatment of orofacial disorders: Literature update. *Asian Journal of Pharmaceutical and Clinical Research*. 2017;10(9):21-9.
- Laine P, Kontio R, Lindqvist C, Suuronen R. Are there any complications with bioabsorbable fixation devices? A 10 year review in orthognathic surgery. *Int J Oral Maxillofac Surg*. 2004 Apr;33(3):240-4. PubmedPMID: 15287306.
- Marimuthu M, Andiappan M, Wahab A, Muthusekhar MR, Balakrishnan A, Shanmugam S. Canonical Wnt pathway gene expression and their clinical correlation in oral squamous cell carcinoma. *Indian J Dent Res*. 2018 May-Jun;29(3):291-297. PubmedPMID: 29900911.
- Kumar S, Rahman RE. Knowledge, awareness, and practices regarding biomedical waste management among undergraduate dental students. *Asian Journal of Pharmaceutical and Clinical Research*. 2017;10(8):341.
- Nahabedian MY, Orlando JC, Delanois RE, Mont MA, Hungerford DS. Salvage procedures for complex soft tissue defects of the knee. *Clin Orthop Relat Res*. 1998 Nov;(356):119-24. PubmedPMID: 9917675.
- Packiri S, Gurunathan D, Selvarasu K. Management of Paediatric Oral Rarula: A Systematic Review. *J Clin Diagn Res*. 2017 Sep;11(9):ZE06-ZE09. PubmedPMID: 29207849.
- Patil SB, Durairaj D, Suresh Kumar G, Karthikeyan D, Pradeep D. Comparison of Extended Nasolabial Flap Versus Buccal Fat Pad Graft in the Surgical Management of Oral Submucous Fibrosis: A Prospective Pilot Study. *J Maxillofac Oral Surg*. 2017 Sep;16(3):312-321. PubmedPMID: 28717289.
- Patturaja K, Pradeep D. Awareness of Basic Dental Procedure among General Population. *Research Journal of Pharmacy and Technology*. 2016 Sep 1;9(9):1349.
- Rahman RE, Mp SK. Knowledge, attitude, and awareness of dental undergraduate students regarding human immunodeficiency virus/acquired immunodeficiency syndrome patients. *Asian J Pharm Clin Res [Internet]*. 2017;10(5):175-80.
- Rao TD, Kumar MS. Analgesic efficacy of paracetamol vs ketorolac after dental extractions. *Research Journal of Pharmacy and Technology*. 2018 Aug 1;11(8):3375-9.
- Regev E, Shiff JS, Kiss A, Fialkov JA. Internal fixation of mandibular angle fractures: a meta-analysis. *Plast Reconstr Surg*. 2010 Jun;125(6):1753-1760. PubmedPMID: 20517101.
- Santhosh Kumar MP, Sneha S. Knowledge and awareness regarding antibiotics prophylaxis form for infective endocarditis among undergraduate dental students. *Asian J Pharm Clin Res*. 2016;9(2):154-9.
- Schortinghuis J, Bos RR, Vissink A. Complications of internal fixation of maxillofacial fractures with microplates. *J Oral Maxillofac Surg*. 1999 Feb;57(2):130-4; discussion 135. PubmedPMID: 9973119.