

Knowledge, Awareness and Practice on Application of Presurgical Nasoalveolar Moulding for Cleft Lip and Palate Patients

Research Article

Tulsani Minal Gopal¹, Vinay Siva Swamy², Divya Rupawat³

¹ Postgraduate Student, Department of Prosthodontics, Saveetha Dental College and Hospitals, Saveetha Institute of Medical and Technical Sciences Saveetha University, Chennai-600077, Tamilnadu, India.

² Senior Lecturer, Department of Prosthodontics, Saveetha Dental College And Hospitals, Saveetha Institute Of Medical And Technical Sciences, Saveetha University, Chennai-600077, Tamilnadu, India.

³ Postgraduate Student, Department of Prosthodontics, Saveetha Dental College and Hospitals, Saveetha Institute of Medical and Technical Sciences Saveetha University, Chennai-600077, Tamilnadu, India.

Abstract

Introduction: Nasoalveolar moulding is a medically prescribed appliance with the objective of molding the maxillae at the oronasal cavity, thus enhancing suckling and swallowing by approximating lip with the right and left maxillary segments of infants with cleft palates in their proper orientation until surgery is performed to repair the cleft. This procedure helps in reducing the number of surgeries required by the cleft lip and palate baby and enhances the results of the surgery.

Aim: To evaluate knowledge and awareness on application of presurgical nasoalveolar moulding for cleft lip and palate patients among dentists in India.

Material and Methods: A cross-sectional study using a questionnaire format was formulated for the dentists in India. 266 volunteers participated in this study between March to April 2020. A validated questionnaire consisting of 15 close-ended questions intended to solicit the level of participants' knowledge concerning the use of presurgical nasoalveolar moulding in cleft lip and palate patients was circulated using online media sharing platforms. The responses were collected using web protocol forms that enabled quick and secure access to data. Chi square test and Pearson's correlation was to determine awareness between males and females and between professions.

Results: This study showed that dentists had a general awareness about the term presurgical nasoalveolar moulding. But only 21.1% of participants knew about the rationale of presurgical nasoalveolar moulding. Similarly, knowledge about force vectors delivered by presurgical nasoalveolar moulding was minimal (13.2%). There was a statistically significant difference seen between responses given by males and females and even between responses given by professionals in different fields of dentistry.

Conclusion: Awareness about the application of pre surgical nasoalveolar moulding for cleft lip and palate patients is minimal as determined by the results of this survey. Increased awareness of this technique could improve the aesthetic outcome of newborns with cleft lip and palate as well as reduce the number of surgeries required to correct their deformity. Hence, Presurgical Nasoalveolar Moulding for Cleft repair should be included as part of the dental education curriculum across all dental schools.

Keywords: Cleft Lip; Cleft Palate; Moulding Plate; Nasoalveolar Moulding

Introduction

Cleft lip and palate is a common congenital anomaly [1]. It results from a multifactorial inheritance process which is also impacted by environmental factors [2]. These Clefts may vary from minor

notching of lip or bifid uvula to cleft palate alone to complete unilateral or bilateral cleft of the lip and palate. The prevalence of orofacial cleft has been reported as 0.34 per 1000 in Africans, 1.22 per 1000 in Indians, 1.34 per 1000 in whites and 2.13 per 1000 in Japanese [3, 4].

*Corresponding Author:

Minal Tulsani,
Postgraduate Student, Department of Prosthodontics, Saveetha Dental College And Hospitals, Saveetha Institute Of Medical And Technical Sciences, Saveetha University, Chennai-600077, Tamilnadu, India.
Tel: +919921181287
E-mail: minaltulsani23@gmail.com

Received: November 12, 2020

Accepted: November 27, 2020

Published: December 03, 2020

Citation: Tulsani Minal Gopal, Vinay Siva Swamy, Divya Rupawat. Knowledge, Awareness and Practice on Application of Presurgical Nasoalveolar Moulding for Cleft Lip and Palate Patients. *Int J Dentistry Oral Sci.* 2020;S5:02:0010:54-61. doi: <http://dx.doi.org/10.19070/2377-8075-S102-050010>

Copyright: Minal Tulsani©2020. This is an open-access article distributed under the terms of the Creative Commons Attribution License, which permits unrestricted use, distribution and reproduction in any medium, provided the original author and source are credited.

Since centuries, the treatment of cleft lip and palate include presurgical infant orthopaedics. The early techniques focused on elastic retraction of the premaxilla which is protruded in these patients, followed by stabilization after surgical repair. The use of facial binding and strapping to narrow the cleft and stabilize the premaxilla after surgery will help in preventing post-surgical dehiscence was demonstrated by Hoffmann in 1689 [5]. Similarly in 1790 Desault gave a technique that will help to retract the maxilla before surgical repair in bilateral cleft patients [5]. In 1844, Hüllihen used adhesive tape for presurgical preparation of clefts [6]. Esmarch and Kowalzig stabilised premaxilla after surgical retraction with help of a bonnet and strapping technique [7]. In 1927, Brophy used silver wire to approximate the ends of the cleft alveolus before the surgery, these wires are passed through both the ends of the cleft alveolus and are tightened progressively [8].

In 1950, Mc Neil started the modern school of presurgical orthopaedics for treatment of cleft lip and palate [9]. He actively moulded the alveolar segments into the desired position using plates of desired size and shape. McNeil's technique was further developed by an orthodontist named Burston [10]. In 1975, Georgia and Latham introduced an active pin-retained appliance to retract the premaxilla and simultaneously expand the posterior segments [11]. In 1987, Hotz described an appliance which uses a passive orthopaedic plate to slowly align the cleft segments [8, 12].

Grayson in 1933 described a technique which can be used to mould the alveolus, lip and nose together before the surgery. The original research of moulding the nasal cartilage was performed using silicone tubes by Matsuo [13-15]. The nasoalveolar moulding appliance (NAM) has two parts: intraoral moulding plate and the nasal stent to mould the alveolar ridge and the nasal cartilage respectively [8]. Presurgical orthopaedics aim is to reduce the width of the cleft, correct the position of the nasal tip, the alar bone, the philtrum and to obtain proper alignment of the segments before surgery, normalise the swallowing pattern, avoids positioning of the tongue in the cleft, helps to improve the shape of the arch, allow the surgical reparation with minimum tension and reduces the need for grafting, lengthening the columella and facilitate surgery and minimises the resultant scar, reduced need for secondary alveolar bone grafts, hospitalization time/cost and provide the psychosocial benefit to the family [16-21]. The nasoalveolar moulding technique has better outcome results when compared to other techniques of presurgical orthopaedics, as it significantly improves the outcome of the primary surgical repair in cleft lip and palate patients [8, 22]. But according to Hotz & Gnoinski the primary objective of early orthopaedics was to take advantage of intrinsic developmental potentialities and not to facilitate surgery, as postulated by McNeil [23, 24]. As in infants for several weeks after birth there is a high level of hyaluronic acid found, which is attributed because of maternal oestrogen, which leads to temporary plasticity of nasal cartilage and alveolar ridge [25]. This temporary plasticity is used for presurgical nasoalveolar moulding (PNAM), to provide measurable long term benefits to the patient [21, 26, 27]. The few drawbacks associated with this procedure are airway obstruction from ill-fitting appliance, mega nostril, locked out segment, alar rim expansion, failure to tape lip segments, exposure of primary tooth bud, soft tissue irritation and fungal infection [21].

There are various *in vitro* studies and review articles on presurgical nasoalveolar moulding, but there are very few surveys con-

ducted to know the knowledge of the dentist about the same. Hence, this study aims to evaluate knowledge and awareness on application of presurgical nasoalveolar moulding for cleft lip and palate patients among dentists in India.

Materials and Methods

A cross-sectional questionnaire survey was conducted among the dentists in India between March to April 2020.

A structured online questionnaire comprising 15 closed-ended questions regarding the participant's demographic details (age, gender and profession) and knowledge on the nuances of presurgical nasoalveolar moulding was formulated for dissemination. Validation was done among postgraduate students and staff of the Department of Prosthodontics in xxx Dental College, Chennai, India. Changes in the questions regarding various techniques used for presurgical nasoalveolar moulding, different types of plates used, was done according to the suggestion of the validation committee.

Sample size calculation was done using a survey sample size calculator with a 95% confidence interval and 5% margin of error, with an estimated 20% dropout, which was up to 384 samples. A questionnaire was sent to 480 dentist participants selected using online social media snowball sampling method. Out of 480, 266 participants voluntarily participated in the survey (response rate - 55.41 %). The responses were collected using web protocol forms that enabled quick and secure access to data.

Ethical clearance was obtained from the SRB committee in xxx Dental College, Chennai, India. Guidelines on data collection and consent were followed as per the Helsinki declaration.

The collected data was then compiled and analysed using SPSS Statistics software for Windows, version 20.0. Descriptive statistics was obtained followed by Chi square test and Pearson's correlation for comparison across various questions.

Results

A total of 266 participants responded out of which 42.1% were male and 57.9% were females. The age range of the study individuals were from 25 to 50 years with 50% of individuals in the age range of 25-30 yrs. 44.7% responses were from Prosthodontists, 7.9% by oral surgeons, 15.8% by pedodontists and 31.6% by others. Variation in the responses between the participants of different fields was observed (Table 1).

Chi-square test was performed to compare responses to questions two and three, which showed that though 65.8% of the participants said that the PNAM should be started within 1- 6 months of age but when the rationale was asked, only 28% of the participants who knew about the timing responded for increased levels of hyaluronic acid (Table 2, Figure 3).

Chi-square test done between questions eleven and twelve showed that though maximum participants knew about the timing of the nasal stent, none of the corresponding participants knew about the consequence of adding nasal stents at the start of PNAM procedure (Table 3, Figure 4). Chi-square test done between ques-

Table 1. All the questions of the survey, options for the responses, the percentage of responses by different professions, cumulative percentage of responses, chi square value and p value have been tabulated.

Questions	Options	Prosthodontist (%)	Oral surgeon (%)	Pedodontist (%)	Others (%)	Cumulative response (%)	Chi square value	P value
Q1: Should presurgicalnasalveolar moulding be mandatorily performed before cleft lip and palate surgery?	Yes	64.7	0	50	66.7	57.9	47.85	0.000*
	No	0	0	0	0	0		
	Not always	29.4	100	50	33.7	39.5		
	No opinion	5.9	0	0	0	2.6		
Q2: What should be the age of the child when you start the PNAM procedure?	1 month - 6 months	76.5	66.7	66.7	50	65.8	67.88	0.000*
	6 months - 1 year	17.6	0	33.3	50	28.9		
	1 year - 6 years	5.9	33.3	0	0	5.3		
	Above 6 years	0	0	0	0	0		
Q3: What is the rationale behind PNAM?	Growth of palatal plates	41.2	0	16.7	0	21.1	91.3	0.000*
	Growth of premaxilla	35.3	100	50	58.3	50		
	Increased level of hyaluronic acid	23.5	0	16.7	25	21.1		
	Positioning of tongue with help of device	0	0	16.7	16.7	7.9		
Q4: Whose impression technique would you prefer for PNAM?	Grayson	47.1	33.3	83.3	83.3	63.2	114.593	0.000*
	Taylor	47.1	33.3	0	8.3	26.3		
	Routine as for dentates	5.9	0	0	8.3	5.3		
	Others	0	33.3	16.7	0	5.3		
Q5: Which impression material would you prefer for impression in cleft defects?	1 step silicone	52.9	100	66.7	58.3	60.5	52.438	0.000*
	2 step silicone	11.8	0	33.3	25	18.4		
	Impression compound	23.5	0	0	16.7	15.8		
	Tissue conditioner	11.8	0	0	0	5.3		
Q6: Which techniques do you use for PNAM?	Grayson	53.3	33.3	83.3	72.7	62.9	31.83	0.000*
	Figueroa	13.3	33.3	16.7	9.1	14.3		
	Liou	0	0	0	0	0		
	Taylor	33.3	33.3	0	18.2	22.9		
Q7: Which plate do you prefer for PNAM?	Presurgical infant orthopedics plate	7.1	33.3	20	16.7	14.7	47.54	0.000*
	Presurgicalnasalveolar moulding appliance	85.7	33.3	80	66.7	73.5		
	Hotz plate	0	0	0	8.3	2.9		
	Modified nostril retainer	7.1	33.3	0	8.3	8.8		
	Others	0	0	0	0	0		
Q8: Recall for patients undergoing PNAM procedure is done	Every day	5.9	0	0	0	2.6	61.552	0.000*
	Every week	70.6	33.3	66.7	50	60.5		
	Every month	11.8	66.7	16.7	16.7	18.4		
	Every 3 months	11.8	0	16.7	33.3	18.4		
Q9: What should be the amount of resilient resin added at every appointment to the PNAM plate?	0 - 0.5 mm	17.6	0	16.7	16.7	15.8	37.373	0.000*
	0.5 - 1 mm	52.9	33.3	66.7	58.3	55.3		
	1 - 1.5 mm	23.5	33.3	0	8.3	15.8		
	1.5 - 2 mm	0	0	0	0	0		
	According to size of defect	5.9	33.3	16.7	16.7	13.2		
Q10: What should be the direction of the force vector delivered by the PNAM appliance?	Anterior and Inferior	5.9	0	16.7	50	21.1	145.102	0.00*
	Anterior and Superior	82.4	33.3	66.7	16.7	55.3		
	Posterior and Inferior	11.8	33.3	16.7	8.3	13.2		
	Posterior and Superior	0	33.3	0	25	10.5		
Q11: When should the nasal stent be added to a PNAM plate?	When cleft is reduced to :	5.9	0	16.7	8.3	7.9	60.223	0.000*
	8mm	17.6	0	16.7	16.7	15.8		
	7mm	52.9	66	0	25	36.8		
	6mm	23.5	33.3	66.7	50	39.5		
	5mm							
Q12: What are the consequences if the nasal stent is added at the starting of PNAM procedure?	Short nostril	17.6	0	16.7	16.7	15.8	110.034	0.000*
	Wide nostril	41.2	100	83.3	50	55.3		
	Mega nostril	41.2	0	0	8.3	21.1		
	Others	0	0	0	25	7.9		
Q13: According to you, does PNAM help in columellar lengthening?	Yes	58.8	66.7	66.7	33.3	52.6	40.834	0.000*
	No	17.6	33.3	0	16.7	15.8		
	May be	17.6	0	16.7	33.3	21.1		
	No opinion	5.9	0	16.7	16.7	10.5		
Q14: What is the advantage of PNAM?	Helps in bone growth	5.9	33.3	16.7	16.7	10.5	35.505	0.000*
	Helps to reduce size of the defect	64.7	0	33.3	66.7	60.5		
	Reduce overall surgeries	23.5	66.7	33.3	16.7	23.7		
	Easier to swallow	5.9	0	16.7	0	5.3		
Q15: Will PNAM help in improving the quality of life for the child post surgically?	Yes	88.2	66.7	100	91.7	89.5	46.391	0.000*
	No	0	0	0	8.3	2.6		
	May be	11.8	33.3	0	0	7.9		
	No opinion	0	0	0	0	0		

Table 2. Table showing results of Chi-square test done to evaluate association between responses of Question 2 and 3.

Q2: What should be the age of the child when you start the PNAM procedure?	Q3: What is the rationale behind PNAM?				Chi- square Value	P value
	Growth of palatal plates	Growth of premaxilla	Increase in hyaluronic acid	Position of tongue		
1 month - 6 months	24.00%	36.00%	28.00%	12.00%	57.091	0.000*
6 months - 1 year	9.10%	81.80%	9.10%	-		
1 year - 6 years	50.00%	50.00%	-	-		
Total	21.10%	50.00%	21.10%	7.90%		

* The Chi-square statistic is significant at the 0.05 level.

Table 3. Table showing results of Chi-square test done to evaluate association between responses of Question 11 and 12.

Q11: When should the nasal stent be added to a PNAM plate?	Q12: What is the consequence if the nasal stent is added at the starting of PNAM procedure?				Chi- square Value	P Value
	Short nostril	Wide nostril	Mega nostril	Others		
<8mm	33.30%	33.30%	-	33.30%	126.41	0.000*
<7 mm	33.30%	50.00%	16.70%	-		
<6 mm	7.10%	42.90%	50.00%	-		
<5 mm	13.30%	73.30%	-	13.30%		
Total	15.80%	55.30%	21.10%	7.90%		

* The Chi-square statistic is significant at the 0.05 level.

Table 4. Table showing results of Chi-square test done to evaluate association between responses of Question 14 and 15.

Q15: Will PNAM help in improving quality of life for the child post-operatively?	Q14: What is the advantage of PNAM?				Chi- square Value	P Value
	Bone growth	Reduce size of defect	Reduce surgeries	Easy to swallow		
Yes	11.80%	61.80%	20.60%	5.90%	28.371	0.000*
No	-	-	100.00%	-		
Maybe	-	66.70%	33.30%	-		
Total	10.50%	60.50%	23.70%	5.30%		

* The Chi-square statistic is significant at the 0.05 level.

Figure 1. Pre-surgical Infant Orthopaedic Plate with anterior ring (PSIOP) [39].

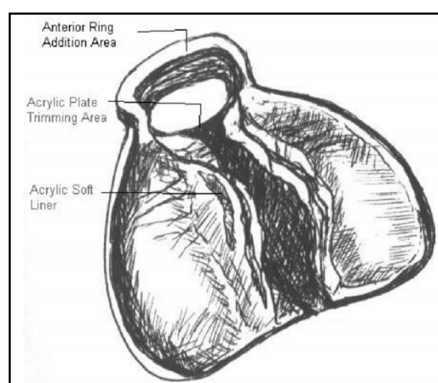


Figure 2. Modified Nostril Retainer [41].

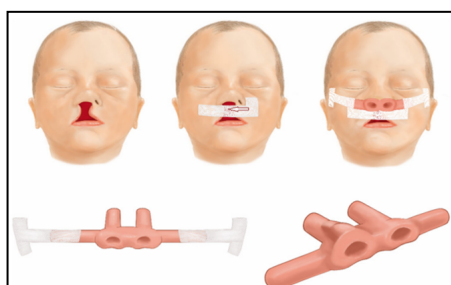


Figure 3. Bar graph showing association between responses of the participants for question 2 and 3.

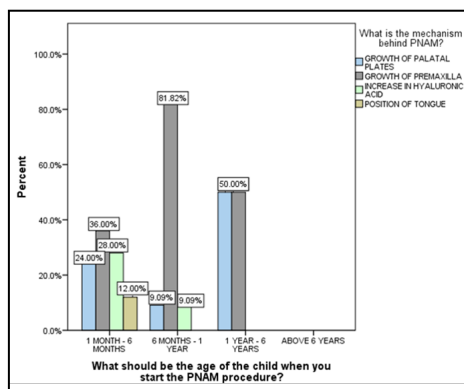


Figure 4. Bar graph showing association between responses of the participants for question 11 and 12.

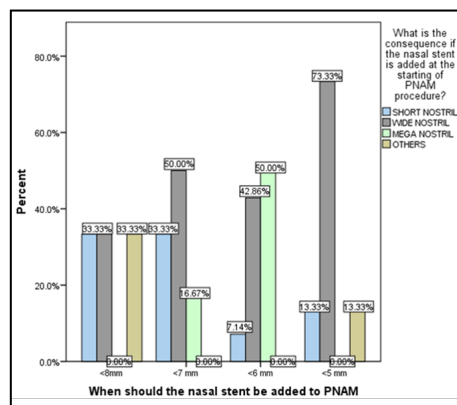
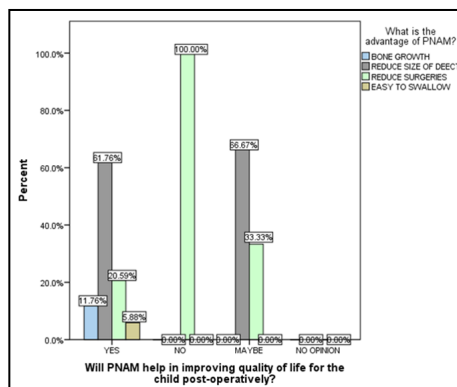


Figure 5. Bar graph showing association between responses of the participants for question 14 and 15.



tions fourteen and fifteen showed that maximum participants responded that PNAM helped in improving the quality of life. Upon inspection of the results, it was observed that 61.8% of the participants responded that the advantage was due to reduced size of the defect and only 20.6% of the corresponding participants responded it was due to reduced number of surgeries. 2.6% participants responded there was no improvement in quality of life but agreed to the fact that PNAM will help in reducing the number of surgeries (Table 4, Figure 5).

Discussion

Cleft lip and palate has always presented difficulty in treatment and hence is considered as one of the most challenging treatments for the craniofacial healthcare team. There are many factors associated with cleft which include functional, psychological, sociological, and aesthetics. Taking all the factors into consideration, a successful treatment will require a team approach which

has a combination of the expertise in healthcare disciplines like a surgical, orthodontic/orthopaedic, restorative care, speech therapy, psychologist and maintenance of the dentition. Treatment plan and timing of treatment for cleft conditions remain a matter of debate even in the current era of advanced technology and development. The basic goal of any treatment of cleft is to repair and restore the defect to normal anatomy. The pre-surgical treatment includes, expansion of the deficient tissues and repositioning of the mal-positioned structures prior to surgical correction. This provides the foundation for a less invasive surgical repair and helps in reducing the number of surgeries required. In our study, 57.9% of the population considered PNAM as a mandatory treatment prior to cleft surgeries. When this was considered according to profession, Oral Surgeons strongly believed that not always PNAM is required before cleft palate surgery.

Timing of the PNAM in repair of the defect is of great significance. There are studies showing that early intervention for moulding has better outcomes, and also reduces the duration of

treatment [14]. A study showed that when PNAM is done within 1 month of age, the outcome is much better than when PNAM is done at 5 months of age [24]. The objective of early orthopaedics is to take advantage of intrinsic developmental potentialities [23, 24]. In infants, several weeks after birth there is a high level of hyaluronic acid circulating in their body, which is attributed because of maternal oestrogen, which leads to temporary increase in plasticity of nasal cartilage and alveolar ridge, which in turn aids in easy moulding of tissues in desired contours [25]. This temporary plasticity is used for pre-surgical nasoalveolar moulding (PNAM), to provide measurable long term benefits to the patient [21, 8, 26-29]. Hence, the timing of the moulding is of utmost importance 65.8% of the participants responding said that the PNAM should be started within 1-6 months of age but when the rationale was asked only 28% of the participants who knew about the timing responded for increased levels of hyaluronic acid.

Impression making for a child of 1-6 months of age is a difficult challenge, but it is one of the important steps at the same point of time. For recording all the details in the impression without obstructing the child's airway is one of the biggest challenges for all dentists. For this proper position of the child, parent/person holding the child and the dentist is of utmost important. Impression is made when a child is awake and is not under any anaesthesia. Various positions for impression making have been suggested in literature like facedown, prone, upright down and upright positions [8, 30-32]. Some authors prefer the impression making in the hospital crib as it provides a work surface which is at a convenient height [33]. Maximum number of participants (63.2%) choose upright down position for impression making, as in this position the infant is inverted, this prevents the tongue from falling back and allows fluids to drain out of the oral cavity instead of infant ingesting the fluids. 83.3% of pedodontist's preferred upright down position while 47.1% of prosthodontists prefer upright down position and 47.1% prosthodontists preferred facedown position.

Impression material used can be alginate, silicone, impression compound. Silicone can be used in one step technique or two step technique. Material used for recording should record all the undercuts properly as they aid in retention of the device. Alginate can be used as it can record all the details even in presence of saliva and is fast setting, only disadvantage of alginate is poor tear strength [34]. Impression compound has better tear strength and if any emergency it can be removed before it sets, but as it is a thermoplastic material it can cause burns or scalds to the child if it is overheated [35]. Silicones are generally preferred as they have high tear strength, low viscosity, good dimensional stability, accurate reproduction of details. One step impression has more chance of slippage of material into the infant throat and disturbance in the undercut area might lead to faulty impression. In one-step technique recording details is more difficult than the two-step impression technique, because the intra-oral and the extra-oral impression parts have to be united and to be impressed at the same time [36]. When impression has to be taken for extra-oral defect along with intraoral defect two-step silicone has shown better results in a study done by Loeffelbein et al [36]. 60.5% of participants preferred a one-step silicone impression. All the oral surgeons preferred one-step impression technique.

According to Grayson's technique of nasoalveolar moulding, nasal stents are added when the cleft size has been reduced to 5mm.

While in Figueroa's technique nasal stent is added from the beginning of treatment to help mold the nasal cartilage and improve nasal symmetry [37]. In Liou's technique the alveolar and nasal molding are performed at the same time and primary cheiloplasty is done after 3 months of moulding [38]. 62.9% of participants preferred Grayson's technique for nasoalveolar moulding. The responses varied according to different procedures. In a study done by Liao et al., [37], showed that Grayson's technique significantly narrowed the nostril width than Figueroa's technique. If nasal molding is done when the alveolar cleft is larger than 5 mm as in the Figueroa technique, it might result in an increase in horizontal dimension of the lateral alar wall which is referred as the "mega nostril" [37]. This fact was known by 21.1% of the participants.

There are various different types of plates available for pre-surgical nasoalveolar moulding. Pre-surgical Infant Orthopaedic Plate (PSIOP) is one of the types, it is made up of soft acrylic and is designed as self-retentive, hence it does not require any extra-oral retention. It has an anterior ring which is the active component of the plate and helps to retract and align the pre-maxillary segments (Figure 1) [4, 39]. Pre-surgical Nasoalveolar Moulding Appliance works according to Grayson's technique, it has an acrylic plate and a nasal stent that is connected in the anterior portion of plate. Nasal stent is made from an orthodontic wire which is molded into swan neck shape and is covered with soft acrylic [30, 40]. According to Grayson's technique nasal stent is added when the cleft size is reduced to 5-6mm, but the modified nostril retainer can be used for nasal moulding before this reduction. The modified nostril retainer is made of soft acrylic, and hence the tension of the soft tissue does not hinder its insertion. Hence, nasal moulding can be started without reducing the width of the alveolar cleft (Figure 2) [41]. Hotz plate is a passive appliance [19]. 73.5% participants choose Pre-surgical Nasoalveolar Moulding Appliance for pre-surgical nasoalveolar moulding. There was a difference in choice of plate for nasoalveolar moulding according to different professions.

The adjustments to the moulding plate to bring the alveolar segments together is done weekly [8, 42]. Some authors preferred adjustments to be done during biweekly visits [43]. The modification is done by 0.5 – 1mm increments per appointment [42]. No more than 1 mm of modification of the moulding plate should be made at one visit [8]. The appliance is selectively grinded in the areas where movement is expected at the same time soft denture liner is added in the region which requires molding. This is similar to the Zurich type of molding device described by Hotz (1969) [42]. 70.6% and 66.7% prosthodontist and pedodontist choose recall at every week respectively. But only 33.3% oral surgeons choose a recall every week interval and alter the PNAM appliance. 55.3% participants responded that 0.5-1mm of resilient resin should be added at every appointment to the PNAM appliance. The direction of the force vector delivered by the PNAM appliance is posteriorly and superiorly [44]. This was known by only 10.5% of the participants.

PNAM has various advantages like reduced number of surgical procedures, quantity of graft required is also reduced, appliances can help infants in suckling, economical, predictable repositioning of alveolar segments, helps to achieve better outcome after surgery, etc. Though PNAM has various advantages it has some disadvantages/drawbacks also. The drawbacks are airway obstruction due to ill-fitting appliance, mega nostril, locked out segment,

ulceration, failure to tape lip segments, loss of retention of the appliance, exposure of primary tooth bud, soft tissue irritation and fungal infection [21]. The coordination between the parents, orthodontist, and plastic surgeon with proper training and clinical skills leads to the desired outcomes of pre-surgical nasoalveolar-moulding which benefit the cleft patients and also to the surgeon performing the surgery for primary repair of cleft lip and palate. Awareness of PNAM amongst health care personnel is extremely low, leading to dissemination of erroneous information regarding timing of surgery. Hence, the knowledge about application of pre-surgical nasoalveolar moulding for cleft lip and palate patients is very less mostly in individuals pursuing only bachelors in dental surgery and an increase in the awareness should be considered mainly during the dental school education and even during continuing dental education as it might help dental surgeons who are not aware of this procedure.

Conclusion

Awareness about application of presurgical nasoalveolar moulding for cleft lip and palate patients is very minimal. Very few dentists know about the protocol and various techniques and the rationale for presurgical nasoalveolar moulding and each of its steps. Though presurgical nasoalveolar moulding is a procedure which results in better esthetic result and decreases the number of surgeries required, it's knowledge and practice is less. Hence, increase in the awareness about application of presurgicalnasalveolar moulding for cleft lip and palate patients and protocol should be considered mainly during the Dental school education and even during continuing dental education.

References

- Calzolari E, Bianchi F, Rubini M, Ritvanen A, Neville AJ. Epidemiology of Cleft Palate in Europe: Implications for Genetic Research. *The Cleft Palate-Craniofacial Journal*. 2004; 41(3): 244–9. Pubmed PMID: 15151454.
- Hopkins EE, Gazza E, Marazita ML. Parental experience caring for cleft lip and palate infants with nasoalveolar moulding. *J AdvNurs*. 2016 Oct; 72(10): 2413–22. Pubmed PMID: 27144651.
- Golalipour MJ, Mirfazeli A, Behnampour N. Birth Prevalence of Oral Clefting in Northern Iran. *The Cleft Palate-Craniofacial Journal*. 2007; 44(4): 378–80. Pubmed PMID: 17608544.
- Ijaz A, Raffat A, Israr J. Nasoalveolar molding of bilateral cleft of the lip and palate infants with orthopaedic ring plate. *J Pak Med Assoc*. 2010 Jul; 60(7): 527–31. Pubmed PMID: 20578599.
- Millard DR. *Cleft Craft: The Evolution of Its Surgery*. II, Bilateral and Rare Deformities. Little, Brown; 1977.
- Goldwyn RM, Simon P, Hullihen: pioneer oral and plastic surgeon. *Plast Reconstr Surg*. 1973 Sep; 52(3): 250–7. Pubmed PMID: 4579165.
- Gibson T. Cleft Craft. The evolution of its surgery. II. Bilateral and rare deformities. *Journal of Plastic, Reconstructive & Aesthetic Surgery*. 1980 Apr 1; 33(2): 307.
- Grayson BH, Shetye PR. Presurgical nasoalveolar moulding treatment in cleft lip and palate patients. *Indian J Plast Surg*. 2009 Oct; 42 Suppl: S56–61. Pubmed PMID: 19884682.
- C. Kerr McNeil. Orthodontic procedures in the treatment of congenital cleft palate. *Dent Rec (London)*. 1950 May; 70(5): 126-32. Pubmed PMID: 24537837.
- Johnston MC. Orthodontic treatment for the cleft palate patient. *American Journal of Orthodontics*. 1958 Oct 1; 44(10): 750-63.
- Georgiade NG, Latham RA. Maxillary arch alignment in the bilateral cleft lip and palate infant, using pinned coaxial screw appliance. *Plast Reconstr Surg*. 1975 Jul; 56(1): 52–60. Pubmed PMID: 1096192.
- Hotz M, Perko M, Gnoinski W. Early Orthopaedic Stabilization Of The Praemaxilla In Complete Bilateral Cleft Lip and Palate In Combination With The Celesnik Lip Repair. *Scandinavian Journal of Plastic and Reconstructive Surgery*. 1987; 21(1): 45–51. Pubmed PMID: 3589579.
- Matsuo K, Hirose T. Nonsurgical correction of cleft lip nasal deformity in the early neonate. *Ann Acad Med Singapore*. 1988 Jul; 17(3): 358–65. Pubmed PMID: 3064700.
- Matsuo K, Hirose T, Otogiri T, Norose N. Repair of cleft lip with nonsurgical correction of nasal deformity in the early neonatal period. *Plast Reconstr Surg*. 1989 Jan; 83(1): 25–31. Pubmed PMID: 2909076.
- Matsuo K, Hirose T. Preoperative non-surgical over-correction of cleft lip nasal deformity. *British Journal of Plastic Surgery*. 1991; 44(1): 5–11. Pubmed PMID: 1993238.
- Mauil DJ, Grayson BH, Cutting CB, Brecht LL, Bookstein FL, Khorrambadi D, et al. Long-Term Effects of Nasoalveolar Molding on Three-Dimensional Nasal Shape in Unilateral Clefts. *The Cleft Palate-Craniofacial Journal*. 1999; 36(5): 391–7. Pubmed PMID: 10499400.
- ópez-Palacio, Cerón-Zapata AM, Gómez DF, Dávila-Calle AP, Ojalvo-Arias MA. Nasal changes with nasoalveolar molding in Colombian patients with unilateral cleft lip and palate. *Pediatr Dent*. 2012 May; 34(3): 239–44. Pubmed PMID: 22795158.
- Ball JV, Di Biase DD, Sommerlad BC. Transverse maxillary arch changes with the use of preoperative orthopedics in unilateral cleft palate infants. *Cleft Palate Craniofac J*. 1995 Nov; 32(6): 483–8. Pubmed PMID: 8547288.
- Cerón-Zapata AM, López-Palacio AM, Rodríguez-Ardila MJ, Berrio-Gutiérrez LM, De Menezes M, Sforza C. 3D evaluation of maxillary arches in unilateral cleft lip and palate patients treated with nasoalveolar moulding vs Hotz's plate. *Journal of Oral Rehabilitation*. 2016; 43(2): 111–8. Pubmed PMID: 26404105.
- Mitsuyoshi I, Masahiko W, Masayuki F. Simple modified preoperative nasoalveolar moulding in infants with unilateral cleft lip and palate. *Br J Oral Maxillofac Surg*. 2004 Dec; 42(6): 578–80. Pubmed PMID: 15544893.
- Chaudhary DC, Sharma R, Sharma V, Kaur S. Presurgical nasoalveolar moulding: A boon in the management of cleft lip and palate. *Medical Journal Armed Forces India*. 2016; 72(Suppl 1): S164–8. Pubmed PMID: 2805103.
- Grayson BH, Cutting CB. Presurgical nasoalveolar orthopaedic molding in primary correction of the nose, lip, and alveolus of infants born with unilateral and bilateral clefts. *Cleft Palate Craniofac J*. 2001 May; 38(3): 193–8. Pubmed PMID: 11386426.
- Hotz M, Gnoinski W. Comprehensive care of cleft lip and palate children at Zürich university: a preliminary report. *Am J Orthod*. 1976 Nov; 70(5): 481–504. Pubmed PMID: 1068633.
- Shetty V, Vyas HJ, Sharma SM, Sailer HF. A comparison of results using nasoalveolar moulding in cleft infants treated within 1 month of life versus those treated after this period: development of a new protocol. *Int J Oral Maxillofac Surg*. 2012 Jan; 41(1): 28–36. Pubmed PMID: 22018821.
- Matsuo K, Hirose T, Tomono T, Iwasawa M, Katohda S, Takahashi N, Koh B. Nonsurgical correction of congenital auricular deformities in the early neonate: a preliminary report. *Plastic and reconstructive surgery*. 1984 Jan 1; 73(1):38-50.
- Cutting C, Grayson B, Brecht L, Santiago P, Wood R, Kwon S. Presurgical Columellar Elongation and Primary Retrograde Nasal Reconstruction in One-Stage Bilateral Cleft Lip and Nose Repair. *Plastic and Reconstructive Surgery*. 1998; 101(3): 630–9. Pubmed PMID: 9500379.
- Santiago PE, Grayson BH, Cutting CB, Gianoutsos MP, Brecht LE, Kwon SM. Reduced Need for Alveolar Bone Grafting by Presurgical Orthopedics and Primary Gingivoperiosteoplasty. *The Cleft Palate-Craniofacial Journal*. 1998; 35(1): 77–80. Pubmed PMID: 9482227.
- Winters JC, Hurwitz DJ. Presurgical orthopedics in the surgical management of unilateral cleft lip and palate. *Plast Reconstr Surg*. 1995 Apr; 95(4): 755–64. Pubmed PMID: 7892327.
- Grayson BH, Garfinkle JS. The Role of Nasoalveolar Molding in the Presurgical Management of Infants Born with Cleft Lip and Palate. In *Cleft Lip and Palate Primary Repair 2013*; 3-33.
- Grayson BH, Santiago PE, Brecht LE, Cutting CB. Presurgical Nasoalveolar Molding in Infants with Cleft Lip and Palate. *The Cleft Palate-Craniofacial Journal*. 1999; 36(6): 486–98. Pubmed PMID: 10574667.
- Yang S, Stelnicki EJ, Lee MN. Use of nasoalveolar molding appliance to direct growth in newborn patient with complete unilateral cleft lip and palate. *Pediatr Dent*. 2003 May; 25(3): 253–6. Pubmed PMID: 12889702.
- Sabarinath VP, Hazarey PV, Ramakrishna Y, Vasanth R, Girish K. Caring for cleft lip and palate infants: Impression procedures and appliances in use. *The Journal of Indian Prosthodontic Society*. 2009 Apr 1; 9(2): 76.
- Jacobson BN, Rosenstein SW. Early maxillary orthopedics for the newborn cleft lip and palate patient. An impression and an appliance. *Angle Orthod*. 1984 Jul; 54(3): 247–63. Pubmed PMID: 6385784.
- Phillips RW, Anusavice KJ. *Phillips' science of dental materials*. Elsevier/Saunders; 2013.
- Doubleday B. Impression materials. *Br J Orthod*. 1998 May; 25(2): 133–40.
- Loeffelbein DJ, Rau A, Wolff K-D. Impression technique for monitoring and virtual treatment planning in nasoalveolar moulding. *Br J Oral Maxil-*

- lofac Surg. 2013 Dec; 51(8): 898–901. Pubmed PMID: 23414909.
- [37]. Liao YF, Hsieh YJ, Chen IJ, Ko WC, Chen PKT. Comparative outcomes of two nasoalveolarmolding techniques for unilateral cleft nose deformity. *Plast Reconstr Surg.* 2012 Dec; 130(6): 1289–95. Pubmed PMID: 23190811.
- [38]. Liou EJ-W, Subramanian M, Chen PKT, Huang CS. The progressive changes of nasal symmetry and growth after nasoalveolarmolding: a three-year follow-up study. *Plast Reconstr Surg.* 2004 Sep 15; 114(4): 858–64. Pubmed PMID: 15468390.
- [39]. Raffat A, Ijaz A. Premaxillary retraction in bilateral complete cleft lip and palate with custom made orthopaedic plate having anterior acrylic ring. *J Pak Med Assoc.* 2009 Jun; 59(6): 376–80. Pubmed PMID: 19534372.
- [40]. Grayson BH, Maull D. Nasoalveolar molding for infants born with clefts of the lip, alveolus and palate. *In: Cleft Lip and Palate.* 2006; 451–458.
- [41]. Titiz S. Preoperative nasoalveolar moulding in a patient with a unilateral cleft lip and palate using a modified nostril retainer: a technical note. *British Journal of Oral and Maxillofacial Surgery.* 2019; 383–4. Pubmed PMID: 30987749.
- [42]. Murthy PS, Deshmukh S, Bhagyalakshmi A, Srilatha K. Pre surgical nasoalveolarmolding: changing paradigms in early cleft lip and palate rehabilitation. *J Int Oral Health.* 2013 Apr; 5(2): 70–80. Pubmed PMID: 24155594.
- [43]. Pai BCJ, Ko EWC, Huang CS, Liou EJW. Symmetry of the nose after presurgical nasoalveolarmolding in infants with unilateral cleft lip and palate: a preliminary study. *Cleft Palate Craniofac J.* 2005 Nov; 42(6): 658–63. Pubmed PMID: 16241178.
- [44]. Yu Q, Gong X, Shen G. CAD presurgical nasoalveolar molding effects on the maxillary morphology in infants with UCLP. *Oral Surgery, Oral Medicine, Oral Pathology and Oral Radiology.* 2013; 116(4): 418–26. Pubmed PMID: 24035109.