

## Prevalence Of Posterior Alveolar Bone Dehiscence And Fenestration In Adults Reporting For Orthodontic Treatment - A CBCT Study

Research Article

Akriti Tiwari<sup>1</sup>, Ravindra Kumar Jain<sup>2\*</sup>, Remmiya Mary Varghese<sup>3</sup>

<sup>1</sup> Department of Orthodontics and Dentofacial Orthopaedics, Saveetha Dental College and Hospital, Saveetha Institute of Medical and Technical Sciences, Saveetha University, 162, Poonamallee High Road, Chennai-600077, Tamil Nadu, India.

<sup>2</sup> Associate Professor, Department of Orthodontics and Dentofacial Orthopaedics, Saveetha Dental College and Hospital, Saveetha Institute of Medical and Technical Sciences, Saveetha University 162, Poonamallee High Road, Chennai-600077, Tamil Nadu, India.

<sup>3</sup> Senior Lecturer, Department of Orthodontics and Dentofacial Orthopaedics, Saveetha Dental College and Hospital, Saveetha Institute of Medical and Technical Sciences, Saveetha University 162, Poonamallee High Road, Chennai-600077, Tamil Nadu, India.

### Abstract

Identifying alveolar bony fenestration and dehiscence prior to orthodontic treatment is helpful to orthodontists for several reasons. Incidence of alveolar bone dehiscence and fenestrations may lead to gingival recession, decreasing bony support of teeth. An undetected and undiagnosed buccal alveolar bone defect poses a greater potential for treatment relapse. The aim of this study was to determine the prevalence of posterior alveolar bony dehiscence and fenestration in adults undergoing orthodontic treatment. A total of 30 subjects in the age range 18-35 years who had reported for Orthodontic treatment at the Department of Orthodontics were selected for this study randomly and their CBCT records were retrieved from the Department of Radiology, Saveetha Dental College and Hospitals. All statistical analysis was performed using IBM SPSS version 23. A chi-square test was used to determine the association of fenestrations and dehiscence between males and females. The prevalence of dehiscence was found to be 40% in females and 36% in males whereas fenestration was found to be 35% in males and 40% in females. There was a statistically significant association of dehiscence width in females and wider dehiscence were noted in females ( $p=0.019$ ,  $p<0.05$ ). There was a statistically insignificant association of fenestration prevalence between males and females. ( $p=0.178$ ,  $p>0.05$ ) Within the limits of this study, it was observed that females are more prone to bony alveolar dehiscence and fenestration when compared to males.

**Keywords:** Prevalence; Dehiscence; Fenestrations; Alveolar Bony Dehiscence.

### Introduction

Identifying alveolar bony fenestration and dehiscence prior to orthodontic treatment is helpful to orthodontists for several reasons [7]. Studies have shown that the incidence of alveolar bone dehiscence and fenestration may lead to gingival recession, decrease bony support of teeth [17, 15]. An undetected and undiagnosed buccal alveolar bone defect poses a greater potential for treatment relapse [13]. This leads to unaesthetic finishing of orthodontic treatment and tooth sensitivity. Orthodontic treatment if not carried out properly can lead to fenestration and dehiscence.

Detection of alveolar bony dehiscence and fenestration is not possible with traditional 2-dimensional imaging. With the advent

of CBCT, it's now possible to view these defects three-dimensionally [6]. Timock et al reported that the accuracy and reliability of buccal bone height and thickness measurements from CBCT are acceptable and appropriate [9]. Studies have examined alveolar bony dehiscence using CBCT in children with cleft lip and palate, adolescents undergoing rapid maxillary expansion and in different malocclusions [1, 2, 16].

However, there has been no study examining alveolar bony defects in adults undergoing orthodontic treatment. It's recommended that orthodontists know the anatomical limits of tooth movement to be aware of potential periodontal problems that can worsen during orthodontic treatment [4, 5]. CBCT has a high specificity and high negative predictive value for both dehiscence and fenestration but a low positive predictive value [8]. Leung et

#### \*Corresponding Author:

Ravindra Kumar Jain,  
Associate Professor, Department of Orthodontics and Dentofacial Orthopaedics, Saveetha Dental College and Hospital, Saveetha Institute of Medical and Technical Sciences, Saveetha University 162, Poonamallee High Road, Chennai-600077, Tamil Nadu, India.  
Tel: +919884729660  
E-mail: ravindrakumar@saveetha.com

**Received:** September 07, 2020

**Accepted:** September 27, 2020

**Published:** September 30, 2020

**Citation:** Akriti Tiwari, Ravindra Kumar Jain, Remmiya Mary Varghese. Prevalence Of Posterior Alveolar Bone Dehiscence And Fenestration In Adults Reporting For Orthodontic Treatment - A CBCT Study. *Int J Dentistry Oral Sci.* 2020;S1:02:0011:52-55. doi: <http://dx.doi.org/10.19070/2377-8075-SI02-010011>

**Copyright:** Ravindra Kumar Jain ©2020. This is an open-access article distributed under the terms of the Creative Commons Attribution License, which permits unrestricted use, distribution and reproduction in any medium, provided the original author and source are credited.

al reported that the value of CBCT is having a relatively high accuracy to diagnose dehiscence and fenestration [7]. Orthodontists using bony defects data as a precaution prior to treatment can be viewed as overestimation to the side of caution rather than giving misinformation. As long as CBCT users understand the extent of its accuracy, clinicians can still use the bony defect information within the boundaries of the overestimation limit.

The aim of this study was to determine the prevalence of posterior alveolar bony dehiscence and fenestration in adults undergoing orthodontic treatment.

## Materials and Methods

### Study design

This was a retrospective study. CBCTs of 30 Adults subjects aged 18 to 35 years old were collected from the records of patients reporting for Orthodontic treatment at the department of Orthodontics Saveetha dental college.

Inclusion criteria for the study were

1. Class 1 malocclusion subjects with minimum crowding, good periodontal health.

### Exclusion criteria

1. Obvious pathologies like cyst or tumour, bony pathologies and congenital defects
2. Multiple carious lesions, restoration, abfraction, or abrasions, missing posterior teeth.
3. History of previous orthodontic treatment.

After applying the inclusion and exclusion criteria, CBCTs of 10 males and 10 females were included in the study.

### Sampling method

To minimize sampling bias, simple random sampling was carried out. The investigator A.T. did not have access to the subject-spe-

cific demographic information of the CBCT DICOM files until the study was completed.

### Bony defect measurement method- Upper

All CBCT images were viewed and measured using dolphin imaging 11.8 premium software by the same investigator (A.T). The image was oriented using the FH line so that the FH plane is parallel to the floor and the midsagittal plane perpendicular to the FH plane. Each posterior quadrant was viewed in a multiplanar view with 3 times magnification. Once enlarged, the posterior segment was lined up anteroposteriorly on the axial view.

For the lesion to be counted as dehiscence, it had to be equal to or larger than 2mm in its vertical distance from CEJ. This was done to eliminate counting normal bone level as dehiscence, which is usually 1.5-2mm below the CEJ. There was no minimum required lesion size for fenestration. If any amount of bone was denuded on the root surface but not continuous to the marginal bone, it was counted and measured as a fenestration.

### Statistical Analysis

All statistical analysis was performed in IBM SPSS version 23. A Chi-square test was done to determine the association of alveolar bony defects in males and females.

## Results and Discussion

### Out of the 20 cbct

A tooth was counted as a tooth with bony defect when there was a bony defect on one side, either mesial or distal, or on both sides. Table 1 depicts the mean and standard deviation of bony defects. Table 2 depicts the association of fenestrations and dehiscence of males and females. Females had more wider dehiscence defects than males and this was statistically significant Chi-square test ( $p=0.019$ ,  $p<0.05$ ) whereas fenestration defects were not different in males and females Chi-square ( $p=0.178$ ,  $p>0.05$ ). Fig 1 and fig 2 represents the association of fenestration and dehiscence in

**Table 1. Associations between the mean width of fenestration and dehiscence of genders in the study population.**

Gender	N	Mean width
Fenestration Males	5	1.40 ± .516
Females	7	1.70 ± .153
Dehiscence Males		1.40 ± .163
Females	10	1.90 ± .100

Depicting mean and standard deviation of bony defects

**Table 2. Association of fenestrations and dehiscence of the genders in the study population.**

	Value	df	Asymptotic Significance (2 sided)
Pearson's chi-square Dehiscence	5.495	1	0.019
Fenestration	1.818	1	0.178

Depicting chi-square test for associations between the genders

Figure 1. Bar chart representing the association of gender and frequency of dehiscence. X axis represents the width of the dehiscence and Y axis represents the gender. Pearson's chi square value- 5.49, p value-0.019 (<0.05) hence its statistically significant.

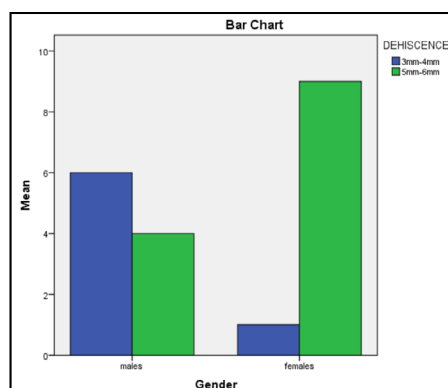
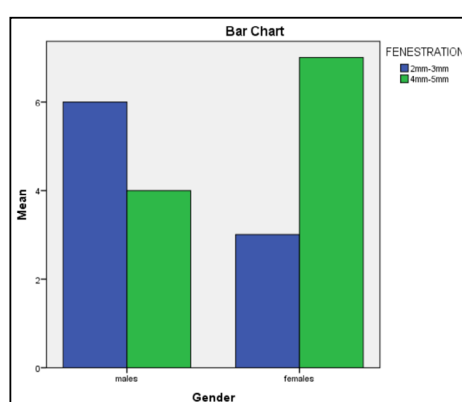


Figure 2. Bar chart representing the association of gender and frequency of fenestration. X axis represents the width of the fenestration and Y axis represents the gender. Pearson's chi square value-1.818, p value-0.178 (>0.05) hence its not significant.



males and females.

On studying the prevalence of fenestration and dehiscence in males and females it was reported that there was a statistically significant association of dehiscence in females than males. There was no statistically significant association of fenestration between males and females. Regarding patient selection, growing patients were not included in the study, as previous studies have shown that hormonal and functional changes associated with age influence cortical bone thickness [14, 12]. In our study CBCT was used since it is the imaging of choice in orthodontics nowadays since a 3-dimensional view of the entire dentition and craniofacial structures but due radiation concerns, CBCT should not routinely be considered in orthodontics [11].

Rupprecht et al., conducted a prevalence study of dehiscence and fenestration in modern American skulls and reported that African-American males and Caucasian females were significantly more likely to have dehiscences, while African-American females were significantly more likely to have fenestrations but this was a craniometric study whereas the present study involved CBCT [7]. Similarly, Ana et al reported that the percentage of teeth with considerable bone loss was higher in females, but was not significantly associated [10]. Choi et al reported that adults in crossbite reported higher prevalence to total bony defects and dehiscence but an association was not performed between males and females [3].

The overall consensus in the available literature on this topic

agrees with the findings of the present study. The limitation of this study was a small sample size. Since this was a retrospective study, the settings of the CBCT images could not be controlled. Dehiscence and fenestrations do not have a specific geometric shape, so changing the orientation of the image can slightly change the measurements on measuring vertical diameter.

Future scope indicates that investigations should be carried out pre- and post orthodontic treatment. Study larger sample size, more no. of teeth should be evaluated and type of malocclusion should be taken into consideration.

## Conclusion

Within the limitations of this study it can be concluded that in females dehiscence defects were more wider than males but no gender association was seen for fenestration.

## References

- [1]. Baysal A, Uysal T, Veli I, Ozer T, Karadede I, Hekimoglu S. Evaluation of alveolar bone loss following rapid maxillary expansion using cone-beam computed tomography. *Korean J Orthod.* 2013 Apr;43(2):83-95. PubMedPMID: 23671833.
- [2]. Buyuk SK, Ercan E, Celikoglu M, Sekerci AE, Hatipoglu M. Evaluation of dehiscence and fenestration in adolescent patients affected by unilateral cleft lip and palate: A retrospective cone beam computed tomography study. *Angle Orthod.* 2016 May;86(3):431-6. PubMedPMID: 26284755.
- [3]. Choi JY, Chaudhry K, Parks E, Ahn JH. Prevalence of posterior alveolar bony dehiscence and fenestration in adults with posterior crossbite: a CBCT

- study. *ProgOrthod*. 2020 Mar 16;21(1):8. PubmedPMID: 32173764.
- [4]. Coşkun İ, Kaya B. Appraisal of the relationship between tooth inclination, dehiscence, fenestration, and sagittal skeletal pattern with cone beam computed tomography. *Angle Orthod*. 2019 Jul;89(4):544-551. PubmedPMID: 30741575.
- [5]. Hwei PC, Thomas JT. Role of periodontal therapy in rapid tooth movement. *IOSP J Med Dent Sci*. 2014;13:62-5.
- [6]. J PC, Marimuthu T, C K, Devadoss P, Kumar SM. Prevalence and measurement of anterior loop of the mandibular canal using CBCT: A cross sectional study. *Clin Implant Dent Relat Res*. 2018 Aug;20(4):531-534. PubmedPMID: 29624863.
- [7]. Leung CC, Palomo L, Griffith R, Hans MG. Accuracy and reliability of cone-beam computed tomography for measuring alveolar bone height and detecting bony dehiscences and fenestrations. *Am J OrthodDentofacialOrthop*. 2010 Apr;137(4 Suppl):S109-19. PubmedPMID: 20381751.
- [8]. Sun L, Zhang L, Shen G, Wang B, Fang B. Accuracy of cone-beam computed tomography in detecting alveolar bone dehiscences and fenestrations. *Am J OrthodDentofacialOrthop*. 2015 Mar;147(3):313-23. PubmedPMID: 25726398.
- [9]. Timock, A. M. et al. (2011) 'Accuracy and reliability 137(4 Suppl), pp. S109–19.
- [10]. Malčić AI, Vodanović M, Matijević J, Mihelić D, Mehičić GP, Krmek SJ. Caries prevalence and periodontal status in 18th century population of Požega-Croatia. *Arch Oral Biol*. 2011 Dec;56(12):1592-603. PubmedPMID: 21714956.
- [11]. Meena N, Kowsky RD. Applications of cone beam computed tomography in endodontics: A review. *Dentistry*. 2014 Jan 1;4(7):1.
- [12]. Papadopoulos MA. *Skeletal Anchorage in Orthodontic Treatment of Class II Malocclusion E-Book: Contemporary applications of orthodontic implants, miniscrew implants and mini plates*. Elsevier Health Sciences; 2014 Sep 29.
- [13]. Rothe LE, Bollen AM, Little RM, Herring SW, Chaison JB, Chen CS, et al. Trabecular and cortical bone as risk factors for orthodontic relapse. *Am J OrthodDentofacialOrthop*. 2006 Oct;130(4):476-84. PubmedPMID: 17045147.
- [14]. Usui T, Uematsu S, Kanegae H, Morimoto T, Kurihara S. Change in maximum occlusal force in association with maxillofacial growth. *OrthodCraniofac Res*. 2007 Nov;10(4):226-34. PubmedPMID: 17973690.
- [15]. Xu G, Ren S, Wang D, Sun L, Fang G. Fabrication and properties of alkaline lignin/poly (vinyl alcohol) blend membranes. *BioResources*. 2013 Apr 2;8(2):2510-20.
- [16]. Yagci A, Veli I, Uysal T, Ucar FI, Ozer T, Enhos S. Dehiscence and fenestration in skeletal Class I, II, and III malocclusions assessed with cone-beam computed tomography. *Angle Orthod*. 2012 Jan;82(1):67-74. PubmedPMID: 21696298.
- [17]. Zachrisson BU, Alnaes L. Periodontal condition in orthodontically treated and untreated individuals. II. Alveolar bone loss: radiographic findings. *Angle Orthod*. 1974 Jan;44(1):48-55. PubmedPMID: 4520950.