

## Psoas Muscle, An Exceptional Location for Cystic Echinococcosis About a Case

Case Report

S. Ammari<sup>1\*</sup>, N. Nait Slimane<sup>1</sup>, Y. Benhocine<sup>2</sup>, N. Bounab<sup>1</sup>, A. Bouzid<sup>1</sup>, L. Merakeb<sup>1</sup>, M. Taieb<sup>1</sup>

<sup>1</sup> General Surgery department, Ain Taya Hospital, Algiers, Faculty of Medicine of Algiers, Algiers University 1, Algeria.

<sup>2</sup> Anesthesia – Resuscitation Department, Tizi-Ouzou University Hospital, Algeria.

### Abstract

**Introduction:** Primary extra-hepatic and extra-pulmonary locations of cystic echinococcosis are rare. Psoas muscle, is one of the unusual locations of cystic echinococcosis, Few series of cases have been reported.

**Purpose:** report a new case of psoas muscle cystic echinococcosis, and review the literature to discuss diagnostic circumstances and therapeutic modalities

**Observation:** A 29-year-old man, consulted for painful swelling, extending from the right flank of the abdomen to the root of the right thigh. Preoperative diagnosis is facilitated by ultrasound, CT, and serology. The patient is operated by a median laparotomy. The intimate relationship of the cyst with the adjacent structures including the nerve structures prevented the realization of a complete kystectomy. Post-operative evolution is simple. An Albendazole-based medical treatment was associated in post-operative for one year.

**Conclusion:** Psoas muscle is one of the rare locations of cystic echinococcosis. Know how to think about it before any lumbar or iliac cystic formation. Surgical treatment remains the first line of therapy.

**Keywords:** Cystic Echinococcosis; Hydatid Cyst; Psoas muscle.

### Introduction

Cystic echinococcosis, a name now replacing that of hydatid cyst. It's a cosmopolitan anthrozoosonose, widespread throughout the world [1]. Liver is the most frequently affected organ (50% to 70%), followed by the lung (20% to 30%) [2]. Primary muscle location is exceptional, and uncommon, accounting for 0.4% to 1% of all locations [2]. The pathophysiology of psoas muscle involvement remains hypothetical and imprecise [3]. The symptomatology is poor, and variable. Preoperative diagnosis is based on ultrasound, CT and serology. Treatment, can be radical, by a complete cystectomy, or conservative, by a partial resection of the cyst, with treatment of the parasite, and prevention of recurrence. Our aim is report a new case of psoas muscle cystic echinococcosis, and to review the literature to discuss diagnostic circumstances and therapeutic modalities.

### Observation

A 29-year-old patient, with no history of disease, consulted for right iliac fossa (RIF) and right thigh root pain, evolving since two weeks. The clinical examination finds a patient in good general condition, afebrile, body mass index (BMI) at 25. Visible and palpable oblong mass occupying right flank, the RIF, and the root of the right thigh; it was firm, painless, adherent to the deep plane, extended on about 20 cm of long axis. There's a limitation in the extension of the right thigh in relation to psoitis. Digital rectal exam was without anomalies, hernial orifices were free.

Abdominal ultrasound showed a multicystic mass of the right iliac psoas muscle, compressive, evoking cystic echinococcosis.

Abdominopelvic computed tomography (CT-scann) found a multi-loculate formation, with a bi-sac wall, of the right pelvic retroperitoneum, contained a central calcification, measuring 22.2

#### \*Corresponding Author:

Smail Ammari,  
General Surgery Department, Ain Taya Hospital, 16029, Algiers, Algeria.  
Faculty of Medicine of Algiers, Ben Youcef Ben Khedda University Algiers 1.  
Tel: +213771396182  
E-mail: s.ammari@univ-alger.dz

**Received:** August 01, 2023

**Accepted:** August 23, 2023

**Published:** September 04, 2023

**Citation:** S. Ammari, N. Nait Slimane, Y. Benhocine, N. Bounab, A. Bouzid, L. Merakeb, M. Taieb. Psoas Muscle, An Exceptional Location for Cystic Echinococcosis About a Case. *Int J Surg Res.* 2023;9(2):171-175.

**Copyright:** S. Ammari<sup>©</sup> 2023. This is an open-access article distributed under the terms of the Creative Commons Attribution License, which permits unrestricted use, distribution and reproduction in any medium, provided the original author and source are credited.

cm high by 9.9 cm x 9.5 cm of transverse axis, extending from the retrocecal region to the root of the right thigh through the crural orifice.

Hydatic serology using the ELISA technique was positive (3.28 IU/L). Intradermal reaction (IDR) to tuberculin was negative. Other biological tests were normal.

We operated on the patient. Laparotomy under umbilical. Intraoperative exploration found a large retro peritoneal cystic mass, protruding under the right psoas muscle aponeurosis. This collection extended from the root of the psoas muscle at the height of the 3rd and 4th lumbar vertebra to the right coxo-femoral joint about 20 cm tall and 10 cm wide, pushing the right colon forward and towards the midline.

The attempt to perform a closed complete cystectomy was unsuccessful due to the cyst's intimate contact with adjacent structures,

particularly the nerves of the right lower limb.

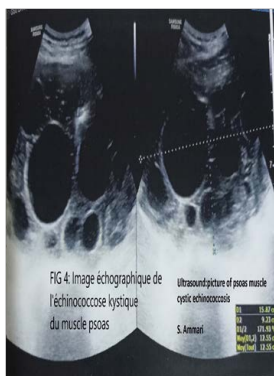After protecting the abdominal cavity with compresses soaked with hydrogen peroxide, we proceeded to a complete aspiration of the cyst, treatment of the parasite and sterilization of the residual cavity with hydrogen peroxide, with partial resection of the cystic cavity.

A drainage irrigation system left in the residual cavity. In postoperative, it allowed us to do iterative washings of this cavity.

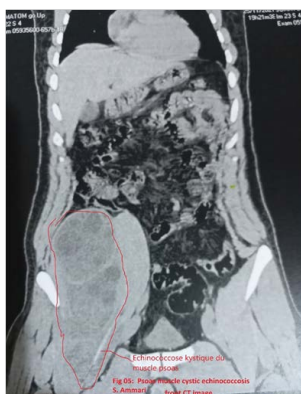Postoperative recoveries were simple and the patient was released on the 7th post-operative day.

Medical treatment, based on Albendazole at a rate of 10 mg/kg/day for one year (Started one month before the intervention and continued for one year), no recurrence noted.

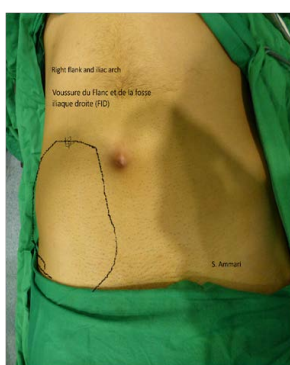
**Figure 1: Psoas muscle cystic echinococcosis ultrasound image**



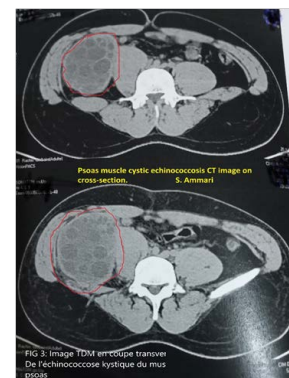**Figure 3: Psoas muscle cystic echinococcosis Front CT image**



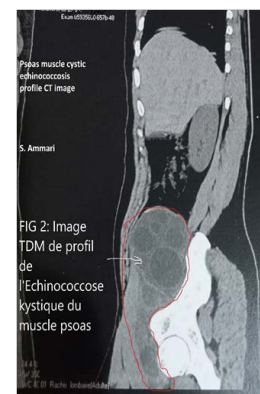**Figure 5: Intraoperative photo of the right side arch and right iliaca fossa**



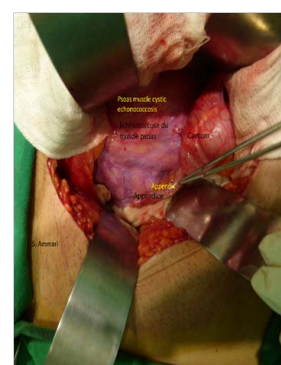**Figure 2: Psoas muscle cystic echinococcosis CT image on cross-section**



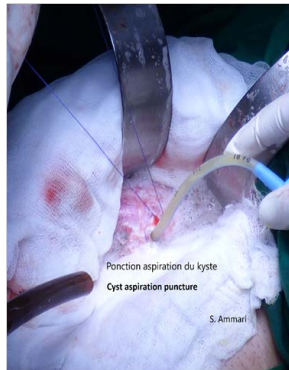**Figure 4: Psoas muscle cystic echinococcosis profile CT image**



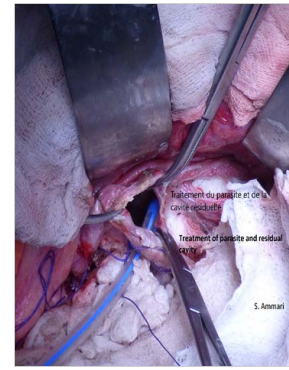
**Figure 6: Intraoperative photo of the hydatic cyst of the psoas, pushing back the right colon**



**Figure 7: Intra-operative photo of the puncture and aspiration of the cyst**



**Figure 8: Intra-operative photo of parasite sterilization and residual cavity treatment**



## Discussion

The liver, then the lung, are the first filters that limit the passage of echinococcus granulosus to the general circulation. Rare to have primary involvement to other organs without liver and/or lung involvement. The psoas muscle, is one of the exceptional and uncommon locations of cystic echinococcosis.

The scarcity of muscular location is due to several factors, including the difficulty of local implantation of the embryo, caused by continuous muscle contractions and the production of lactic acid hindering the nesting of the embryo [3-5], the efficacy of liver and pulmonary filters that oppose the easy migration of the hexacanth embryo into the systemic circulation [6, 7], the alternating muscle contraction-relaxation does not allow uniform vascularization and exerts a compression preventing the parasite fixation on the muscle [6, 8-10]. Finally, the absence of particular tropism of echinococcosis strains for muscle is the last possibility reported by the authors [6, 11].

The pathophysiology of psoas muscle hydatid cyst involvement remains hypothetical. Several contamination pathways are possible. First, the haematogenic pathway; after passing the liver and lung filters, the larva of the echinococcus granulosus is carried by the great circulation and is located in the most richly vascularized organs including the spleen, and muscles [3]. The second reported, is lymphatic contamination pathway or shunt from the gastrointestinal tract [2, 3]. For our patient, these two contamination pathways are possible, and could explain this primitive localization in the psoas muscle. Other contamination pathways, have been reported, such as contiguous contamination from vertebral hydatidosis is possible [3, 12]. This last mentioned contamination pathway is not consistent with the case of our patient, who does not have a spinal injury.

Clinical manifestations of cystic echinococcosis of psoas muscle are variable. It's generally a banal swelling, of slow evolution, long well supported, and therefore unknown [2]. Some cysts may be revealed by complications such as nerve compression, urinary, vascular, or haematogenic superinfection that can lead to sometimes severe sepsis [4, 13]. For our patient, the revelation of this disease was made by a painful swelling occupying the right flank, and the right iliac fossa (FID) of the abdomen.

Imaging allows visualization of the hydatid cyst and its constituent parts. His techniques are efficient and allow to establish a diagno-

sis, to judge complications, to carry out mass tests, and to perform instrumental treatments [2]. Ultrasound is a reliable examination and can clarify the hydatid nature of the cyst in more than 95% of cases [3, 6, 14-16]. Ultrasound is superior to CT for identification of the hydatid nature of the cyst, but the latter is more effective in the accuracy of its topography and ratios [3]. Ultrasound can also be used to specify the type according to Gharbi classification (16) and vascular and urinary ratios [3] [17]. The use of high-frequency probes refines the ultrasound study of the cystic wall [5]. Computed tomography (CT) shows morphological aspects similar to those shown by ultrasound [3, 5, 9, 18]. Cystic echinococcosis is characterized by the absence of contrast enhancement after injection [3]. The additional contribution of CT, compared to ultrasound, lies in accurate topographical diagnosis [3, 5, 18]. Moreover, CT is very useful in the precision of the hydatid nature of a mass (In case of type IV ultrasound) [3]. For our patient, ultrasound and CT have greatly contributed and facilitated positive diagnosis, with accurate topographical diagnosis to CT.

Magnetic resonance imaging (MRI) is reserved for cases where the diagnosis remains doubtful [3, 17]. The cyst image appears as a multi-vesicular lesion with or without peripheral hypo-signal on the T1 and T2-weighted Rim-sign sequences. There is often a parietal enhancement after gadolinium injection [6, 19, 20]. MRI, allows a detailed study of the wall, and cystic content [21]. It is useful in assessing cyst vitality by showing a hyper-signal in the daughter vesicles on T2-weighted sequences [6, 19]. In our case, MRI was not necessary.

Arteriography and cavography are currently abandoned. These two invasive scans were previously performed to assess the vascular impact of a retro peritoneal cyst [3].

Biology is essentially hydatid serology. It's of great diagnostic value when it is positive [4]. Its main role lies in post-operative surveillance, looking for a possible recurrence, when it shows an ascent in antibody levels [3]. The qualitative (Immunoelectrophoresis, electrosyneresis) and quantitative methods (Indirect Haem agglutination, Immunofluorescence, ELISA) are difficult to interpret, however, the Western Blot and Immunoprint are more sensitive and specific [5, 13]. In order to improve the sensitivity/specificity ratio, most authors prefer to combine two serological techniques, one quantitative: indirect haemagglutination, immunofluorescence, ELISA and the other qualitative: immunoelectrophoresis, electrosyneresis [4, 22]. In the case of our patient, ELISA is the technique that was used.

Eosinophilia is inconstant [3, 23]. It is concomitant with the invasion phase fades rapidly, sometimes persisting (in 7-15% of cases) at a moderate level. It may reappear during cyst cracking but fails in case of bacterial superinfection [2].

Surgery remains the first-line treatment for cystic echinococcosis of psoas. Medical treatment with Albendazole or Mebendazole remains an alternative for inoperable cases or in case of massive recurrence in addition to surgery [24]. In our patient, Albendazole has been systematically associated with surgical treatment. More recently, laparoscopy has been used, and its indications are being evaluated, it is a pathway that is not yet validated [2, 5, 25, 26].

Classical surgery remains the gold standard for cystic echinococcosis. The extraperitoneal surgical pathway is preferable to avoid any risk of intraperitoneal hydatid dissemination [24, 27, 28]. The transperitoneal pathway through a median, may be useful to treat at the same time other associated intraperitoneal hydatid lesions and especially hepatic [3]. Sometimes the recommended median incision, due to the large volume of the cyst [3]. In our case, we used the transperitoneal medial pathway because of the large volume of the cyst.

To avoid the spread of hydatid fluid and especially scolex in the abdominal cavity, it is essential to protect the surgical field by compresses soaked with parasiticide solutions [2].

Radical treatment is based on total kystectomy. However, adhesions to vasculonerveux elements can make this complete resection difficult or even dangerous [24]. Association with vertebral involvement is another contraindication of total cyst ectomy since, in this case, the parasite behaves maliciously by developing between bone trabecles without forming a clean cystic wall [24, 29].

In some situations, radical treatment is impossible to achieve; it is then necessary to limit to a partial cyst, leaving a pericyst cap against the vascular and nervous elements to avoid their trauma during dissection [3]. In our case, we tried in vain to achieve a total kystectomy; the volume of the cyst and its intimate relations with the vasculonerous structures intended for the lower limbs, forced us to limit ourselves to a partial kystectomy. The depth of the residual cavity, prompted us to leave in place an irrigation-drainage system, in order to carry out repeated washings postoperatively; thus, avoiding complications of the residual cavity, especially infectious complications.

Based on the literature, mortality is estimated at 4% and morbidity at 8.6% [3]. Paresthesia, in the territory of the crural nerve, may persist in postoperative stages due to intra-operative microtrauma of this nerve and which are often self-limiting [22, 30]. In our patient, mobility and mortality are zero, no recurrence is noted after one year of follow-up.

## Conclusion

Psoas muscle is one of the uncommon locations of cystic echinococcosis. The rarity of this muscular localization is due to several factors, including difficulty of local implantation of the embryo, caused by continuous muscle contractions and the effectiveness

of liver and lung filters. Clinical symptomatology is not specific. The diagnosis must be evoked before any lumbar or iliac fluid mass. Confirmation is based on imaging (Ultrasound, and CT), and hydatid serology. Radical total kystectomy surgery should be preferred whenever possible. Medical treatment remains an alternative for inoperable cases or in case of massive recurrence in addition to surgery. Prevention remains the best treatment.

## Ethics Approval

The results of this work come from a thesis work carried out by the main author (S. Ammari), and supervised by Professor M. Taieb at general surgery department of Ain Taya University Hospital.

Before starting this thesis work. A project was submitted to 03 experts at Algiers Faculty of Medicine who gave their approval to begin this research work. Thus, we had the authorization of the scientific council of Algiers faculty of medicine.

All patients are consenting for their inclusion in this work and for the publication of the results.

## Funding

Funding will be provided by the lead author, with no funding from any other source.

## References

- Gomez I Gavara C, López-Andújar R, Belda Ibáñez T, Ramia Ángel JM, Moya Herraiz Á, Orbis Castellanos F, et al. Review of the treatment of liver hydatid cysts. *World J Gastroenterol*. 2015 Jan 7;21(1):124-31. PubMed PMID: 25574085.
- Carmoi T, Farthouat P, Nicolas X, Debonne JM, Klotz F. Hydatid cysts of the liver. *EMC*. 2008: 7-023.
- Bedioui H, Nouira K, Daghfous A, Ammous A, Ayari H, Rebai W, et al. Primary hydatid cyst of the psoas muscle: description of 9 cases in Tunisia and review of the literature. *Med Trop (Mars)*. 2008 Jun;68(3):261-6. PubMed PMID: 18689318.
- Alaoui I, Hjouji F, Doumbia M, Aoufi S, Lyagoubi M. Hydatid cyst of the psoas muscle: about a case. *Pan Afr Med J*. 2016 Aug 9;24:302. PubMed PMID: 28154657.
- Soufi M, Lahlou MK, Messrouri R, Benamr S, Essadel A, Mdaghri J, et al. Hydatid cyst of the psoas: a report of two cases. *J Radiol*. 2010 Dec;91(12 Pt 1):1292-4. PubMed PMID: 21242912.
- Mseddi M, Mtaoumi M, Dahmene J, Ben Hamida R, Siala A, Moula T, et al. Hydatid cysts in muscles: eleven cases. *Rev Chir Orthop Reparatrice Appar Mot*. 2005 May;91(3):267-71. PubMed PMID: 15976671.
- Bendib A, Bendib S, Benmamar L, Hansal MT, Bendib M. X-ray computed tomography of hydatid cyst of the liver: symptomatology and classification. Apropos of 157 cases including 146 surgically confirmed. *J Radiol*. 1985 May;66(5):367-75. PubMed PMID: 3897521.
- Chigot JP, Ben hamida M, Mercadier M. About a case of muscular hydatid cyst. *Gaz Med*. 1974;81:5313-5317.
- Kehila M, Allegue M, Abdessalem M, Letaief R, Said R, Khalfallah A, et al. Hydatid cyst of the psoas muscle. Apropos of a case. *J Radiol*. 1987 Apr;68(4):265-8. PubMed PMID: 3295225.
- Saad H, Hamdi A, Gargouri R, Zouari K, Sghaier MS, Balti MH, et al. Hydatid cyst of the psoas muscle. Apropos of 3 cases. *Ann Chir*. 1990;44(4):299-301. PubMed PMID: 2192683.
- Bonitacino A, Carino R, Caratozzolo M. Ultrasonography in hydatidosis. International symposium on hydatidology. *Med Chir Dig*. 1989;18:301-12.
- El Moussaoui A, Rabii R, Rais H, Aboutaieb R, Meziane F, El Mrini M, et al. Hydatid cyst of the psoas muscle. Apropos of a case. *Ann Urol (Paris)*. 1997;31(6-7):357-60. PubMed PMID: 9509237.
- El Malki HO, El Mejdoubi Y, Bouslami B, Mohsine R, Ifrine L, Belkouchi A. Hydatid cyst of the psoas muscle. *Sante*. 2007 Jul-Sep;17(3):177-9. PubMed PMID: 18180220.

- [14]. El Fortia M, Bendaoud M, Shaban A, Gharbi H, Ehtwaish F, Roberts D, et al. Subcutaneous extension of a large psoas muscle Echinococcus cyst. *Eur Radiol.* 2000;10(5):870. PubMed PMID: 10823651.
- [15]. Hammami T, Noomane F, Ketata M, Ganneme Y, Nasr M, Zouari K, et al. Hydatid cyst of the thigh: three cases. *Rev Chir Orthop Reparatrice Appar Mot.* 2002 Apr;88(2):193-6. PubMed PMID: 11973552.
- [16]. Lamine A, Fikry T, Zryouil B. Primary hydatidosis of the peripheral muscles. 7 case reports]. *Acta Orthop Belg.* 1993;59(2):184-8. PubMed PMID: 8372655.
- [17]. Daali M, Hssaida R. Muscle hydatidosis. 15 cases. *Presse Med.* 2000 Jun 17;29(21):1166-9. PubMed PMID: 10906934.
- [18]. von Sinner WN, Stridbeck H. Hydatid disease of the spleen. Ultrasonography, CT and MR imaging. *Acta Radiol.* 1992 Sep;33(5):459-61. PubMed PMID: 1389656.
- [19]. García-Díez AI, Ros Mendoza LH, Villacampa VM, Cózar M, Fuertes MI. MRI evaluation of soft tissue hydatid disease. *Eur Radiol.* 2000;10(3):462-6. PubMed PMID: 10756997.
- [20]. Alexiadis G, Lambropoulou M, Deftereos S, Papadopoulos N, Manavis J. Primary muscular hydatidosis. US, CT and MR findings. *Acta Radiol.* 2002 Jul;43(4):428-30. PubMed PMID: 12225488.
- [21]. Ben M'Rad. Multiple hydatidosis of the thigh: Role of magnetic resonance imaging. *J Radiologie.* 1998;79:877-19.
- [22]. Benchekroun A, Jira H, Cheikhani OJ, Kasmaoui EH, Zannoud M, Faik M. Hydatid cyst of the psoas. Report of a case. *Ann Urol (Paris).* 2001 Mar;35(2):108-10. PubMed PMID: 11355279.
- [23]. Louchi A, Chtata H, Araoui M, Zizi A. Hydatid cyst of the psoas. *Ann Chir.* 2001 Oct;126(8):820-1. PubMed PMID: 11692777.
- [24]. El Khassoui A, Aghoutane EM, Salama T, El Fezzazi R. Psoas Hydatid Cyst in Children: A Rare Localization about a Case. *Case Rep Pediatr.* 2021 Nov 6;2021:1961509. PubMed PMID: 34782851.
- [25]. Dziri C, Haouet K, Fingerhut A. Treatment of hydatid cyst of the liver: where is the evidence? *World J Surg.* 2004 Aug;28(8):731-6. PubMed PMID: 15457348.
- [26]. Oubejja H, Khalloufi N, Kisra M, Ettayeb F. Laparoscopic treatment of psoas hydatid cyst, about a case. *J Coelio.* 2008;68:14-18.
- [27]. Louchi A, Chtata H, Araoui M, Zizi A. Hydatid cyst of the psoas. *Ann Chir.* 2001 Oct;126(8):820-1. PubMed PMID: 11692777.
- [28]. Abdellaoui H, Bouabdallah Y. Enucleation of a hydatid cyst of the psoas muscle in a child. *Pan Afr Med J.* 2019 Jan 3;32:3. PubMed PMID: 31068997.
- [29]. Angulo JC, Granell J, Muguerra J, Sanchez-Chapado M. Primary bilateral hydatidosis of the psoas muscle. *J Urol.* 1999 May;161(5):1557-8. PubMed PMID: 10210396.
- [30]. Kafih M, Ajbai M, Ridai M, Idrissi H, Zerouali O. Hydatid cyst of the psoas muscle. *Ann Gastroenterol Hepatol (Paris).* 1993 May;29(3):110-2. PubMed PMID: 8517623.