

## Cheiloscopy: A Tool For Sex Identification

Review Article

Neelkamal<sup>1</sup>, Jyoti<sup>2\*</sup>, Divya<sup>2</sup>

<sup>1</sup> Assistant Professor, Department of Genetics, Maharshi Dayanand University, Rohtak, Haryana, India.

<sup>2</sup> PG Students of Forensic Science in Department of Genetics, Maharshi Dayanand University, Rohtak, Haryana, India.

### Abstract

The purpose of this study is to estimate sex from lip print pattern. Sex estimation is important to identify whether the crime has been committed by a male or female or to identify the perpetrator. Cheiloscopy is the study of lip print pattern, which is very useful in forensic identification of a person. Lip prints are actually lines and fissures in the form of wrinkles in the zone of transition of lip i.e. red part of lips. These ridges, grooves or wrinkles are studied for the purpose of positive identification of a person. Lip prints can also prove to be as one of the best method of personal identification. Lip print is unique to individual and thus can be used for identification purpose. Lip prints are important evidence in case like sexual assault, murder, rape and also remain at scene of crime unknowingly on cups, glasses, cigarette butts, clothing's, skin etc.

**Keywords:** Forensic Science; Cheiloscopy; Lip Prints; Ridges; Grooves; Forensic Identification.

### Introduction

Human identification is an universal and important process. This is based on various scientific methods considering fingerprint analysis, DNA analysis. As we know that fingerprints are unique for every person and they help in their personal identification. Similarly lip print is unique to individual and thus also used for the identification purposes. Cheiloscopy deals with the furrow and grooves (elevation & depressions) present on lips. These grooves are called sulci labarum. These grooves are unique to person to person and can be used to reveal the identity of a person just as fingerprints and DNA profiling [1, 2]. Hence lip prints can be used to verify the presence or absence of a person at scene of crime [3, 4].

Study of lip prints or Cheiloscopy is very important method used in forensic discipline. In the last few years we have seen a great development in the use of lip prints, which may be useful in identification and for the diagnosis of congenital diseases and anomalies etc [5]. Cheiloscopy techniques have an equal value in relation to other types of forensic evidence for personal identification and sex determination [6, 7]. Lip prints help in linking a crime, suspect and scene of crime. This is the trace evidence

which helps in excluding a person from the list of suspects. Lip prints are an important evidence in case like sexual assault, murder, rape and also remain at scene of crime unknowingly on cups, glasses, cigarette butts, clothing's, skin etc [8].

During few years various studies were carried out by several researchers in India and in other countries. Different aspects of lip prints were studied like stability, uniqueness, characters on the bases of which sex of a person can be determined on the basis of lip prints and various other morphological characters among different groups of population.

Classification of lip prints is based on the patterns of wrinkles or grooves on the vermillion border of the lips.

Dr. Santosh in 1966 divided the nature of wrinkles and grooves into simple and compound types [9].

### Simple

When they are formed only by one element

- Straight line

#### \*Corresponding Author:

Jyoti,  
Forensic Science in Department of Genetics, Maharshi Dayanand University, Rohtak, Haryana -124001, India.  
Tel: +91-7206428199  
E-mail: jyotihd19@gmail.com

**Received:** January 09, 2016

**Accepted:** February 11, 2016

**Published:** February 15, 2016

**Citation:** Neelkamal, Jyoti, Divya (2016) Cheiloscopy: A Tool For Sex Identification. *Int J Forensic Sci Pathol*. 4(2), 221-226. doi: <http://dx.doi.org/10.19070/2332-287X-1600053>

**Copyright:** Jyoti<sup>©</sup> 2016. This is an open-access article distributed under the terms of the Creative Commons Attribution License, which permits unrestricted use, distribution and reproduction in any medium, provided the original author and source are credited.

- Curved lines
- An angled line

**Compound**

When they are formed by several elements.

- Bifurcated
- Trifurcated
- Anomalous groups

Classification based on their thickness [9].

- Thin lip prints: These are seen among European people.
- Medium lip prints: These are 8-10 mm in thickness, in which the pink zone is found to be more rounded found in general population.
- Thick lip prints: These are very big in which the labial string appears inverted and mainly found in Negros.
- Mixed lip prints: This type of lip was may commonly seen in oriental people.

Lip prints were classified into 6 types according to the shape and course of the grooves as shown in below [10] (Table 1 and Figure 1).

French scientist Renaud studied about 4000 lip print patterns and classified lip prints into A-J categories [11] (Table 2 and Figure 2).

Classification of pattern of lines on the red part of the lips given by Kasprzak is as follow [12, 13] (Figure A-D).

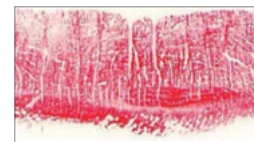
- If the lines prevail, the pattern is described as linear “L”

**Figure. A**



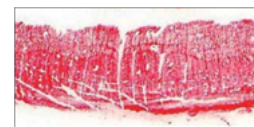- If the bifurcation is dominant, it is called bifurcation “R”

**Figure. B**



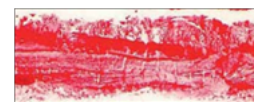
- If the lines cross the pattern is dubbed reticular “S”

**Figure. C**



- In case where there is no superiority can be estimated the pattern is named undetermined “N”

**Figure. D**



**Table 1. Suzuki and Tsuchihashi lip prints classification.**

Classification	Groove type
Type I	Complete vertical
Type I'	Incomplete vertical
Type II	Branched
Type III	Intersected
Type IV	Reticular pattern
Type V	Irregular

**Figure 1.**

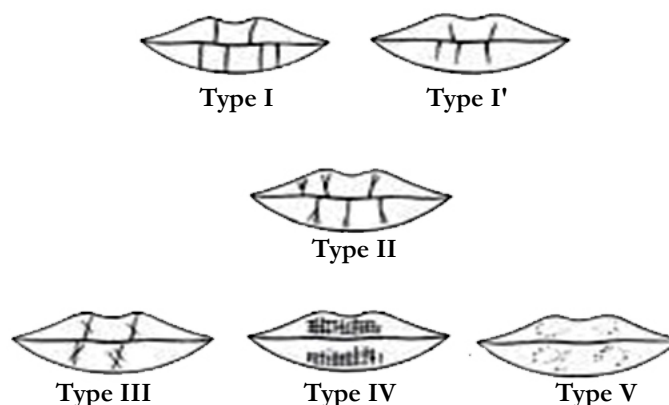
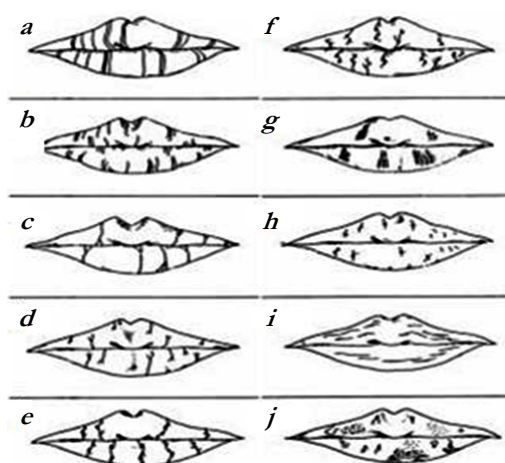


Table 2. Renaud lip prints classification.

Classification	Groove type
A	Complete vertical
B	Incomplete vertical
C	Complete bifurcated
D	Incomplete bifurcated
E	Complete branched
F	Incomplete branched
G	Reticular pattern
H	X or coma form
I	Horizontal
J	Others forms (ellipse, triangle)

Figure 2.



Classification, given by Afchar-Bayar M in 1979, based on a six-type groove organization [14] (Table-3).

**Materials and Methodology**

The present study was conducted on 72 individuals (36 males and 36 females) in the age group from 1-40 and above who were randomly selected. First group: 1-10 year's individuals. Second group: 11-20 year's individual. Third group: 21-30 year's individuals. Forth group: 31-above year's individuals. In each group 9 males and 9 females were included. The materials used were dark colored lipstick, bond paper, cellophane tape, a brush for applying lipstick uniformly, and a magnifying lens. Lipstick was applied on the vermillion border of the lips. Lipstick was evenly distributed on the lips. The subject was asked to rub the lips against each other to spread lipstick. After it a sufficient portion of cellophane tape was taken and pressed against lips, and thus impressions were transferred to tape which was then slicked on the white paper for permanent records (Figure 3).

**Result**

Lip prints were obtained from which were randomly selected from different places in Rohtak District of Haryana State, India. The samples were analyzed by simple percentage method. For

group 1<sup>st</sup> are, total 18 individuals were included 9 males and 9 females. In total most common type of lip print pattern is III i.e. 35 %, then comes type I i.e. 25 %, then each I', II and V are 10 % type IV is absent (Table 4).

Type III was the most common type of lip print pattern in this group.

In group 2 total 18 individuals were included 9 males and 9 females (Table 5).

Type II was the most common type of pattern in this group.

In group 3 total 18 individuals were included 9 males and 9 females. Type V patterns are absent in both male and female this group (Table 6).

Type III was the most common type of pattern found in this group.

In group 4 again total 18 individuals were included 9 males and 9 females type I' not found in both male & female, type II also not found in both male & female (Table 7).

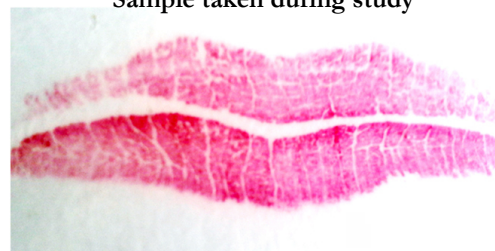
Type III was the most common type of pattern found in this group.

**Table 3. Afchar-Bayar M classification system.**

Classification	Groove type
A1	Vertical and straight grooves, covering the whole lip
A2	Like the former, but not covering the whole lip
B1	Straight branched grooves
B2	Angulated branched grooves
C	Converging grooves
D	Reticular pattern grooves
E	Other grooves

**Figure 3. (Type I lip print).**

Sample taken during study



**Table 4. Percentage of group 1 (age 1-10).**

Type	Female	% age	Male	% age	Total	% age
I	4	40%	1	10%	5	25%
P	1	10%	1	10%	2	10%
II	1	10%	1	10%	2	10%
III	1	10%	6	60%	7	35%
IV	--	--	--		--	--
V	2	20%	--		2	10%
Total	9		9		18	

**Table 5. Percentage of group 2 (Age 11-20).**

Type	Female	% age	Male	% age	Total	% age
I	1	10%	2	20%	3	15%
P	-	--	1	10%	1	5%
II	3	30%	3	30%	6	30%
III	1	10%	2	20%	3	15%
IV	2	20%	1	10%	3	15%
V	2	20%	-		2	10%
Total	9		9		18	

**Table 6. Percentage of group 3 (age 21-30).**

Type	Female	% age	Male	% age	Total	% age
I	4	40%	1	10%	5	25%
P	1	10%	2	20%	3	15%
II	1	10%	--	--	1	5%
III	2	20%	6	60%	8	40%
IV	1	10%	--	--	1	5%
V	--		--	--	--	--
Total	9		9		18	

Table 7. Percentage of group 4 (Age 30 &amp; above).

Type	Female	% age	Male	% age	Total	% age
I	3	30%	2	20%	5	25%
I'	-	--	--	--	--	--
II	-	--	--	--	--	--
III	3	30%	3	30%	6	30%
IV	2	20%	3	30%	5	25%
V	1	10%	1	10%	2	10%
Total	9		9		18	

Table 8. Shows the total percentage of different type lip patterns.

Type	Female	% age	Male	% age	Total	% age
I	12	33.3%	6	16.7%	18	25%
I'	2	5.6%	4	11.1%	6	8.35%
II	5	13.9%	4	11.1%	9	12.5%
III	7	19.4%	17	47.2%	24	33.3%
IV	5	13.9%	4	11.1%	9	12.5%
V	5	13.9%	1	2.8%	6	8.35%
Total	36	100%	36	100%	72	100%

## Discussion

In present study as per the classification method of Suzuki and Tsuchihashi Type I pattern is mainly found in females while in males Type III is found. Sex of a person can be successfully determined with the help of lip print patterns.

According to previous studies it was found that Type I and Type I' is most frequently found in females while in males Type III, Type IV and Type V were dominating. Besides this no other lip print pattern matches with each other and are unique to every individual [15-18]. According to another study, Type I and Type I' patterns were found to be dominant in females, while Type III and Type IV patterns dominant in males. Lip prints are dissimilar among different individuals [19].

In other previous studies it was concluded that Type III was the most predominant pattern in Indo-Dravidian population. Type III is the most predominant pattern in males, followed by Type II, Type IV, Type I and Type V patterns. In females, Type II appears to be the most predominant pattern followed by the Type IV, Type I, Type III and Type V patterns. The predominant pattern in the overall population (both males and females) was Type II pattern followed by Type III, Type IV and Type V patterns [20, 21].

In another study from India male and female subjects in Maharashtra were studied and sex determination was correctly done in 65 males and 67 females with high degree of accuracy [22]. Other studies showed the pattern types found in the different populations like in Punjabi population the vertical pattern (Type I) was the most common lip print pattern in both the sexes [23]. It was found that intersecting pattern was most common, both among males and females having 39.5 and 36.5%, respectively. However, the least common was the reticular pattern seen in

11.0% males and 13.0% females [24]. The most frequent is type IV, which is the reticular type of lip print [25]. Another study showed that no lip prints matched with each other. Also, lip-prints did not change on repeated sampling [26].

## Conclusion

In all the previous studies conducted on lip prints the lip print pattern in a population was studied. In present study lip prints are used as a sex determination tool and according to age group lip prints are studied. The lip prints are compared for sexual identification. This study has proved that (Cheiloscopy) lip prints hold the potential to identify the sex (whether male or female) and identity of the individual, as they remain unchanged over the time and unique to individual. There is a positive result for the application of lip prints in forensic investigation and criminal cases. Hence it is concluded that lip prints can be used as sex estimation tool.

## References

- [1]. Sivapathasundharam B, Parkash PA, Sivakumar G (2001) Lip prints (Cheiloscopy). *Indian J Dent Res* 12(4): 234-237.
- [2]. Rajendran R, Sivapathasundharam B (2006) Shafer's Textbook of Oral Pathology. (5<sup>th</sup> edtn), Elsevier, New Delhi, India. 1199-1224.
- [3]. Choras M (2007) Human lips Recognition. In Computer recognition system 2 advances in soft computing. Springer Berlin Heidelberg. 45: 838-843.
- [4]. Tsuchihashi Y (1974) Studies on personal identification by means of lip prints. *Forensic Sci* 3(3): 233-248.
- [5]. Suzuki K, Tsuchihashi Y, Suzuki H (1968) A trial of personal identification by means of lip prints-I. *Jap J Leg Med* 22: 392.
- [6]. Bindal U, Jethani SL, Mehrotra N, Rohatgi RK, Arora M, et al. (2009) Lip prints as a method of identification in human being. *J Anat Soc India* 58(2): 152-155.
- [7]. Dongarwar GR, Bhowate RR, Degwekar SS (2013) Cheiloscopy- Method of person identification and sex determination. *Scientific Report* 2(1): 612.
- [8]. Singh NN, Brave VR, Khanna S (2010) Natural dyes versus lysochrome dyes in Cheiloscopy: a comparison evaluation. *J Forensic Dent Sci* 2(1): 11-17.

- [9]. Santos M (1967) Cheiloscropy: A supplementary stomatological means of identification. *Brazil Int Microform J Leg Med* 2: 66.
- [10]. Suzuki K, Tsuchihashi Y (1971) A new attempt of personal identification by means of lip print. *Can Soc Forensic Sci J* 4(4): 154-158.
- [11]. Renaud M (1973) L'identification chéiloscopique en médecine légale. *Le chirurgien dentiste de France* 65-69.
- [12]. Kasprzak J (1990) Possibilities of Cheiloscropy. *Forensic Sci Int* 46(1): 145-151.
- [13]. Kasprzak J, Leczynska B (2000) Cheiloscropy. In *Encyclopedia of forensic science*. Academic Press, London. 1: 358-361.
- [14]. Afchar-Bayar M (1978) Determination de l'identité par les empreintes des lèvres chez les femmes de Iran. *Société de Médecine Legale* 589-592.
- [15]. Vahanwala S, Nayak CD, Pagare SS (2005) Study of lip prints as an aid of sex determination. *Medico-Legal Update* 5(3): 93-98.
- [16]. Vahanwala SP, Parekh BK (2000) Study of lip prints as an aid of forensic methodology. *J Indian Dent Assoc* 71: 269-271.
- [17]. Sharma P, Saxena S, Rathod V (2009) Cheiloscropy: The study of lip prints in sex identification. *J Forensic Dent Sci* 1(1): 24-27.
- [18]. Randhawa K, Narang RS, Arora PC (2011) Study of the effect of age changes on lip print pattern and its reliability in sex determination. *J Forensic Odontostomatol* 29(2): 45-51.
- [19]. Suzuki K, Tsuchihashi Y (1975) Two criminal cases of lip print. *ACTA Criminol Jpn* 41: 61-64.
- [20]. Kumar GS, Vezhavendhan N, Vendhan P (2012) A study of lip prints among Pondicherry population. *J Forensic Dent Sci* 4(2): 84-87.
- [21]. Verma K, Meenakshi, Sharma S (2014) Lip print patterns among the students of Maharshi Dayanand University (MDU) Rohtak, Haryana. *Int J Pharm Bio Sci* 4(2): 210-217.
- [22]. Gondivkar SM, Indurkar A, Degwekar S, Bhowate R (2009) Cheiloscropy for sex determination. *J Forensic Dent Sci* 1(2): 56-60.
- [23]. Sandhu SV, Bansal H, Monga P, Bhandari R (2012) Study of lip print pattern in a Punjabi population. *J Forensic Dent Sci* 4(1): 24-28.
- [24]. Saraswathi TR, Mishra G, Ranganathan K (2009) Study of lip prints. *J Forensic Dent Sci* 1(1): 28-31.
- [25]. Verghese AJ, Shashidhar CM (2011) A study of Efficacy of Lip Prints as an Identification Tool among the People of Karnataka in India. *J Indian Acad Forensic Med* 33(3): 200-202.
- [26]. Singh H, Chhikara P, Singroha R (2011) Lip prints as evidence. *J Punjab Acad Forensic Med Toxicol* 11(1): 23-25.