

Forehead Morphology Pattern: Does it indicate the Potential Existence of the so-called Forehead Print?

Case Study

Nagy A

Forensic Consultant and Forensic DNA Expert, Associate Professor of Forensic Medicine and Toxicology, Forensic Medicine, College of Medicine, Al-Qassim University, Buraida City, KSA, Saudi Arabia.

Abstract

Forehead is a part of the human body that never been used in forensics or studied for its potential usefulness in forensics. No one ever talked about the variability of forehead morphology among individuals or how can forehead and/or its impression potentially be used for forensic individual identification.

In the present study, forehead images were taken for the foreheads of 800 unrelated consented male subjects, volunteers of the Egyptian origin, ranging in age from 10 to over 70 years. Careful examination of the collected forehead images was conducted by the naked eye observation for the existence of forehead wrinkles or any thing else on the forehead that can be specific for the forehead of the individual such as dermatological lesion/s, recent wound or scar of old wound or anything else that can be of value in the individual identification. Forehead wrinkles were examined for the number, shape, position and direction. Forehead could be categorized according to the morphology of the wrinkling pattern that they have. There are two types of forehead wrinkles, horizontal and vertical. Forehead examined for the age of appearance of forehead wrinkles and for the persistence of the wrinkling pattern. Forehead wrinkles have been proven that they are persistent and when they appear, they remain throughout the lifetime. Forehead wrinkles have been examined for their shape during different expressions to see what they look like during these expressions. Foreheads were also examined to see what one can rely upon in identification of forehead, especially when the forehead wrinkles are absent.

Keywords: Forehead; Wrinkles; Pattern; Forensic; Identification.

*Corresponding Author:

Dr. Nagy Alfadaly MBCh, MSc, PhD (UK),
Forensic Consultant and Forensic DNA Expert, Associate professor of
Forensic Medicine, College of Medicine, Qassim University, Buraida,
KSA, Saudi Arabia.
Tel: 00966-543474172
E-mail: nmbayoumy@yahoo.co.uk

Received: August 05, 2015

Accepted: October 14, 2015

Published: October 16, 2015

Citation: Nagy A (2015) Forehead Morphology Pattern: Does it indicate the Potential Existence of the so-called Forehead Print?. *Int J Forensic Sci Pathol.* 3(10), 179-189. doi: <http://dx.doi.org/10.19070/2332-287X-1500044>

Copyright: Nagy A[®] 2015. This is an open-access article distributed under the terms of the Creative Commons Attribution License, which permits unrestricted use, distribution and reproduction in any medium, provided the original author and source are credited.

Introduction

One of the main principles which support the classical forensic science identification is the *principle of uniqueness*. This principle can be summed up in the phrase 'Nature never repeats itself', which is attributed to the Belgian Quételet, and is echoed in claims like 'All fingerprints/ears/voices are unique' [1-3].

In the contemporary forensic science more and more attention has been paid to those traces, which until recently were considered untypical, such as lip, nose or forehead impressions or ear impressions. It should be clearly stated that the value of those traces is not directly related to the frequency of their occurrence but should be attributed to the increased potential of human identification thus contributing to an improved effectiveness of law enforcement [4].

Forehead is a part of the human body that has never been used in forensics or studied for its potential usefulness in forensic identification. No one has ever talked about the variability of forehead morphology among individuals or how can forehead and/or its impression be used for the forensic reasons, particularly individual identification.

I have reviewed the currently available forensic literature, looked for anything related to the so-called a forehead print or forehead wrinkling pattern and the use of its diversity among individuals in forensics but unfortunately, i could find nothing about this issue. All I have found was a few number of research articles, one of them about the use of forehead wrinkles in the estimation of age [5] and the rest about the forehead wrinkles, skin aging and its treatment such as botox and cosmetic surgery [6, 7]. Forehead is a part of face and plays an important role in facial recognition. Face recognition is a remarkable process and the human brain has the ability and capacity to distinguish between many known and unknown faces with a high speed. The biggest advantage of using the face (over other parts of the human body) in many applica-

tions is that the face is always with the person. Moreover, the face carries a significant number of features that identify individuals such as gender, emotional state, ethnic origin, age [8].

It has been pointed that there are several types of facial wrinkles and none of them have been studied more, nor rise as high in concern from a cosmetic point of view, as the lines and grooves associated with facial expression [9].

I have decided to penetrate the secrets of the human forehead to find out about its diversity among individuals and consequently its potential usefulness in forensic identification. The same as ear print, forehead print can potentially be found at the scene of crime when the intruder tries to look through the door or window glass to see what is behind or how the inside looks like. While he is doing so, his forehead print can be transmitted to the glass surface. In such circumstances the forensic scientist can only benefit from this print if recognized rules for forehead print identification are available.

The forehead constitutes the upper third of the face [10]. It is bounded from above by the scalp hairline, below by the glabella and the supra-orbital ridges and on both sides by the temporal ridges [11]. The scalp hairline is not a stable landmark among individuals; factors of sex, age, familial characteristics, and the influences of culture and fashion decide the hairline position for individuals [10].

The forehead consists mainly of three components from back to front, which are bone, muscles and skin. The bony part of the forehead is the plate-like part of the frontal bone, which is known as the squama frontalis [12]. The squama frontalis forms the scaffold on which the soft tissues are draped. The frontal bone presents an anterior surface of the forehead that is convex anteriorly [10].

The muscles of the forehead and the other muscles of the face differ in function than skeletal muscles elsewhere in the body whose function is to move bone, the physiology of forehead muscles with the other muscles of the face, is unique in that its primary function is to move skin (an exception would be the masseter needed for chewing) [9].

The musculature of the forehead consists of two groups of muscles. The first one consists of Occipitofrontalis muscles, which elevate the eye brows. The second group consists of procerus, corrugator superciliaris and the orbital portion of the orbicularis oculi muscles, which depress the eye brows and/or bring them closer. Both of the elevator and depressor muscles are innervated by the temporal and frontal branches of the facial nerve [13].

The muscles of the forehead help to form facial expressions. There are four basic motions, which can occur individually or in combination to form different expressions [14]. The movements of the muscles in the forehead produce characteristic wrinkles in the skin. The Occipitofrontalis muscles run vertically from the top of the head to the eye brows. They consist of two parts, inner and external part [15]. The Occipitofrontalis muscles can raise the eyebrows, either together or singly, forming expressions of surprise and quizzicality [14]. Contraction of the inner part of the frontalis muscle produces transverse wrinkles across the width of the forehead, known as worry lines [16]. The Corrugator superciliaris muscles can pull the eyebrows inwards and down, form-

ing a frown. The contraction of corrugator superciliaris muscles produces vertical wrinkles between the eyebrows above the nose, which are known as frown lines and they contract when the person is concentrating or angry [6]. The Procerus muscles can pull down the centre portions of the eyebrows. Their contraction causes the nose to wrinkle [14].

Skin of the forehead is a multilayered tissue consisted of three main layers, epidermis, dermis and hypodermis. The skin is connected to the underlying musculature via connective tissue and the muscles are attached to the skull bone [9]. The skin of the forehead is the thickest facial skin and is rich in sebaceous glands and sweat glands. The subcutaneous tissue is rich in blood vessels and contains a homogenous layer of adipose tissue [10]. Cua et al in 1995 measured skin surface lipid content with the dynamic friction coefficient in different anatomical regions of the skin including the forehead with respect to age, sex and anatomical region. He found that the lipid content was statistically lower on the forehead in females. His research suggests that surface lipid content plays a limited role in frictional properties of skin [17].

Forehead wrinkles

Wrinkles are folds, ridges or creases in the skin. They can be temporary or persistent. The age-related changes in temporary and persistent facial skin wrinkling occur very slowly over a person's lifetime [18]. The presence of wrinkles is a sign, which indicates that the skin's "Recovery Ability" has declined progressively with age. However, extreme variability in onset and progression makes it difficult to quantify the relationship of wrinkling patterns to age [19]. Wrinkles in the skin can also be caused by habitual facial expressions, sun damage, smoking and poor hydration [20]. Other factors are also known to cause help in causing wrinkling by inducing the dermal thickening and dermal deterioration such as degenerative environmental, hormonal, genetic factors and repetitive mechanical stress [19]. The hormonal changes, sun exposure, and smoking are well known to accelerate the onset and rate of skin aging, including the acceleration of facial wrinkling [18]. The age of onset and rate of persistent facial wrinkling is dependent on the cumulative amount of mechanical stress (frequency of temporary wrinkling) in combination with the decline in skin elasticity [9].

Regarding the direction, the forehead wrinkles are classified into two types horizontal and vertical. The horizontal (transverse) wrinkles are the most common ones, which appear in the form of lines that run horizontally across the entire forehead [7]. Within the forehead area, there are numerous transverse fibrous septa radiating from the occipitofrontalis muscles to the dermis. These septa are partially responsible for formation of the transverse forehead wrinkles [10]. The other type occurs in the form of deep vertical wrinkles that appear in the central area of the lower forehead between the eyebrows, which are known as frown lines [7]. They are caused by contraction of the corrugator superciliaris muscles [21].

There are several types of facial wrinkles classified with consideration to their location, pattern, histology and etiology [22].

Dermatologists and cosmetic surgeons use two accepted classifications of face ageing stages according to the face wrinkling. The first one is the Fitzpatrick classification of facial lines, which determines the degree of wrinkling focusing on the wrinkling

around the mouth and eyes.

It has three classes. Class I: Fine wrinkles, Class II: Fine-to-moderately deep wrinkles and moderate number of lines. Class III: Fine-to-deep wrinkles, numerous lines, and possibly redundant folds [6]. The second classification is Glogau's classification, which describes the facial wrinkling in four degrees in a simple way as follow: Degree 1: mild wrinkling, where there are a few wrinkles that are hard to see. Degree 2: moderate wrinkling where parallel lines start to appear only on motion (Dynamic wrinkles). Degree 3: advanced or persistent wrinkling where wrinkles are seen on resting (static wrinkles). Degree 4: Severe wrinkling where severe wrinkles and furrows are seen [23].

Wrinkles can also be classified regarding the appearance and/or disappearance into temporary and persistent wrinkles. Temporary wrinkles (dynamic lines) appear in the skin during the process of muscle contraction and disappear when the facial muscles relax providing the human face with the unique ability to express emotion. On the other hand, persistent wrinkles (static lines) are visible at rest without muscle contraction [9]. It is reported that the wrinkles start first as temporary ones, however, with the advancement of age they are transformed into persistent one [6].

It is an indisputable fact that skin develops wrinkles with age. The presence of wrinkles is a sign that the skin's "Recovery Ability" has declined progressively with age. However, extreme variability in onset and progression makes it impossible to quantify the relationship of wrinkling patterns to age [19]. Not only aging but also repetitive mechanical stress is known to play a role in the formation and progression of facial wrinkling [9]. Muscle contraction which occurs during everyday facial expression, forces the skin to repetitively fold along the same groove. With time, this repeated mechanical stress causes that groove or temporary wrinkle to etch in as a permanent or persistent wrinkle [24].

The wrinkles are produced in the skin of the forehead due to irregular thickening of the dermis and of a decrease in the amount of water held by the epidermis. This is mainly caused by long time exposure to ultraviolet light of the sun through the years and exposure to environmental toxins particularly tobacco smoke [6]. Other causes of wrinkling include cigarette smoking, chronological aging, individual sleep patterns, gravitational effects and the way our muscles of the face move when the person smiles, laughs, eats and drinks [25].

The visual assessment of wrinkles of the forehead and temporal region has recently been used for the approximate estimation of age of the governmental employees whose ages range from 25-45 years. In this study, no wrinkles could be detected in the foreheads of the control groups whose ages range from 25 – 35 years. While the Forehead wrinkles were detected in the control groups whose ages range from 36- 45 years [5]. It is an indisputable fact that skin develops wrinkles with age. However, extreme variability in onset and progression makes it impossible to quantify the relationship of wrinkling patterns to age.

It is supposed that muscles of the face on both sides work symmetrically, but this is not true. In a study carried out about the asymmetries in facial actions, several different models have proposed to invoke specialization of function of the right, the left, or both hemispheres to explain asymmetries in facial actions. The

results showed existence of asymmetry with the deliberate actions, which was more than that with the spontaneous actions. The results also indicated that asymmetry of deliberate actions is not caused by hypothesized laterality of emotion. Instead, they suggested that asymmetry was related to differentiated motor control on each side of the face [26]. It is supposed that this asymmetry would be responsible for the asymmetry of wrinkles on both sides of the forehead.

Wrinkles treatment

Although wrinkles can be signs of experience and wisdom, most people would rather not have them. There are several medical and cosmetic techniques available for improving or even removing the wrinkles. For several years, surgeons relied on different methods for the correction of scars and wrinkles such as chemical peeling, dermabrasion, surgical scar revision, electrosurgical planning, and dermal/subdermal filler substances (eg, collagen implantation, silicone injection, autologous fat transplantation) [27].

As a general role, superficial wrinkles can be treated by non surgical procedures such as medical treatment, however, the deep wrinkles (furrows) require more aggressive techniques such as cosmetic surgery.

Nonsurgical procedures have become very popular for the rejuvenation of the aging face by removing or decreasing wrinkling. Face wrinkles can be treated topically by tretinoin that involves using Vitamin A in a chemical form to smooth away wrinkles [28].

Tretinoin decreases cohesiveness of follicular epithelial cells and stimulates mitotic activity and increased turnover of follicular epithelial cells, consequently, reduces the appearance of wrinkles through its effects on the follicular cells [29].

Injectable fillers entered mainstream cosmetic medicine with the development of bovine collagen injections in the 1980s. The availability of improved fillers that are less allergenic and longer lasting has resulted in a renaissance in filler techniques [30]. Popularity of such fillers continues to increase as the aging population seeks options to correct the signs of aging without surgery. Fillers such as the hyaluronic acids are obviously one of the key components to the successful combination treatment of the aging face [31].

Botulinum toxin is a neurotoxin protein produced by the bacterium *Clostridium botulinum*. Botox (onabotulinumtoxinA) is a specific form of botulinum toxin manufactured by Allergan Inc (U.S.) for both therapeutic as well as cosmetic use [32]. Wrinkles can also be treated by Botox. Botox is a relatively new procedure in which the skin is injected with proteins that smooth out wrinkles. Botox is so effective and the results so instant that it has become the number one choice for treating age related wrinkles, particularly those around the eyes [33].

Wrinkles can be removed cosmetically by lasers. Over the past decade, advances in laser technology have allowed cosmetic surgeons to diminish the appearance of scars and wrinkles using both ablative and nonablative lasers [35]. Lasers such as fractional CO₂ and Fraxel re:store lasers are the most effective wrinkle treatment. Laser surgery reduces the appearance of wrinkles by using lasers to effectively eliminate fine lines [35].

Aims and objectives

1. To find out if forehead wrinkling pattern is unique for every individual, so we can call its resultant image forehead print.
2. To find out what information one can get from the forehead.
3. To find out the types of forehead regarding their persistent wrinkling pattern that exists during the neutral expression (resting state).
4. To see if the forehead wrinkling pattern is stable during the life (Persistence).
5. To find out how forehead wrinkling pattern is formed.
6. To see what forehead wrinkling pattern looks like during the rest and emotions.
7. To see if there are any other features that one can rely upon in identifying the individual's forehead, especially, in cases when forehead wrinkles are absent.

Materials and Methods

In this study, forehead images were taken for the foreheads of 800 unrelated consented male volunteers of the Egyptian origin, ranging in age from 10 to over 70 years. Careful examination of the collected forehead images was conducted by the naked eye observation for the existence of forehead wrinkles or any thing else on the forehead that can be specific for the forehead of the individual such as dermatological lesion/s, recent wound or scar of an old wound or anything else that can be of value in the individual identification. Forehead wrinkles were examined for the number, shape, position and direction.

Forehead prints were examined for the following aspects

Morphology of the forehead wrinkling pattern: Forehead images were examined for the character of wrinkling pattern (number, shape, position and direction) aiming to set a classification for foreheads according to their wrinkling patterns.

Age of the appearance of forehead wrinkles: Forehead images were examined for presence or absence of the wrinkling pattern relative to the person's age aiming to draw a relationship between the age of the person and appearance of the forehead wrinkles.

Persistence of the forehead wrinkling pattern: Forehead images were taken from some individuals twice with a 10-years interval in between to see how the 10-years period of time would affect the wrinkling pattern.

Morphology of the forehead wrinkling pattern during different expressions: Forehead images were examined during different conditions (rest, surprise, both surprise and frowning simultaneously) to see how the wrinkling pattern looks like during these conditions, to find out which the condition that would have the maximal effect on the establishing and prominence of the forehead wrinkling pattern.

Morphology of the foreheads that do not bear a wrinkling pattern: The foreheads of the individuals which do not bear any wrinkles were examined to find out what other features that can be used to help in the identification of this kind of foreheads.

Morphology of foreheads with bizarre wrinkling patterns: Foreheads with bizarre wrinkling patterns are studied.

Results

Morphology of the forehead wrinkling pattern

There are two types of forehead wrinkles, horizontal and vertical. The horizontal ones appear at the center of the forehead while the vertical ones appear at the glabella (the area between the eye brows).

Morphology of horizontal wrinkles: On examination of the forehead images of the group of individuals with 50-year-old (100 subjects) for the characters of forehead horizontal wrinkles that they have, it was possible to divide the foreheads into four types regarding the presence or absence of wrinkles and the shape, length and distribution of wrinkles (Table 1).

The first type of the foreheads that is having long horizontal wrinkles could be further classified into five subtypes, according to the number of horizontal wrinkles that they have (Table 2).

Due to the variability of foreheads regarding the number and shape of the forehead horizontal wrinkles, it is easy to notice the difference even between the foreheads which are having the same type and number of wrinkles (Figure 1).

Morphology of vertical wrinkles: On examination of the forehead images of the groups of individuals who are 50 years old (100 subjects) for the characters of forehead vertical wrinkles that they have, it was possible to divide the foreheads into four types regarding the shape of wrinkles in the glabellar area between the eye brows (Table 3) (Figure 2).

Age of the appearance of forehead wrinkles

Horizontal wrinkles: Forehead images of all age groups were examined for presence or absence of the persistent horizontal wrinkles relative to the person's age aiming to draw a relationship between the age of the person and the appearance of the horizontal forehead wrinkles. Forehead images are classified into 8 age groups, each group includes 100 individuals, as follow: 10, 20, 30, 40, 50, 60, 70 and over 70-years-old groups (Table 4).

Vertical wrinkles: Forehead images of all age groups were examined for presence or absence of the persistent vertical wrinkles (frown lines). The aim was to draw a relationship for the appearance of the vertical forehead wrinkles relative to the age. Accordingly, forehead images could be classified into 7 age groups as follow, 10- 20, 30, 40, 50, 60, 70 and over 70-years-old groups (Table 5). An example of horizontal and vertical wrinkles of a 40-year old male is displayed (Figure 3).

Persistence of the forehead wrinkling pattern

To study the persistence of forehead wrinkling patterns, forehead images were taken from 25 individuals, twice with a 10-year interval in between to see how the 10-years period of time would affect the wrinkling pattern. The first pictures were taken at the age 40, while the second pictures were taken at the age of 50. It was clear that since the forehead wrinkling pattern has appeared, it remains stable and does not disappear or decrease by time in morphology (shape, direction, position), on the contrary it aggravates by time in these characters. The only difference could be noticed is the size of the wrinkles, represented by depth and width,

Table 1. Foreheads are divided into four main types according to existence or absence of the horizontal wrinkles and the size (length) of wrinkles that they have.

Type	Characters of wrinkles	Number of subjects	Percentage
I	Foreheads with long or continuous wrinkles (wrinkles occupy more than half breadth of the forehead)	79	79%
II	Foreheads with short or sporadically distributed wrinkles (wrinkles occupy half or less than half breadth of the forehead)	6	6%
III	Mixed or composite (long and short) wrinkles	12	12%
IV	Free foreheads with no horizontal wrinkles	3	3%

Table 2. Subtypes of the horizontal wrinkles, according to their number, among the group of individuals with continuous wrinkles.

Subtype	subgroups of horizontal wrinkles	Percentage
1	One wrinkle	18%
2	Two wrinkles	36%
3	Three wrinkles	31%
4	Four wrinkles	12%
5	Five wrinkles	3%

Figure 1. Despite all five forehead images displayed above show presence of two horizontal wrinkles, each has its own specific wrinkling pattern. Differences can be in details such as shape, direction, continuity, level, depth, width of the wrinkling line.

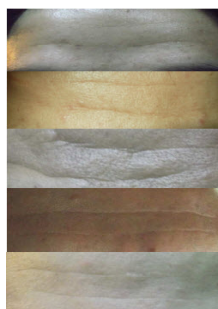

Table 3: The types of vertical forehead wrinkles and the ratios of their distribution among the study groups.

Type	Characters of wrinkles	Number of subjects	Percentage
I	Foreheads with two vertical wrinkles	91	91%
II	Foreheads with one vertical wrinkle	1	1%
III	Foreheads with three vertical wrinkles	2	2%
IV	Foreheads with irregularly-shaped vertical wrinkles	6	6%

Figure 2. Two successive glabellar areas of two male individuals, each is 40-years-old, are displayed. The upper one shows two vertical lines (pointed at by arrows), which represent the vertical wrinkles. The second one shows three vertical lines (pointed at by arrows), which represent the vertical wrinkles. The majority of the vertical wrinkles (91%) are of the first type in which the glabellar area contains just two vertical wrinkles.

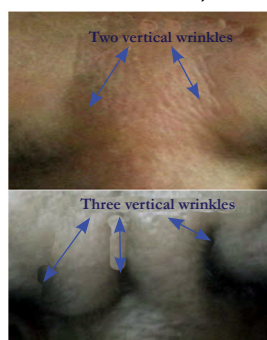


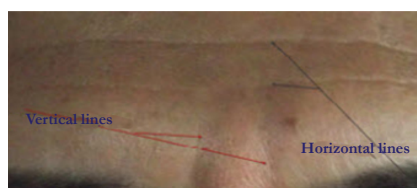Table 4: Percentage of appearance of forehead horizontal wrinkles among the different age groups.

No.	Age groups	Percentage of appearance of forehead horizontal wrinkles among each group
1	10 years	Absence of any wrinkling pattern
2	20 years	12%
3	30 years	36%
4	40 years	74%
5	50 years	97%
6	60 years	99%
7	70 years	100%
8	Over 70 years	100% (wrinkles become more deep and wide)

Table 5. Percentage of appearance of forehead vertical wrinkles among the different age groups.

Age group	Age limit	Percentage of the appearance of forehead vertical wrinkles among different age groups
1	10 -20 years	Absence of any wrinkling pattern
2	30 years	5%
3	40 years	29%
4	50 years	56%
5	60 years	77%
6	70 years	86%
7	Over 70 years and afterwards	93% and they become more clear and evident

Figure 3. A forehead image of a 40-year-old male individual is displayed. One can observe two continuous horizontal wrinkles, running transversally across the whole breadth of the forehead (horizontal lines). Another pair of vertical wrinkles is seen between the eye brows, which are known as frown lines (vertical lines). It was found that at this age, 74% of all individuals are having horizontal wrinkles and 29% of individuals are having vertical wrinkles.



which showed gradual increase. (Figure 4).

Forehead pattern morphology during different expressions

To study the forehead pattern morphology during different expressions, forehead pictures were collected from 25 subjects who are having persistent resting wrinkles, during different conditions, to see how the wrinkling pattern looks like during different expressions (rest, surprise and both of surprise and frowning) and to find out which the condition that would have the maximal effect on the establishing and prominence of the forehead wrinkling pattern. From the examined pictures, it was clear that the contraction of occipitofrontalis muscles, which happens during surprise, is the main factor that results in the formation of the horizontal forehead wrinkles (Figure 5).

Morphology of the foreheads with no wrinkling pattern

Foreheads of the young individuals (as teens), which showed absence of any wrinkling pattern during rest, have been studied to find out what other features that can be used for identification. Despite the foreheads of young individuals were identified by the absence of wrinkles, they could be identified by other things such as the accidental existence of forehead acne lesions (black, white

comedones, acne papules and postules), which are common to find at this age (Figure 6).

Foreheads with bizarre wrinkling patterns

During examination of the forehead images, there were a number of foreheads with bizarre shapes. They have either irregular horizontal wrinkles or wrinkles of different combinations such as crossing wrinkles making rectangular or deltoid or other shapes. Some are horizontal type but with irregular borders. They are minority and less than 1% of the whole forehead images (Figure 7).

The study observations

1. Forehead wrinkling pattern would probably be unique for each individual.
2. Forehead wrinkling pattern does not change by time and as soon as formed it remains throughout the life time and the only change would happen is the increase in its depth and breadth as one gets older.
3. Forehead wrinkling pattern starts to appear in the late teens age in some individuals and in others it starts to appear at later ages until at age of 50 years when the majority of people are having wrinkling pattern and at the age of 60 approxi-

Figure 4. Two successive pictures of the forehead of a male are displayed. They were taken with a 10-years interval in between (at 40 and 50 years old). The upper one was taken in 2001 and the second one was taken in 2011. Naked eye examination reveals the persistence, stability forehead wrinkling pattern with age. It can be easily noticed that the wrinkles are more increase in size (width and depth) by age.



Figure 5. Four successive images of a forehead of a male individual are displayed from above downwards. They show the forehead during different emotional expressions. They show how the forehead wrinkles are formed during the contraction of the muscles of the forehead and exactly in the grooves that are formed as a result of the repeated contraction of these muscles over the years. The upper one shows the forehead during the resting state where two long horizontal wrinkles are seen running across the forehead without contraction of forehead muscles. The second image shows the forehead during smiling and it is noticeable that smiling has shown no significant effect on the forehead wrinkling. The third image shows the forehead during surprise. During this state the occipitofrontalis muscles are moderately contracted on both sides causing increase of the forehead horizontal wrinkling but there are no vertical wrinkles recognized (the area between the eye brows is flat without frown lines). The fourth image shows the forehead during a state of frowning with surprise. During this state both of the occipitofrontalis muscles are highly contracted causing exaggerated horizontal forehead wrinkles and the corrugator superciliaris muscles are contracted too causing appearance of vertical wrinkles (frown lines).

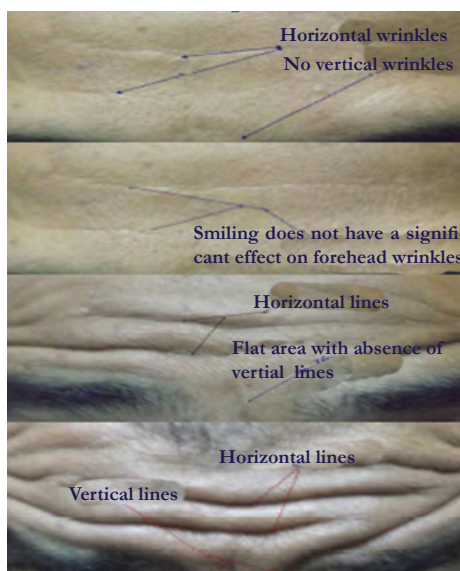


Figure 6. Two forehead images of an 20-year-old male individual are displayed. It is clearly seen in the upper one that he is having active cystic acne lesions. The acne lesions appear in the form of comedones (blackheads and whiteheads), pustules (pimples) and nodules (large papules). There is no evidence of forehead wrinkling, which is rarely seen at this age. In the lower image, his forehead is displayed 6 months later and his forehead acne lesions are healed and nothing left but their scars. In our study, the accidental existence of acne lesions can be used as an indication of the age as the forehead wrinkles appeared in only 12% of this age group (20-years-old).

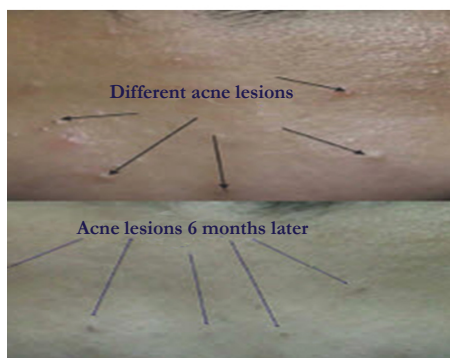
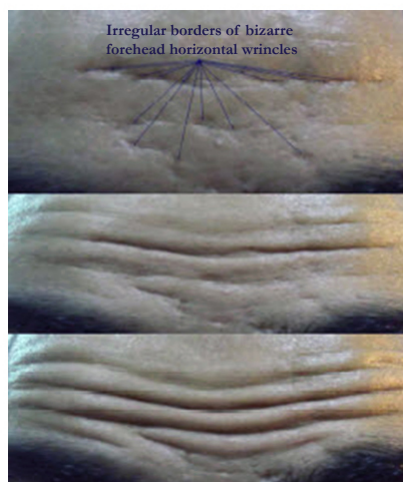

Figure 7. Not all foreheads have the same regular or standard wrinkling pattern, there are foreheads with bizarre wrinkling patterns. Three successive pictures of a forehead of 30-year-old individual are displayed. The first one shows his forehead during the rest with some irregular line-shaped horizontal furrows, which might wrongly be misdiagnose as old scars of lacerated wounds. They are irregular in shape, borders, width and depth. The fact is that these furrows are mere irregular or bizarre wrinkles with no wounds or history of wounding at all. Looking at the second and third images, taken when the subject was in a surprise (moderate and strong surprise, respectively), one can observe that these furrows are real wrinkles and all of them during rest and surprise are matching completely. This kind of bizarre wrinkles is rare (less than 1% of all forehead images). It probably happens in highly emotional individuals. It may refer to the irregularity of the skin of the forehead, scars of pervious acne lesions and /or the irregularity of the contraction of occipitofrontalis muscles.



mately all individuals have shown the existence of forehead wrinkling pattern.

4. During the teens age and early 20s when the forehead wrinkles are still absent, one can rely upon the other forehead features such as acne lesions.
5. Comparing a number of forehead images has shown that due to the certain degree of uniqueness the forehead wrinkling pattern has in addition to its wide diversity, it is probably an easy task to identify a certain forehead among a number of foreheads by comparing the details of the forehead wrinkling patterns along with the other features of the forehead in case they exist.

Discussion

The questions that impose their selves here would be:

Can forehead wrinkles play a role in the individual identification? Is it possible to have a forehead print that can be used in identification based on the variability of the forehead wrinkling pattern? What is the information the forensic expert can get from the forehead wrinkling pattern if he discovers a print at the scene of crime?

In my opinion the forehead print would probably be left at the crime scene in cases when the intruder or the criminal, before committing his crime, tries to look through the window or door glass to see what is happening or to discover if there is anybody inside or what does the place inside look like? First I think one research article like this would never be able to find answers to all these questions and the further research should be concentrating on the forehead print. Aiming to get introductory answers to some of these questions, forehead pictures were collected from male Egyptian volunteers, most of them in the resting state (neutral expression), at different ages. Some were taken twice with a 10-years- interval and others were taken for examination of the forehead morphology pattern during different expressions. The pictures were studied meticulously by the naked eye examination

and obtained results are as follow:

Morphology of the forehead wrinkling pattern

Morphology of horizontal wrinkles: On examination of the forehead pictures of the 50-year-old individuals for the characters of persistent forehead wrinkles that they have during the neutral relaxing state, it was possible to divide the resultant forehead patterns into four types according to the presence or absence of wrinkles and the size of wrinkles when they exist. Type I is characterized by the existence of long continuous horizontal wrinkles, which occupy more than half breadth of forehead. It represents 79% of all foreheads with wrinkles. Type II is characterized by the existence of short horizontal wrinkles which are regularly or sporadically distributed. They occupy half breadth or less than half breadth of the forehead; they commonly are several in number. This type represents 6% of the total number of wrinkled foreheads. Type III is the mixed or composite type. It is characterized by the existence of mixture of both long and short horizontal wrinkles. It represents 12% of the total number of wrinkled foreheads. Type IV is the blank forehead type, whose foreheads do not contain any visible wrinkles during the neutral relaxing state (persistent wrinkles). However, they would appear on other expressions and emotions (temporary wrinkles). It represents 3% of the total number of foreheads. From this classification, it is obvious that type I that is having long horizontal forehead wrinkles is the prevalent among men as it represents 79% of the total numbers of wrinkles foreheads.

Further classification of continuous wrinkles: On examination of the foreheads bearing long continuous horizontal wrinkles, they could be further classified into five subtypes, according to the number of horizontal continuous wrinkles that they bear. The obtained subtypes and their ratios are: one wrinkle 18%; two wrinkles 36%; three wrinkles 31%; four wrinkles 12% and five wrinkles 3%. It is clear from these ratios that forehead subtypes with two and three horizontal wrinkles represent the majority (36% & 31% respectively), however, the other subtypes which

contain either one, four or five wrinkles occur at lower ratios than these ones (18%, 12% & 3% respectively). So, it is obvious from the forehead images we studied that a forehead can carry one or more wrinkles up to five in maximum. However, it is probable that foreheads would have more than 5 if a larger numbers of foreheads are examined. It is clear from this part of the study that people are variable regarding the forehead wrinkles and this could possibly refer to several factors, such as genetic, environmental. Researchers indicated that an individual's pattern of facial wrinkling, including forehead wrinkling, is likely dependent on the morphology of the skull and muscles which directly influence face expression that causes skin buckling [9].

As foreheads proved to be diverse in the shape, number, distribution of their wrinkles, it can be said that forehead wrinkling patterns would potentially be unique for every individual. Even if a number of individuals are having the same type and same number of forehead wrinkles, they could be differentiated from each other and look different. Further research work is required on this regard.

Morphology of vertical wrinkles: On examination of the forehead images of the group of individuals for the characters of forehead vertical wrinkles that they have, it was possible to divide the foreheads into four types regarding the shape of vertical wrinkles in the glabellar area between the eye brows. The first type is the standard one, which contains two vertical lines. This type is the commonest and represents the majority of the vertical wrinkles (represents 91%). The second and third types are very rare and contain either one or three vertical lines, (represent 1% and 2%), respectively. The fourth type is rare in which the glabellar area contains irregular shaped wrinkle, represents 6%. Vertical wrinkles are moderately variable. They do not occur in all individuals even at 60 or 70-years-old as there were some individuals who do not have any vertical wrinkles in the resting state. Vertical wrinkles do not contain much detail and start to appear at later ages than the horizontal ones.

Age of the appearance of forehead wrinkles

Horizontal wrinkles: On examination of the forehead pictures of all age groups regarding the persistent horizontal wrinkles, foreheads could be classified into 8 age groups as follow: 10, 20, 30, 40, 50, 60, 70 and over 70-years-old groups. On examination of the foreheads of these age groups, the following ratios were obtained:

1. At age of 10 years, foreheads of the individuals of this age group did not show any wrinkling pattern.
2. At age of 20 years, only 12% of the individuals of this age group have shown presence of horizontal forehead wrinkles.
3. At age of 30 years, 36% of the individuals of this age group have shown presence of horizontal forehead wrinkles.
4. At age of 40 years, 74% of the individuals of this age group have shown presence of horizontal forehead wrinkles.
5. At age of 50 years, 97% of the individuals of this age group have shown presence of horizontal forehead wrinkles.
6. At age of 60 years, 99% of the individuals of this age group have shown presence of horizontal forehead wrinkles.
7. At age of 70 years, almost all individuals of this age group have shown presence forehead wrinkles.
8. At ages over 70-years, all individuals carried horizontal forehead wrinkles which are more wide and deep and very evident.

It is probable that these ratios might be changed on examination of larger numbers of individuals.

From Figure 3, it is easy to observe that at age of 20 years, some individuals have shown the presence of forehead horizontal wrinkles (12%). However, this result contradicts another study which indicated that in youth (ages 10-19), facial wrinkles including forehead ones (both temporary and persistent are largely absent [26]. In our study the horizontal forehead wrinkles appeared at earlier ages than that of Miyamoto study. Probably because our study have been done on people from Egypt who are affected by different genetic and environmental factors such as sun. Egypt is nearly sunny all the year, and it is known that sun affects the elasticity of tissues and results in the appearance of forehead wrinkles at earlier ages. It was indicated that the loss of skin mechanical properties starts very early in life and this loss is significantly faster on sun-exposed vs. sun-protected skin sites [36]. It is clear that forehead horizontal wrinkles start to appear around the age of 20 and increases gradually until at the age of 50 years 97% of men would have this type of wrinkles on their forehead and at the age of 60, 99% of men have wrinkles and at the age of 70 years, all men would have this kind of wrinkles on their forehead.

It is probable that these ratios might be are changed on examination of foreheads of larger numbers of individuals.

Vertical wrinkles (frown lines): On examination of the forehead pictures of all ages, regarding the vertical wrinkles, foreheads could be classified into 7 age groups as follow: 10-20, 30, 40, 50, 60, 70 and over 70-years-old groups. On examination of the foreheads of these age groups, the following ratios were obtained.

1. At age of 10-20 years, foreheads of the individuals of this age group showed absence of any vertical wrinkles.
2. At age of 30 years, foreheads of only 5% of the individuals of this age group carried vertical forehead wrinkles.
3. At age of 40 years, foreheads of 29% of the individuals of this age group carried vertical forehead wrinkles.
4. At age of 50 years, foreheads of 56% of the individuals of this age group carried vertical forehead wrinkles.
5. At age of 60 years, foreheads of 77% of the individuals of this age group carried vertical forehead wrinkles.
6. At age of 70 years, foreheads of 86% of the individuals of this age group carried vertical forehead wrinkles.
7. At ages over 70 years, 93% of the individuals of this age group carried vertical forehead wrinkles.

It is clear from tables 4 and 5 that people vary widely regarding the age of appearance of each of horizontal and vertical forehead wrinkles. The majority of horizontal forehead wrinkles appear at ages between 30 – 50 years while the Majority of vertical forehead wrinkles appear at ages between 40-70 years. In a study on rate of wrinkling in women, it was found that the subjects in their forties showed a significant faster rate of wrinkling than in other age groups [37].

This agrees with the studies which indicated that the age of onset and rate of persistent facial wrinkling, including the forehead wrinkles, is dependent on both the cumulative amount of mechanical stress (frequency of temporary wrinkling) in combination with the decline in skin elasticity caused by, for example, cumulative sun exposure [9]. Geng et al, 2007 indicated that Different people age in different ways. The aging pattern of each

person is determined by his/her genes as well as many external factors, such as health, lifestyle and weather conditions [38].

Persistence of forehead wrinkling pattern

To study the persistence of forehead wrinkling pattern, forehead pictures were taken from 25 individuals twice with a 10-years interval in between (at ages of 40 and 50 years old). Despite this period would not be long enough to study this character, it was clear that the appearance of the forehead wrinkling pattern does not disappear or fade with time in morphology (whether in shape, direction or position). The only difference noticed is the size of the wrinkles, represented by depth and width, which showed some increase. This would probably be more noticeable when the forehead wrinkling patterns are studied on longer intervals than 10 years such as 20 and 30 years even longer. Thus I would say that the present study establishes that the forehead wrinkling pattern is somehow stable and since formed does not change in shape, probably throughout the lifetime (unless interfered by cosmetic means). As the wrinkling pattern starts to appear with age, it remains in its place and does not change by time. It is generally assumed that the age-related deterioration in the elastic properties of the skin is directly or indirectly responsible for the formation of skin wrinkles [39]. This longitudinal part of our study is done on the persistence of forehead wrinkles. It has showed the persistence and stability of the wrinkling pattern, this agrees completely with another study that was done on the persistence of facial wrinkles (including forehead ones) with eight years interval. The study discovered that the images taken for the same individual with eight years interval are consistently similar [40].

Forehead pattern morphology during different expressions

To study the forehead pattern morphology during different expressions, forehead images were collected from 25 individuals, who are having persistent resting wrinkles, during different expressions, to see how the wrinkling pattern looks like during different expressions (rest, surprise and both surprise & frowning) and to find out which the condition that would have the maximal effect on the appearance and prominence of the forehead wrinkling pattern. From the examined images, it was clear that the contraction of occipitofrontalis muscles, which occurs during surprise, is the main factor that is responsible for the formation of the horizontal forehead wrinkling pattern.

N.B. Throughout our study, all forehead images were taken during the neutral or relaxed state. This section is the only part of the study in which images were taken for individuals during rest (neutral state) and during other facial expressions such as surprise and mixed surprise & frowning.

N.B. Most of the clinical work, which was done on facial wrinkling, studied the wrinkles during the neutral state. However, we here have chosen to study the wrinkling during rest and surprise, mixture of surprise and frowning. It has recently been reported that despite the importance of facial expression in the etiology of facial wrinkling, most of the facial wrinkling clinical research over the past 40 or more years has employed methods or protocols that measure facial wrinkling only in a relaxed or neutral state [9]. Only a few studies studied wrinkling during both the neutral and smiling expressions for the examination of crow's feet wrinkles around the eyes, not the forehead ones [41].

Morphology of the foreheads which don't have wrinkling pattern

Foreheads of the young individuals (such as teens), which showed absence of any wrinkling pattern during rest, have been studied to find out what other features that can be used for identification. Despite the foreheads of young individuals were identified by the absence of wrinkles, they could also be identified by the accidental presence of forehead acne lesions (black, white comedones, acne papules and pustules). Presence of these lesions reflects the approximate age group of the individual (teenage and the early twenties). In the older individuals, there would be other features such as old scars, warts, psoriatic lesions and naevi [42].

Foreheads with bizarre wrinkling patterns

During examination of the forehead images, there were a number of foreheads with bizarre appearance. They have either irregular horizontal wrinkles or wrinkles of different combinations of wrinkling lines such as crossing wrinkles making rectangular or deltoid or other shapes. Some are horizontal type but with irregular borders. These bizarre wrinkles are very rare and less than 1% of the whole forehead images and would be useful in identification of the bizarre shaped forehead.

Conclusion

1. Foreheads would probably be unique as they differ from one to another in the absence or presence and/or the shape and size of the wrinkling pattern that they bear. It is reported that no two person's facial wrinkling pattern are alike. Each individual has his/her own unique pattern of wrinkling which can hypothetically named "wrinkleprint", as unique as is their own fingerprints. This unique pattern of wrinkling is dependent not only on the person's skin but also on the persons' age, unique skull and muscle morphology [9]. It has been reported that it is impossible to find two identical people as regard the facial aging patterns, even twins have some differences [43, 44].
2. Forehead Horizontal wrinkling can be classified according to the length of wrinkles related to the size of the forehead into three main types:
 - A. Long horizontal wrinkles: the forehead bears one or more of horizontal wrinkles which occupy more than half breadth of the forehead.
 - B. Short horizontal wrinkling: the forehead bears one or more of the horizontal wrinkles which occupy half or less than half breadth of the forehead.
 - C. Mixed or Composite wrinkles: the forehead bears both long and short horizontal wrinkles.
3. Forehead horizontal wrinkling pattern according to the number of horizontal wrinkles the forehead bears, can be divided into 5 subtypes (see table 2). The majority of the individuals in our study have carried two to three horizontal wrinkles on their foreheads (36% and 31%, respectively).
4. Forehead wrinkles start to appear in most individuals at ages 20 to 30 years age. There are exceptions for this as they sometimes appear slightly before or after these ages.
5. Forehead wrinkles start superficial and get deeper with age.
6. Forehead wrinkles morphology is persistent and stable with age, although it may probably be altered (by surgery, filler, botulinum toxin or other cosmetic procedures or when they are tampered with).

Suggested future studies

1. Persistence of forehead patterns has to be studied with longer time intervals such as 10, 20 and 30 years.
2. Forehead patterns need to be examined and compared in both sexes to see the difference of the forehead wrinkling patterns in both sexes.
3. Forehead patterns are to be examined among different races to see if there is any racial differentiation. The rate of skin aging varies between different racial groups, however. Generally, Caucasians present an earlier onset and a deeper skin wrinkling and sagging than other skin phototypes [45, 46].
4. Studies should be done on forehead prints and in these studies the prints should be examined for the potential validity of forehead wrinkling patterns in the individual identification and consequently in the forensic work.
5. Forehead wrinkling patterns need to be studied among families to see if there are any genetic similarities among relatives.
6. Foreheads with no wrinkles need to be examined for any peculiarity that can help in identification.

Acknowledgement

The author is grateful to all the subjects who volunteered to give their forehead images for this study.

References

- [1]. Alan L McRoberts (1996) Nature never repeats itself. "THE PRINT" 12(5): 1-3.
- [2]. APA Ton Broeders (2003) Forensic Evidence and International Courts and Tribunals: Why bother, given the present state of play in forensics? ISRCL The Hague:1-10.<http://www.isrcl.org/Papers/Broeders.pdf>.
- [3]. John R Vanderkolk (2010) <http://www.clpex.com/Articles/TheDetail/1-99/TheDetail18.htm>.
- [4]. Kasprzak J (2001) Identification of ear impressions in polish forensic practice. Problems of Forensic Sciences 57: 168-174.
- [5]. Shendarkar AT, Kharat R, Vaz WF, Karjodkar FR, Rede KR (2010) Estimation of Age in the Living Municipal Employees in the Age Group of 25-45 Years by Physical and Radiological Examination. J Indian Acad Forensic Med 32(2): 113-119.
- [6]. Amanda O (2011) Facial lines and wrinkles. The New Zealand Dermatological Society Incorporated. DermNet. NZ. <http://dermnetnz.org/site-age-specific/wrinkles.html>.
- [7]. Eric FB (2010) Forehead wrinkles. <http://www.collagen.org/forehead.aspx/>
- [8]. AbuBaker A, Mehdi A (2012) Estimating the Position, Number and Length of Forehead Wrinkles Using Neural Network. Research Journal of Applied Sciences, Engineering and Technology 4(15): 2584-2589.
- [9]. Farage M, Miller K, Maibach H (2010) Textbook of aging skin. Springer-Verlag Berlin Heidelberg, Germany.
- [10]. Bhupendra P, Simon T, Roshmi G (2011) Forehead Anatomy. <http://emedicine.medscape.com/article/834862-overview>.
- [11]. Knize DM (2001) The Forehead and Temporal Fossa: Anatomy and Technique. Lippincott Williams & Wilkins, UK. 4.
- [12]. Marieb EN, Hoehn K (2007) Human anatomy & physiology. (7th edtn), Pearson Education, New York. 204.
- [13]. Thomas VD, Mitchell WL, Swanson NA, Rohrer TE, Lee KK (2007) Reconstructive surgery of Skin Cancer defects. In Keyvan Nouri. Skin Cancer. McGraw-Hill Professional. 523.
- [14]. Palastanga N, Derek Field, Roger Soames (2006) "Head and Brain". Anatomy and human movement. (5th edtn), Elsevier Health Sciences. 645-646.
- [15]. Paul Ekman, Wallace V. Friesen, Joseph C. Hager (2002) Facial action coding system. Salt Lake City, Research Nexus, UT.
- [16]. Hager JC (2003) <http://face-and-emotion.com/dataface/general/homepage.jsp>.
- [17]. Cua AB, Wilhelm KP, Maibach HI (1995) Skin surface lipid and skin friction: relation to age, sex and anatomical region. Skin Pharmacol 8(5): 246-251.

- [18]. Hillebrand GG, Levine M, Miyamoto K (2007) The age-dependent changes in skin condition in ethnic populations from around the world. In Ethnic Hair and Skin. (1st edtn), Informa Healthcare, New York. 105-122.
- [19]. Hatzis J (2004) The wrinkle and its measurement – a skin surface Profilometric method. Micron 35(3): 201-219.
- [20]. Anderson L (2006) Looking Good: The Australian guide to skin care, cosmetic medicine and cosmetic surgery. Australasian Medical Publishing Company. Sydney.
- [21]. Bernstein EF (1986) University of Pennsylvania School of Medicine. <http://www.collagen.org/forehead.aspx>.
- [22]. Fisher GJ, Wang ZQ, Datta SC, Varani J, Kang S, et al. (1997) Pathophysiology of premature skin aging induced by ultraviolet light. N Engl J Med 337(20): 1419-1428.
- [23]. Heather Brannon (2006) Glogau Classification of Photoaging, Classifying the Severity of Wrinkles.
- [24]. Kligman AM, Zheng P, Lavker RM (1985) The anatomy and pathogenesis of wrinkles. Br J Dermatol 113(1): 37-42.
- [25]. Nelson Lee Novick (2011) Wrinkles (rhytides). Younger Looking Without Surgery. <http://fromyourdoctor.com/skinsavvy/health/topic.do?title=Wrinkles+Rhytides&t=7302>.
- [26]. Hager JC (1983) Asymmetries in Facial Actions. Phd thesis in psychology. The University of California.
- [27]. Hantash BM, Bedi VP, Sudreddy V, Struck SK, Herron GS, et al. (2006) Laser-induced transepidermal elimination of dermal content by fractional photothermolysis. J Biomed Opt 11(4): 041115.
- [28]. Kligman A, Grove J, Hirose R, Leyden JJ (1986) Topical tretinoin for photoaged skin. J Am Acad Dermatol 15(4 Pt 2): 836-859.
- [29]. Stefanaki C, Stratigos A, Katsambas A (2005) Topical retinoids in the treatment of photoaging. J Cosmet Dermatol 4(2): 130-134.
- [30]. Lowe NJ, Maxwell CA, Lowe P, Duick MG, Shah K (2001) Hyaluronic acid skin fillers: Adverse reactions and skin testing. J Am Acad Dermatol 45(6): 930-933.
- [31]. Ghersetich I, Lotti T, Campanile G, Grappone C, Dini G (1994) Hyaluronic acid in cutaneous intrinsic aging. Int J Dermatol 33(2): 119-122.
- [32]. Brin F, Lew F, Adler H, Comella L, Factor A, et al. (1999) Safety and efficacy of NeuroBloc (botulinum toxin type B) in type A-resistant cervical dystonia. Neurology 53(7): 1431-1438.
- [33]. Fagien S (1999) Botox for the treatment of dynamic and hyperkinetic, facial lines and furrows: adjunctive use in facial aesthetic surgery. Plant Reconstr Surg 103(2): 710-713.
- [34]. Ancona D, Katz BE (2010) A prospective study of the improvement in peri-orbital wrinkles and eyebrow elevation with a novel fractional CO2 laser-the fractional eyelift. J Drugs Dermatol 9(1): 16-21.
- [35]. Hurwitz DJ, Schweiger ES (2007) Tips for teaching cosmetic dermatology to residents. Cosmetic Dermatology 20(5): 276-277.
- [36]. Miyamoto K, Hillebrand GG (2007) The influence of facial expression on the age-dependent changes in facial wrinkling. J Soc Cos Sci 58: 206-207.
- [37]. Jemec GB, Selvaag E, Agren M, Wulf HC (2001) Measurement of the mechanical properties of skin with ballistometer and suction cup. Skin Res Technol 7(2): 122-126.
- [38]. Geng X, Zhou ZH, Smith-Miles K (2007) Automatic age estimation based on facial aging patterns. Pattern Analysis and Machine Intelligence, IEEE Transactions on 29(12): 2234-2240.
- [39]. Hillebrand G, Yoshii T, Yan X (2009) Progression of temporary into persistent facial wrinkling: An 8-year longitudinal study. J Am Acad Dermatol 60(3 Suppl 1): AB1.
- [40]. Akazaki S, Nakagawa H, Kazama H, Osanai O, Kawai M, et al. (2002) Age-related changes in skin wrinkles assessed by a novel three-dimensional morphometric analysis. Br J Dermatol 147(4): 689-695.
- [41]. Miyamoto K, Hillebrand GG (2002) The Beauty Imaging System: for the objective evaluation of skin condition. J Cosmet Sci 53: 62-65.
- [42]. Hillebrand GG, Levine MJ, Miyamoto K (2001) The age-dependent changes in skin condition in African Americans, Caucasians, East Asians, Indian Asians and Latinos. IFSCC Mag 4: 259-266.
- [43]. Kalamani D, Balasubramanie P (2006) Age Classification using Fuzzy Lattice Neural Network. Proceedings of the sixth international Conference on Intelligent Systems Design and Applications, China. 225-230.
- [44]. Rose LC (1998) Recognizing Neoplastic Skin Lesions: a photo guide. Am Fam Physician 58(4): 873-884.
- [45]. Seiberg M, Paine C, Sharlow E, Andrade-Gordon P, Costanzo M, et al. (2000) The protease-activated receptor 2 regulated pigmentation via keratinocytes-melanocyte interactions. Exp Cell Res 254(1): 25-32.
- [46]. Zhao W, Chellappa R, Phillips PJ, Rosenfeld A (2003) Face recognition: A literature survey. ACM Computing Surveys 35(4): 399-458.