

## Number of Calcified Maxillary Anteriors Undergoing Root Canal Treatment Under 50 Years of Age - an Institutional Study

Research Article

Jitesh S<sup>1</sup>, Adimulapu Hima Sandeep<sup>2\*</sup>, Madhulaxmi M<sup>3</sup><sup>1</sup> Saveetha Dental College and Hospital, Saveetha Institute of Medical and Technical Sciences, Saveetha University, Chennai 600077, Tamil Nadu, India.<sup>2</sup> Senior Lecturer, Department Of Conservative dentistry and Endodontics, Saveetha Dental College and Hospital, Saveetha Institute of Medical and Technical Sciences, Saveetha University, Chennai 600077, Tamil Nadu, India.<sup>3</sup> Professor, Department of Oral and Maxillofacial Surgery, Saveetha Dental College and Hospital, Saveetha Institute of Medical and Technical Sciences, Saveetha University, Chennai 600077, Tamil Nadu, India.

### Abstract

The main objective of this study is to find out the prevalence of calcified maxillary anteriors undergoing root canal treatment under 50 years of age group visiting Saveetha dental college and hospitals. This is an institutional based retrospective study conducted among 208 patients reported for root canal treatment of maxillary anteriors and the diagnosis of calcification was based on radiographic evidence. Patients reported to the OP other than maxillary anterior root canal treatment and medically compromised were excluded. From this current study, it was found that, out of 208 patients, 37 were reported with calcification and the prevalence rate was found to be 17%. The extent of calcification was evaluated in which 62% were completely calcified, 20 % of the teeth exhibited calcification till apical third and 18% was till middle third. Within the limits of the present study, prevalence of calcification in maxillary anteriors was found to be 17% under 50 years of age group. Comparing the extent of calcification, teeth with complete calcification (62%) was found to be the most prevalent when compared to calcification extending till apical and middle third and there was no significant association between gender and canal calcification.

**Keywords:** Calcific Metamorphosis; Maxillary Anteriors; Pulp Calcification.

### Introduction

Dental trauma is a common etiological factor to the primary and permanent dentition leading to several complications and management challenges for a dentist. Most common complications include the surface inflammation, internal resorption, pulpal necrosis, invasive cervical resorption and calcific metamorphosis [1, 2]. Calcific metamorphosis (CM) is defined as the pulpal response against the trauma resulting in rapid deposition of the hard tissues within the root canal space [3, 4]. Calcific metamorphosis complicates the access of the root canal system for dentists to do a successful root-canal treatment.

Calcific metamorphosis is one of the most common responses towards dental trauma. However, the degrees of response depend upon the severity of the trauma to the neurovascular tissues in the apical foramen [5, 6]. Treating canal calcification is a most taunt-

ing process for the endodontist [7, 8]. Calcific metamorphosis is very common in the anterior teeth and it is possible to identify it three months after an incidence of the injury and sometimes it might also occur even after a year. Even the vital pulp testing may give a negative response irrespective of the pulpal vitality, due to the increased dental thickness [9, 10]. Calcific metamorphosis occurs commonly following traumatic injuries like luxation, subluxation and concussion which leads to complete/partial obliteration of the root canal depending upon the severity of the injury or development stage of the tooth [11, 12]. It is mostly asymptomatic and most of the time is identified based on yellow discoloration of the affected crown tooth and is due to the thickness of dentin deposition. It is important to consider color change takes place uniformly across [9, 13]. The osteoid lesion with cellular inclusions adjacent to mineralised areas in the pulp could have been observed due to either an initial calcification of isolated pulp tissues/epithelial mesenchymal extractions [14, 16]. Lundberg and

#### \*Corresponding Author:

Dr. Adimulapu Hima Sandeep,

Senior Lecturer, Department Of Conservative dentistry and Endodontics, Saveetha Dental College and Hospital, Saveetha Institute of Medical and Technical Sciences, Saveetha University, Chennai 600077, Tamil Nadu, India.

Tel: +91 90031 75288

E-mail: himas.sdc@saveetha.com

**Received:** July 30, 2021**Accepted:** August 11, 2021**Published:** August 18, 2021

**Citation:** Jitesh S, Adimulapu Hima Sandeep, Madhulaxmi M. Number of Calcified Maxillary Anteriors Undergoing Root Canal Treatment Under 50 Years of Age - an Institutional Study. *Int J Dentistry Oral Sci.* 2021;8(8):3981-3984. doi: <http://dx.doi.org/10.19070/2377-8075-21000813>

**Copyright:** Dr. Adimulapu Hima Sandeep ©2021. This is an open-access article distributed under the terms of the Creative Commons Attribution License, which permits unrestricted use, distribution and reproduction in any medium, provided the original author and source are credited.

Wek et al., showed that content of collagen increases in maxillary inclusion after trauma with decreased cell number [17-19]. Sihendh et al suggested root end resilient to be considered when a canal cannot be isolated. Previously our team has a rich experience in working on various research projects across multiple disciplines [20-34]. Now the growing trend in this area motivated us to pursue this project.

The purpose of this study was to describe the prevalence of canal calcification in the given sample and to report the extent of calcification of the same.

**Materials and Methods**

**Study design and Study setting:**

The present hospital based retrospective study was carried out with the use of a digital case record of 208 patients who underwent root canal treatment from lakhs of patients attending the dental college from june 2019 to march 2020.

Ethical clearance to conduct this study was obtained from the Scientific Review Board of the hospital (SDC/SIHEC/2020/DI-

ASDATA/0619-0320) . An inclusion criterion was patients visiting the dental college in the specified period of time and patients undergoing RCT of maxillary anteriors. All the 208 patients who underwent RCT of maxillary anteriors were included in this study and cross verification of the data was done for errors. Each case was verified regarding general information of the patient; if anterior RCT was done then radiographic investigation was performed to assess the canal status. The exclusion criteria were missing or incomplete data. Exclusion criteria eliminated cases that were not approved by the concerned faculty in the hospital. Demographic details of cases went for RCTs and Radiographs were retrieved. Data was verified by one eternal examiner. Data was tabulated in Excel and imported to SPSS and variables were determined.

**Results & Discussion**

IBM SPSS version 20.0 was used for statistical analysis and descriptive analysis was used to describe age, gender and extent of calcification. Dependent variables were root canal treated teeth and independent variables were age, calcified root canal system.

The gender distribution of the population who underwent for RCT for maxillary anteriors are males(66%) and females(34%) (figure 1and table 1) and from this current study, it was found

Figure 1. Bar chart depicting the gender distribution of the present study. X axis represents the gender and Y axis represents the percentage of the study population. Sample size n=208; 138 males (66%) and 70 females (34%).




Figure 2. Bar chart depicts the presence of calcification. X axis represents the status of the canal and Y axis represents the percentage of the study population. Out of 208 patients: 37 calcified canal (17.8%) and 171 normal canal morphology(82.2%).




Figure 3 - Pie chart shows the extent of calcification. In which completely calcified canal (green) 62%, calcification extending till the middle third(blue) 18% and the calcification extending only till the apical third(red) 20% of the cases.

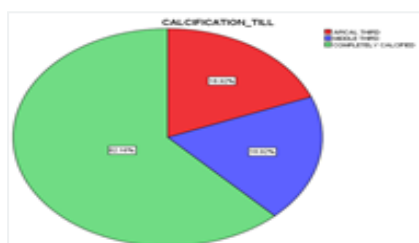
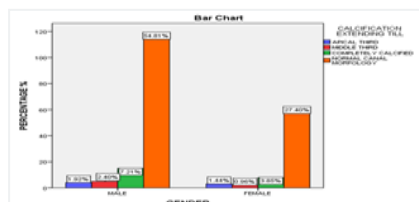


Figure 4 - Bar graph depicting the association between the canal morphology among males and females. X axis represents the gender and Y axis represents the total count of the subjects. Association tested by Pearson Chi-Square is more likely to - .368, p value - 0.947(>0.05) ; statistically not significant though complete calcification of the pearson (green) is more likely to occur in males than females.



**Table 1. Depicts the gender distribution of the present study. Gender distribution of the population out of 208; 138 males(66%) and 70 females(34%).**

		Frequency	Percent	Valid Percent	Cumulative Percent
Valid	MALE	138	66.3	66.3	66.3
	FEMALE	70	33.7	33.7	100
	Total	208	100	100	

**Table 2. Depicts the prevalence of the calcified canal of the present study. Out of 208 patients ; 37 calcified canal (17.8%) and 171 normal canal morphology(82.2%).**

		Frequency	Percent	Valid Percent	Cumulative Percent
Valid	PRESENT	37	17.8	17.8	17.8
	ABSENT	171	82.2	82.2	100
	Total	208	100	100	

to be that out of 208 patients, 37 patients had canal calcification and the prevalence was about 17% (figure 2 and table 2). The extent of Canal calcification was 62% were completely calcified, 20 % were till apical third, 18% were till middle third.(figure 3) and there was no significant association between gender and the canal morphology.(Pearson Chi-Square test - .368, p value was more than 0.05 ; statistically not significant)(figure 4).

In our present study, the prevalence of canal calcification of maxillary anterior was found to be 17.8% which is supported by the study done by Patterson and Micheal (1) where the incidence of Calcified canal ranges from 4% to 24%. In Calcified canal cases, typically the anterior teeth show a high dentin deposition rate of 3.5 µm /day as compared to the average normal rate of 2.8µm/day for deciduous teeth and 1.5% µm/day for permanent teeth (35,36).The lamina dura remains intact without peripheral lesions and there is no widening of the PDL space. Radiographic diagnosis of Calcified canal requires a complete/partial obliteration of the pulp chamber and canal. A complete obliteration does not require a complete absence of pulp chamber and canal space.

In contrast, a partial obliteration is when pulp chambers are not visible and the canal is markedly narrowed but still visible. For deciding root canal treatment, dentists must show sound knowledge towards canal anatomy and also possible variations. This greatly helps them prepare a better access to the cavity prior to planning the rubber dam. The access cavity was kept normal size and shape. It is recommended to use inductors like sodium hypochlorite for visualising location of the canal [37-39]. Usage of operating microscope required to localise the calcified canal [40, 41].

In our present study, the extent of calcification was found to be 62% completely calcified, 20% till the apical third, 18% was extending from apical to the middle third. Even though negotiating and managing the calcified canals is challenging, it can be accessed if a proper protocol is followed. Access preparation is initiated with the rotary instrument directed towards the presumed location of the pulp chamber. Accurate radiographs are needed for preoperative assessment and periodic assessment of the bur penetration and orientation. Penetration proceeded with DG-16 endodontic explorer. In case of deep excavation long shank round no.2 bur can be used.then the orifice can be enlarged using No. 8 or 10 K- files. Calcified canal management includes use of

vital(external) bleaching with hydrogen peroxide to be considered as the first option [42, 43]. Operator's skill, patience, and a proper armamentarium are the requisites to overcome the difficulties posed by these unforgiving canals for their successful treatment. Our institution is passionate about high quality evidence based research and has excelled in various fields[44 -54]. We hope this study adds to this rich legacy.

The limitations of the study included geographic isolation, subjective error/bias, sample size, multi unleashed , larger sample size to be extensively done in this field of interest.

**Conclusion**

Within the limits of the present study, prevalence of calcification in maxillary anteriors was found to be 17% under 50 years of age group. Comparing the extent of calcification, teeth with complete calcification (62%) was found to be the most prevalent when compared to calcification extending till apical and middle third. This study shows that complete calcification of the canal was more in males than females. Further investigation can be done on the etiological factors of calcification dividing the age groups. Operator's skill, patience, and a proper armamentarium are the requisites to overcome the difficulties posed by these unforgiving canals for their successful treatment.

**References**

- [1]. Malhotra N, Mala K. Calcific metamorphosis. Literature review and clinical strategies. Dent Update. 2013 Jan-Feb;40(1):48-50.Pubmed PMID: 23505858.
- [2]. PradeepKumar AR, Shemesh H, Jothilatha S, Vijayabharathi R, Jayalakshmi S, Kishen A. Diagnosis of Vertical Root Fractures in Restored Endodontically Treated Teeth: A Time-dependent Retrospective Cohort Study. J Endod. 2016 Aug;42(8):1175-80.Pubmed PMID: 27339633.
- [3]. AlDajji MT, Alsahaly L. Aesthetic management of complete calcific metamorphosis: a case report. Int J Res Med Sci. 2018 Nov;6(11):3782.
- [4]. Ramamoorthi S, Nivedhitha MS, Divyanand MJ. Comparative evaluation of postoperative pain after using endodontic needle and EndoActivator during root canal irrigation: A randomised controlled trial. Aust Endod J. 2015 Aug;41(2):78-87.Pubmed PMID: 25195661.
- [5]. Kuster CG. Calcific metamorphosis/internal resorption: a case report. Pediatr Dent. 1981 Sep;3(3):274-5.Pubmed PMID: 6951155.
- [6]. Ramanathan S, Solete P. Cone-beam Computed Tomography Evaluation of Root Canal Preparation using Various Rotary Instruments: An in vitro Study. J Contemp Dent Pract. 2015 Nov 1;16(11):869-72.
- [7]. Koli P, Pujar M, Yalgi V, Uppin V, Vagarali H, Hosmani N. Ultrasonic man-

- agement of calcified canal: a case report. *Oral Surg Oral Med Oral Radiol.* 2014;2(2):11-3.
- [8]. Siddique R, Sureshbabu NM, Somasundaram J, Jacob B, Selvam D. Qualitative and quantitative analysis of precipitate formation following interaction of chlorhexidine with sodium hypochlorite, neem, and tulsi. *J Conserv Dent.* 2019 Jan-Feb;22(1):40-47. Pubmed PMID: 30820081.
- [9]. Lise DP, Gutiérrez C, da Rosa TP, Vieira LC. Bleaching options for pulp-calcified teeth: case history reports. *Oper Dent.* 2014 Nov-Dec;39(6):572-7. Pubmed PMID: 25084109.
- [10]. Rajakeerthi R, Nivedhitha MS. Natural Product as the Storage medium for an avulsed tooth—A Systematic Review. *Cumhuriyet Dent J.* 2019 Jun 11;22(2):249-56.
- [11]. Teixeira FB. *Endodontics: Principles and Practice.* J. Endod. 2009 Jul 1;35(7):474.
- [12]. Rajendran R, Kunjusankaran RN, Sandhya R, Anilkumar A, Santhosh R, Patil SR. Comparative evaluation of remineralizing potential of a paste containing bioactive glass and a topical cream containing casein phosphopeptide-amorphous calcium phosphate: An in vitro study. *Pesqui Bras Odontopediatria Clin Integr.* 2019 Oct 10;19:4668.
- [13]. Hussainy SN, Nasim I, Thomas T, Ranjan M. Clinical performance of resin-modified glass ionomer cement, flowable composite, and polyacid-modified resin composite in noncarious cervical lesions: One-year follow-up. *J Conserv Dent.* 2018 Sep-Oct;21(5):510-515. Pubmed PMID: 30294112.
- [14]. Amir FA, Gudmann JL, E Witherspoon DE. Calcific metamorphosis: a challenge in endodontic diagnosis and treatment. *Quintessence Int.* 2001 Jun 1;32(6):447-55.
- [15]. Janani K, Palanivelu A, Sandhya R. Diagnostic accuracy of dental pulse oximeter with customized sensor holder, thermal test and electric pulp test for the evaluation of pulp vitality: an in vivo study. *Braz. Dent. Sci.* 2020 Jan 31;23(1):8.
- [16]. Janani K, Ajitha P, Sandhya R. Improved quality of life in patients with dentin hypersensitivity. *Saudi Endod. J.* 2020 Jan 1;10(1):81.
- [17]. Lundberg M, Cvek M. A light microscopy study of pulps from traumatized permanent incisors with reduced pulpal lumen. *Acta Odontol Scand.* 1980;38(2):89-94. Pubmed PMID: 6929646.
- [18]. Jose J, Subbaiyan H. Different treatment modalities followed by dental practitioners for Ellis class 2 fracture—A questionnaire-based survey. *Open Dent. J.* 2020 Feb 18;14(1):59-65.
- [19]. Nallaswamy D, Solete P, Subha M. Comparative study on conventional lecture classes versus flipped class in teaching conservative dentistry and endodontics. *Int. J. Pharm. Sci. Res.* 2019;10(1):689-93.
- [20]. Jain AR. Prevalence of partial edentulousness and treatment needs in rural population of South India. *World J Dent.* 2017 Jun;8(3):213-7.
- [21]. Varghese SS, Ramesh A, Veeraiyan DN. Blended Module-Based Teaching in Biostatistics and Research Methodology: A Retrospective Study with Postgraduate Dental Students. *J Dent Educ.* 2019 Apr;83(4):445-450. Pubmed PMID: 30745352.
- [22]. Ashok V, Ganapathy D. A geometrical method to classify face forms. *J Oral Biol Craniofac Res.* 2019 Jul 1;9(3):232-5.
- [23]. Padavala S, Sukumaran G. Molar incisor hypomineralization and its prevalence. *Contemp Clin Dent.* 2018 Sep;9(Suppl 2):S246-50.
- [24]. Ke Y, Al Aboody MS, Alturaiki W, Alsagaby SA, Alfaiz FA, Veeraraghavan VP, et al. Photosynthesized gold nanoparticles from *Catharanthus roseus* induces caspase-mediated apoptosis in cervical cancer cells (HeLa). *Artif Cells Nanomed Biotechnol.* 2019 Dec;47(1):1938-1946. Pubmed PMID: 31099261.
- [25]. Ezhilarasan D. Oxidative stress is bane in chronic liver diseases: Clinical and experimental perspective. *Arab J Gastroenterol.* 2018 Jun;19(2):56-64. Pubmed PMID: 29853428.
- [26]. Krishnan RP, Ramani P, Sherlin HJ, Sukumaran G, Ramasubramanian A, Jayaraj G, et al. Surgical Specimen Handover from Operation Theater to Laboratory: A Survey. *Ann Maxillofac Surg.* 2018 Jul-Dec;8(2):234-238. Pubmed PMID: 30693238.
- [27]. Ezhilarasan D, Sokal E, Najimi M. Hepatic fibrosis: It is time to go with hepatic stellate cell-specific therapeutic targets. *Hepatobiliary Pancreat Dis Int.* 2018 Jun;17(3):192-197. Pubmed PMID: 29709350.
- [28]. Pandian KS, Krishnan S, Kumar SA. Angular photogrammetric analysis of the soft-tissue facial profile of Indian adults. *Indian J Dent Res.* 2018 Mar 1;29(2):137-43.
- [29]. Ramamurthy JA, Mg V. Comparison of effect of Hiora mouthwash versus Chlorhexidine mouthwash in gingivitis patients: A clinical trial. *Asian J Pharm Clin Res.* 2018 Jul 7;11(7):84-8.
- [30]. Gupta P, Ariga P, Deogade SC. Effect of Monopoly-coating Agent on the Surface Roughness of a Tissue Conditioner Subjected to Cleansing and Disinfection: A Contact Profilometric In vitro Study. *Contemp Clin Dent.* 2018 Jun;9(Suppl 1):S122-S126. Pubmed PMID: 29962776.
- [31]. Vikram NR, Prabhakar R, Kumar SA, Karthikeyan MK, Saravanan R. Ball Headed Mini Implant. *J Clin Diagn Res.* 2017 Jan;11(1):ZL02-3.
- [32]. Paramasivam A, Vijayashree Priyadharsini J, Raghunandhakumar S. N6-adenosine methylation (m6A): a promising new molecular target in hypertension and cardiovascular diseases. *Hypertens Res.* 2020 Feb;43(2):153-154. Pubmed PMID: 31578458.
- [33]. Palati S, Ramani P, Shrelin HJ, Sukumaran G, Ramasubramanian A, Don KR, et al. Knowledge, Attitude and practice survey on the perspective of oral lesions and dental health in geriatric patients residing in old age homes. *Indian J Dent Res.* 2020 Jan-Feb;31(1):22-25. Pubmed PMID: 32246676.
- [34]. Samuel SR, Acharya S, Rao JC. School Interventions-based Prevention of Early-Childhood Caries among 3-5-year-old children from very low socio-economic status: Two-year randomized trial. *J Public Health Dent.* 2020 Jan;80(1):51-60. Pubmed PMID: 31710096.
- [35]. Goga R, Chandler NP, Oginni AO. Pulp stones: a review. *Int. Endod. J.* 2008 Jun;41(6):457-68.
- [36]. Kumar D, Antony S. Calcified canal and negotiation—A review. *Res J Pharm Technol.* 2018;11(8):3727-30.
- [37]. Bab I, Lustmann J, Azaz B, Gazit D, Garfunkel A. Calcification of non-collagenous matrix in human gingiva: a light and electron microscopic study. *J Oral Pathol.* 1985 Aug;14(7):573-80. Pubmed PMID: 3928852.
- [38]. Appleton J, Williams MJ. Ultrastructural observations on the calcification of human dental pulp. *Calcif Tissue Res.* 1973 Mar;11(3):222-37.
- [39]. Ravinthar K. Recent advancements in laminates and veneers in dentistry. *Res J Pharm Technol.* 2018;11(2):785-7.
- [40]. Carr GB, Murgel CA. The use of the operating microscope in endodontics. *Dent Clin North Am.* 2010 Apr 1;54(2):191-214.
- [41]. Baskran RN, Pradeep S. Recent advancement of local anesthesia advancement to recent advancement of local anaesthesia administration. *Res J Pharm Technol.* 2016;9(10):1761-4.
- [42]. McCabe PS, Dummer PM. Pulp canal obliteration: an endodontic diagnosis and treatment challenge. *Int Endod J.* 2012 Feb;45(2):177-97.
- [43]. Noor SS. Chlorhexidine: Its properties and effects. *Res J Pharm Technol.* 2016;9(10):1755-60.
- [44]. Vijayashree Priyadharsini J. In silico validation of the non-antibiotic drugs acetaminophen and ibuprofen as antibacterial agents against red complex pathogens. *J Periodontol.* 2019 Dec;90(12):1441-1448. Pubmed PMID: 31257588.
- [45]. Pc J, Marimuthu T, Devadoss P, Kumar SM. Prevalence and measurement of anterior loop of the mandibular canal using CBCT: A cross sectional study. *Clin Implant Dent Relat Res.* 2018 Apr 6;20(4):531-4.
- [46]. Ramesh A, Varghese S, Jayakumar ND, Malaiappan S. Comparative estimation of sulfiredoxin levels between chronic periodontitis and healthy patients - A case-control study. *J Periodontol.* 2018 Oct;89(10):1241-1248. Pubmed PMID: 30044495.
- [47]. Ramadurai N, Gurunathan D, Samuel AV, Subramanian E, Rodrigues SJ. Effectiveness of 2% Articaine as an anesthetic agent in children: randomized controlled trial. *Clin Oral Investig.* 2019 Sep;23(9):3543-50.
- [48]. Sridharan G, Ramani P, Patankar S, Vijayaraghavan R. Evaluation of salivary metabolomics in oral leukoplakia and oral squamous cell carcinoma. *J Oral Pathol Med.* 2019 Apr;48(4):299-306.
- [49]. Ezhilarasan D, Apoorva VS, Ashok Vardhan N. Syzygium cumini extract induced reactive oxygen species-mediated apoptosis in human oral squamous carcinoma cells. *J Oral Pathol Med.* 2019 Feb;48(2):115-121. Pubmed PMID: 30451321.
- [50]. Mathew MG, Samuel SR, Soni AJ, Roopa KB. Evaluation of adhesion of *Streptococcus mutans*, plaque accumulation on zirconia and stainless steel crowns, and surrounding gingival inflammation in primary molars: randomized controlled trial. *Clin Oral Investig.* 2020 Sep;24(9):1-6. Pubmed PMID: 31955271.
- [51]. Samuel SR. Can 5-year-olds sensibly self-report the impact of developmental enamel defects on their quality of life? *Int J Paediatr Dent.* 2021 Mar;31(2):285-286. Pubmed PMID: 32416620.
- [52]. R H, Ramani P, Ramanathan A, R JM, S G, Ramasubramanian A, et al. CYP2 C9 polymorphism among patients with oral squamous cell carcinoma and its role in altering the metabolism of benzo[a]pyrene. *Oral Surg Oral Med Oral Pathol Oral Radiol.* 2020 Sep;130(3):306-312. Pubmed PMID: 32773350.
- [53]. Chandrasekar R, Chandrasekar S, Sundari KKS, Ravi P. Development and validation of a formula for objective assessment of cervical vertebral bone age. *Prog Orthod.* 2020 Oct 12;21(1):38. Pubmed PMID: 33043408.
- [54]. Vijayashree Priyadharsini J, Smiline Girija AS, Paramasivam A. In silico analysis of virulence genes in an emerging dental pathogen *A. baumannii* and related species. *Arch Oral Biol.* 2018 Oct;94:93-98. Pubmed PMID: 30015217.