

Cases Requiring Retreatment Due to Missed Canal - A Retrospective Analysis

Research Article

B. Vivek Babu¹, Dr. Sowmya. K^{2*}, Dr. SS Raj³¹Saveetha Dental College, Saveetha Institute of Medical and Technical Sciences (SIMATS), Saveetha University, Chennai, Tamil Nadu, India.²Senior Lecturer, Department of Conservative Dentistry and Endodontics, Saveetha Dental College, Saveetha Institute of Medical and Technical Sciences (SIMATS), Saveetha University, Chennai, Tamil Nadu, India.³Associate Professor, Department of Public Health Dentistry, Saveetha Dental College, Saveetha Institute of Medical and Technical Sciences (SIMATS), Saveetha University, Chennai, Tamil Nadu, India.

Abstract

The success of endodontic therapy requires thorough knowledge of root anatomy and its variations. A good debridement and cleaning of the root canal system of any infected pulp tissue and filling of the root canal space with an inert material prevents or minimises any chance of reinfection. This cannot be achieved when the clinicians fail to locate one or more canals. Hence this retrospective study was undertaken to analyse the teeth requiring re root canal treatment due to missed canals. Data of patients undergoing retreatment in Saveetha dental college was collected and reviewed to identify cases with missed canals. The data was tabulated and Chi square analysis done using IBM SPSS software version 20. Of all the cases analysed, 6.5% cases underwent retreatment due to missed canals (P value- 0.003 < 0.05; Chi square test). Within the limitations of this study, failure to locate and properly debride the canals is still one of the reasons for failure of root canal treatment, even with the advancements in diagnosis and magnification currently available.

Keywords: Diagnostic Aids; Missed Canal; Re-Infection; Retreatment; Root Canal Anatomy.

Introduction

The prognosis of Endodontic treatment is fairly predictable with a reported success rate of 86.95% [41, 38]. Endodontic failure is characterized by a recurrence of clinical symptoms alongside the presence of periapical radiolucency [15]. Several factors including persistent bacteria, improper root canal filling or coronal seal and iatrogenic errors contribute to this failure [52, 40].

The main aim of endodontic treatment is thorough debridement of the infected tissue and cleaning of the root canal space to be filled with an inert material. The root canal system is complex and hence the variations in the root canal morphology should be considered a rule rather than an exception [62, 49]. New root canal configurations are studied and reported by several authors in different populations [56, 17, 63]. Inadequate knowledge of the complexities of the root canal system hinders proper debridement and can result in reinfection and recurrence of symptoms leading to the failure of root canal treatment [50, 21].

Proper understanding and diagnosis is critical for achieving successful treatment outcomes. Conventional and angulated radiographs can provide a valuable insight into the number of canals present and their morphology [6, 27, 41]. A more sophisticated diagnostic aid like cone beam computed tomography (CBCT) has an advantage over conventional radiography as it allows clinician to have a three dimensional and multi slice view of the root canal system [33, 32]. The use of ultrasonic devices, trans illumination and endodontic microscopes are also an important adjunct in locating and managing the root canals and has made endodontic treatment more predictable [1, 35, 11].

A root canal retreatment becomes necessary when a previously root canal treated tooth fails to heal or if a recurrent infection is evident or the symptoms recurs [22]. It is not uncommon to miss a canal while carrying out endodontic therapy especially in multi rooted teeth where the number of canals often outnumbers the number of roots [13]. The inability to locate and treat all the canals is one of the causes for endodontic failure [36, 45]. Improper diagnosis and inadequate access opening makes it difficult to lo-

***Corresponding Author:**

Dr. Sowmya. K

Senior Lecturer, Department of Conservative Dentistry and Endodontics, Saveetha Dental College, Saveetha Institute of Medical and Technical Sciences (SIMATS), Saveetha University, Chennai, Tamil Nadu, India.

E-mail: sowmyak.sdc@saveetha.com

Received: July 30, 2021**Accepted:** August 10, 2021**Published:** August 17, 2021

Citation: B. Vivek Babu, Dr. Sowmya. K, Dr. SS Raj. Cases Requiring Retreatment Due to Missed Canal - A Retrospective Analysis. *Int J Dentistry Oral Sci.* 2021;8(8):3877-3881. doi: <http://dx.doi.org/10.19070/2377-8075-21000793>

Copyright: Dr. Sowmya. K©2021. This is an open-access article distributed under the terms of the Creative Commons Attribution License, which permits unrestricted use, distribution and reproduction in any medium, provided the original author and source are credited.

cate all the canals [16]. Bacteria residing in these missed canals causes persistent infection and symptoms [45, 16].

Previously our team has a rich experience in working on various research projects across multiple disciplines. (Jain, 2017 [14]), (Varghese, Ramesh and Veeraiyan, 2019 [54]), (Ashok and Ganapathy, 2019 [3]), (Padavala and Sukumaran, 2018 [28]), (Ke et al., 2019 [18]), (Ezhilarasan, 2018 [7]), (Krishnan et al., 2018 [20]), (Ezhilarasan, Sokal and Najimi, 2018 [9]), (Pandian, Krishnan and Kumar, 2018 [30]), (Ramamurthy and Mg, 2018 [39]), (Gupta, Ariga and Deogade, 2018 [10]), (Vikram et al., 2017 [60]), (Paramasivam, Vijayashree Priyadharsini and Raghunandhakumar, 2020 [31]), (Palati et al., 2020 [29]), (Samuel, Acharya and Rao, 2020 [47]) Now the growing trend in this area motivated us to pursue this project.

In spite of all the advancements, the location of all the canals has still been challenging. Hence the aim of this study was to evaluate the cases requiring re root canal treatment due to missed canals [53].

Materials and Methods

This was a retrospective study done in a university setting. An institutional committee approval was obtained to access the personal data of the patients. The data of patients requiring re root canal treatment from the period of June 2019 to April 2020 was collected and analysed. The teeth requiring retreatment were examined clinically and radiographically. Cross verification was done by two reviewers to minimise bias. The type of teeth requiring retreatment and the reason for retreatment was noted. Any reason for retreatment other than the presence of missed canals (iatro-

genic errors, over obscuration, under obscuration, persistent lesion) was put together as other reasons. The data was tabulated and analysed using IBM SPSS software version 20. Descriptive statistics was done to determine the frequency percentage and Chi square test was done to find the association between the teeth requiring retreatment and the reason for retreatment. The level of significance was set at 0.05.

Results & Discussion

A total of 307 retreatment cases were analysed. The frequency of retreatment performed was highest for the anteriors (45.6%) followed by molars (35.5%) and anteriors (18.9%) [Figure 1]. The frequency of teeth requiring retreatment was higher in the mandibular arch (62.9) than the maxillary arch (37.1%) [Figure 2]. Of all the cases evaluated, only 6.5% of cases required retreatment due to missed canals [Figure 3].

The number of teeth requiring retreatment due to missed canals was significantly lower compared to other reasons for retreatment (Chi square: p value-0.003) [Figure 4]. On analysing the tooth type and arch in teeth requiring retreatment due to missed canals, no significant association was found (Chi square: p value- 0.871) [Figure 5]. This could be attributed to the less number of cases that required retreatment due to missed canals.

In our study, out of all the cases analysed, only 6.5% required retreatment due to a missed canal. Previous studies have reported varying percentages of missed canals in teeth requiring retreatment. A study evaluating the most common possible causes of failure of endodontically treated teeth found the most common reason to be leakage around the canal filling material (30.4%), followed by a missed canal (19.7%), underfilling (14.2%), anatomical complexity (8.7%), overfilling (3.0%), iatrogenic problems (2.8%),

Figure 1: Bar diagram representing the type of tooth requiring retreatment. X-axis represents the type of tooth and Y-axis represents the percentage of teeth undergoing retreatment. Here, yellow denotes anterior teeth, brown denotes molars and pink denotes premolars. The highest percentage of teeth that underwent retreatment were anteriors (45.6%) followed by molars (35.5%) and premolars (18.9%).

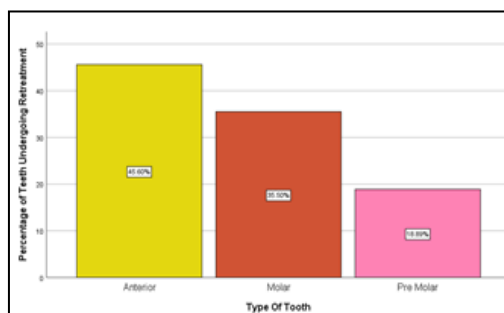


Figure 2: Bar diagram representing the arch involved in retreatment. X-axis represents the arch involved and Y-axis represents the percentage of teeth undergoing retreatment. Here, blue represents maxillary arch and pink represents mandibular arch. The highest percentage of retreatment was done for maxillary teeth (62.87%) than mandibular teeth (37.13%).

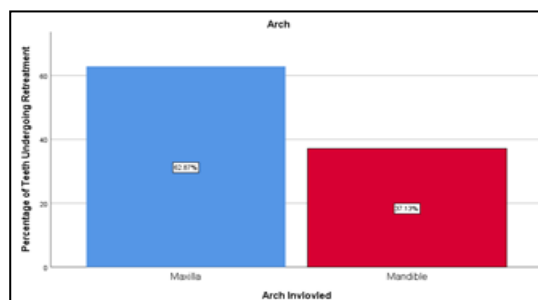


Figure 3: Bar diagram representing reasons for retreatment. X-axis represents the reason for retreatment and Y-axis represents the percentage of teeth undergoing retreatment. Here, purple denotes retreatment due to missed canals and green denotes other reasons for retreatment. Only 6.51% of the total cases underwent retreatment due to missed canals.

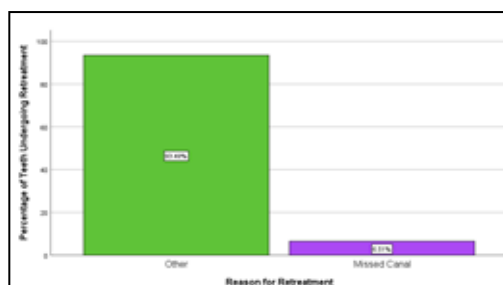


Figure 4: Bar graph showing association between the type of tooth and reason for Retreatment. X-axis represents the type of tooth and Y-axis represents the number of teeth undergoing retreatment. The number of teeth with Missed Canals was higher in molars than premolars and anteriors. The frequency of other reasons for retreatment was higher than missed canals for all type of teeth and this was statistically significant (P value- 0.003 < 0.05; Chi square test).

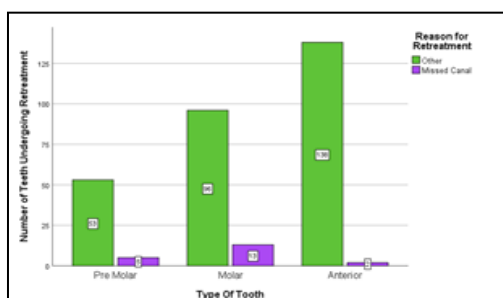
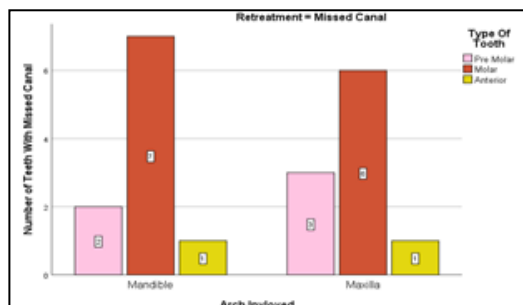


Figure 5: Bar graph showing association between type of tooth and arch involved in retreatment cases with missed canals. X-axis represents the arch involved and Y-axis represents the number of teeth with missed canals. Missed canals were highest in molars in both maxillary and mandibular arches. However, no significant association was found between the arch and type of tooth involved in retreatment cases with missed canals (P value- 0.871 > 0.05; Chi square test)



apical calculus (1.8%), and cracks (1.2%) [19]. According to another study, the evidence of missed canals was reported to be 42% of all 1100 endodontically failing teeth [12]. In a study conducted by David E Witherspoon et al., missed canals were identified in 64 of the 133 previously root canal treated teeth (48%) [61, 23].

With the recent developments in diagnostic imaging, the understanding of root canal anatomy has drastically improved. The incidence of two canals at the tooth's apex is reported to be 1% to 43% [55, 26]. Failure to locate all the canals present has been recognised as a reason for failure in different teeth. The most supreme reason for endodontic failure of mandibular central incisors was found to be the presence of an undetected lingual canal or an untreated isthmus [55, 48]. The prevalence of two canals in mandibular incisors has been reported to be from 11.5% to 44.1% although many merge into one canal in the apical 1–3 mm of the root [56, 48].

Mandibular premolars are known to be the most difficult teeth to treat and are found to have the highest rate of non-surgical endodontic treatment failure (11.45%). This is attributed to the high variations in the root canal morphology and the difficulty in accessing the second canal [57]. One study found a prevalence of two canals to be 27.8% and 8.9% in first and second mandibular premolars respectively, and when this is not identified, it will affect the outcome [62, 43].

Among the different teeth, molars had the highest number that required retreatment due to missed canals in this study. In multirooted molar teeth, of the total missed canals, 44% involved maxillary first molar and 11% involved a maxillary second molar. One previous study has shown that for the maxillary first molars, 93% of all missed canals were identified in the mesiobuccal root whereas in the mandibular second molars, 29% of missed canals were identified in the distal and 71% in the mesial root. In the mandibular first molars, 86% of the missed canals were identified in the distal and 14% were identified in the mesial root [61].

Most problems that occur during endodontic treatment are due to inadequate knowledge about the tooth morphology and root canal system (Al-Qudah and Awawdeh, 2006). Hence it is imperative to assess the morphology of the root canals and their numerous variations before initiating root canal treatment to ensure long term prognosis [56, 2, 4].

The small sample size was the major limitation of the study. Evaluation of a greater number of samples can provide better understanding on the distribution and impact of missed canals on primary root canal treatment. Future studies can be combined with CBCT evaluation of teeth to corroborate the clinical and radiographic findings.

Our institution is passionate about high quality evidence based research and has excelled in various fields (Pc, Marimuthu and Devadoss, 2018 [34]; Ramesh et al., 2018 [41]; Vijayashree Priyadharsini, Smiline Girija and Paramasivam, 2018 [59]; Ezhilarasan, Apoorva and Ashok Vardhan, 2019 [8]; Ramadurai et al., 2019 [37]; Sridharan et al., 2019 [[51]]; Vijayashree Priyadharsini, 2019 [58]; Chandrasekar et al., 2020 [5]; Mathew et al., 2020 [24]; R et al., 2020 [44]; Samuel, 2021 [46]). We hope this study adds to this rich legacy.

Conclusion

Within the limitations of this retrospective study, we conclude that the number of teeth requiring retreatment due to missed canals was significantly lower compared to other reasons for retreatment. Proper knowledge and understanding the complexities of the root canal system along with the use of advanced diagnostic aids and magnification can help in identification and adequate disinfection of root canals, ensuring long term success of the endodontically treated teeth.

References

- [1]. Alaçam T, Tinaz AC, Genç O, Kayaoglu G. Second mesiobuccal canal detection in maxillary first molars using microscopy and ultrasonics. *Aust Endod J.* 2008 Dec;34(3):106-9. Pubmed PMID: 19032644.
- [2]. Al-Qudah AA, Awawdeh LA. Root canal morphology of mandibular incisors in a Jordanian population. *Int Endod J.* 2006 Nov;39(11):873-7. Pubmed PMID: 17014525.
- [3]. Ashok V, Ganapathy D. A geometrical method to classify face forms. *J Oral Biol Craniofac Res.* 2019 Jul-Sep;9(3):232-235. doi: 10.1016/j.job-cr.2019.06.001. Pubmed PMID: 31198677.
- [4]. Calişkan MK, Pehlivan Y, Sepetçioğlu F, Türkün M, Tuncer SS. Root canal morphology of human permanent teeth in a Turkish population. *J Endod.* 1995 Apr;21(4):200-4. Pubmed PMID: 7673821.
- [5]. Chandrasekar R, Chandrasekar S, Sundari KKS, Ravi P. Development and validation of a formula for objective assessment of cervical vertebral bone age. *Prog Orthod.* 2020 Oct 12;21(1):38. Pubmed PMID: 33043408.
- [6]. Curtin C. *The Principles of Endodontics*. 2nd edn Edited by Shanon Patel & Justin J. Barnes. Oxford University Press. *International Endodontic Journal.* 2014;497-497.
- [7]. Ezhilarasan D. Oxidative stress is bane in chronic liver diseases: Clinical and experimental perspective. *Arab J Gastroenterol.* 2018 Jun;19(2):56-64. Pubmed PMID: 29853428.
- [8]. Ezhilarasan D, Apoorva VS, Ashok Vardhan N. Syzygium cumini extract induced reactive oxygen species-mediated apoptosis in human oral squamous carcinoma cells. *J Oral Pathol Med.* 2019 Feb;48(2):115-121. Pubmed PMID: 30451321.
- [9]. Ezhilarasan D, Sokal E, Najimi M. Hepatic fibrosis: It is time to go with hepatic stellate cell-specific therapeutic targets. *Hepatobiliary Pancreat Dis Int.* 2018 Jun;17(3):192-197. Pubmed PMID: 299709350.
- [10]. Gupta P, Ariga P, Deogade SC. Effect of Monopoly-coating Agent on the

Surface Roughness of a Tissue Conditioner Subjected to Cleansing and Disinfection: A Contact Profilometric In vitro Study. *Contemp Clin Dent.* 2018 Jun;9(Suppl 1):S122-S126. Pubmed PMID: 29962776.

- [11]. Gutmann JL, Lovdahl PE. 'Problem Solving in Tooth Isolation, Access Openings, and Identification of Orifice Locations'. *Problem Solving in Endodontics.* 2011;150-176.
- [12]. Hoehn MM, Pink FE. Contemporary endodontic retreatments: an analysis based on clinical treatment findings. *J Endod.* 2002 Dec;28(12):834-6. Pubmed PMID: 12489654.
- [13]. Hussainy SN, Nasim I, Thomas T, Ranjan M. Clinical performance of resin-modified glass ionomer cement, flowable composite, and polyacid-modified resin composite in noncarious cervical lesions: One-year follow-up. *J Conserv Dent.* 2018 Sep-Oct;21(5):510-515. Pubmed PMID: 30294112.
- [14]. Jain AR. Prevalence of Partially Edentulousness and Treatment Needs in Rural Population of South India'. *World journal of dentistry.* 2013;8(3):213-217.
- [15]. Janani K, Palanivelu A, Sandhya R. Diagnostic accuracy of dental pulse oximeter with customized sensor holder, thermal test and electric pulp test for the evaluation of pulp vitality: an in vivo study. *Brazilian dental science.* 2020 Jan 31;23(1):8
- [16]. Jose J, Subbaiyan H. Different treatment modalities followed by dental practitioners for Ellis class 2 fracture - A questionnaire-based survey. *The open dentistry journal.* 2020 Feb 18;14(1).
- [17]. Kartal N, Yanikoğlu FC. Root canal morphology of mandibular incisors. *J Endod.* 1992 Nov;18(11):562-4. Pubmed PMID: 1298794.
- [18]. Ke Y, Al Aboudy MS, Alturaiki W, Alsagaby SA, Alfaiz FA, Veeraraghavan VP, Mickymaray S. Photosynthesized gold nanoparticles from *Catharanthus roseus* induces caspase-mediated apoptosis in cervical cancer cells (HeLa). *Artif Cells Nanomed Biotechnol.* 2019 Dec;47(1):1938-1946. Pubmed PMID: 31099261.
- [19]. Kim SY, Kim BS, Woo J, Kim Y. Morphology of mandibular first molars analyzed by cone-beam computed tomography in a Korean population: variations in the number of roots and canals. *J Endod.* 2013 Dec;39(12):1516-21. Pubmed PMID: 24238439.
- [20]. Krishnan RP, Ramani P, Sherlin HJ, Sukumaran G, Ramasubramanian A, Jayaraj G, Don KR, Santhanam A. Surgical Specimen Handover from Operation Theater to Laboratory: A Survey. *Ann Maxillofac Surg.* 2018 Jul-Dec;8(2):234-238. Pubmed PMID: 30693238.
- [21]. Kumar D, Antony S. Calcified canal and negotiation-A review. *Research J Pharm Technol.* 2018;11(8):3727-30.
- [22]. Lin LM, Pascon EA, Skribner J, Gängler P, Langeland K. Clinical, radiographic, and histologic study of endodontic treatment failures. *Oral Surg Oral Med Oral Pathol.* 1991 May;71(5):603-11. Pubmed PMID: 2047103.
- [23]. Manohar MP, Sharma S. A survey of the knowledge, attitude, and awareness about the principal choice of intracanal medicaments among the general dental practitioners and nonendodontic specialists. *Indian J Dent Res.* 2018 Nov-Dec;29(6):716-720. Pubmed PMID: 30588997.
- [24]. Mathew MG, Samuel SR, Soni AJ, Roopa KB. Evaluation of adhesion of *Streptococcus mutans*, plaque accumulation on zirconia and stainless steel crowns, and surrounding gingival inflammation on primary molars: randomized controlled trial. *Clin Oral Investig.* 2020 Sep;24(9):3275-3280. Pubmed PMID: 31955271.
- [25]. Mathew MG, Samuel SR, Soni AJ, Roopa KB. Evaluation of adhesion of *Streptococcus mutans*, plaque accumulation on zirconia and stainless steel crowns, and surrounding gingival inflammation on primary molars: randomized controlled trial. *Clin Oral Investig.* 2020 Sep;24(9):3275-3280. Pubmed PMID: 31955271.
- [26]. Nandakumar M, Nasim I. Comparative evaluation of grape seed and cranberry extracts in preventing enamel erosion: An optical emission spectrometric analysis. *J Conserv Dent.* 2018 Sep-Oct;21(5):516-520. Pubmed PMID: 30294113.
- [27]. Noor SS. Chlorhexidine: Its properties and effects. *Res J Pharm Technol.* 2016;9(10):1755-60.
- [28]. Padavala S, Sukumaran G. Molar incisor hypomineralization and its prevalence. *Contemporary clinical dentistry.* 2018 Sep;9(Suppl 2):S246.
- [29]. Palati S, Ramani P, Shrelin HJ, Sukumaran G, Ramasubramanian A, Don KR, Jayaraj G, Santhanam A. Knowledge, Attitude and practice survey on the perspective of oral lesions and dental health in geriatric patients residing in old age homes. *Indian J Dent Res.* 2020 Jan-Feb;31(1):22-25. Pubmed PMID: 32246676.
- [30]. Pandian KS, Krishnan S, Kumar SA. Angular photogrammetric analysis of the soft-tissue facial profile of Indian adults. *Indian J Dent Res.* 2018 Mar-Apr;29(2):137-143. Pubmed PMID: 29652003.
- [31]. Paramasivam A, Vijayashree Priyadharsini J, Raghunandhakumar S. N6-adenosine methylation (m6A): a promising new molecular target in hypertension and cardiovascular diseases. *Hypertens Res.* 2020 Feb;43(2):153-154. Pubmed PMID: 31578458.
- [32]. Patel S, Dawood A, Ford TP, Whites E. The potential applications of cone

- beam computed tomography in the management of endodontic problems. *Int Endod J.* 2007 Oct;40(10):818-30. Pubmed PMID: 17697108.
- [33]. Patel S, Brown J, Pimentel T, Kelly RD, Abella F, Durack C. Cone beam computed tomography in Endodontics - a review of the literature. *Int Endod J.* 2019 Aug;52(8):1138-1152. Pubmed PMID: 30868610.
- [34]. J PC, Marimuthu T, C K, Devadoss P, Kumar SM. Prevalence and measurement of anterior loop of the mandibular canal using CBCT: A cross sectional study. *Clin Implant Dent Relat Res.* 2018 Aug;20(4):531-534. Pubmed PMID: 29624863.
- [35]. Plotino G, Buono L, Grande NM, Pameijer CH, Somma F. Nonvital tooth bleaching: a review of the literature and clinical procedures. *J Endod.* 2008 Apr;34(4):394-407. Pubmed PMID: 18358884.
- [36]. Rajendran R, Kunjankaran RN, Sandhya R, Anilkumar A, Santhosh R, Patil SR. Comparative evaluation of remineralizing potential of a paste containing bioactive glass and a topical cream containing casein phosphopeptide-amorphous calcium phosphate: An in vitro study. *Pesquisa brasileira em odontopediatria e clinica integrada.* 2019 Oct 10;19.
- [37]. Ramadurai N, Gurunathan D, Samuel AV, Subramanian E, Rodrigues SJL. Effectiveness of 2% Articaine as an anesthetic agent in children: randomized controlled trial. *Clin Oral Investig.* 2019 Sep;23(9):3543-3550. Pubmed PMID: 30552590.
- [38]. Ramamoorthi S, Nivedhitha MS, Divyanand MJ. Comparative evaluation of postoperative pain after using endodontic needle and EndoActivator during root canal irrigation: A randomised controlled trial. *Aust Endod J.* 2015 Aug;41(2):78-87. Pubmed PMID: 25195661.
- [39]. Ramamurthy JA, Mg V. Comparison of effect of Hiora mouthwash versus Chlorhexidine mouthwash in gingivitis patients: A clinical trial. *Asian J Pharm Clin Res.* 2018 Jul 7;11(7):84-8.
- [40]. Ramanathan S, Solete P. Cone-beam Computed Tomography Evaluation of Root Canal Preparation using Various Rotary Instruments: An in vitro Study. *J Contemp Dent Pract.* 2015 Nov 1;16(11):869-72. Pubmed PMID: 26718293.
- [41]. Ramesh A, Varghese S, Jayakumar ND, Malaiappan S. Comparative estimation of sulfiredoxin levels between chronic periodontitis and healthy patients - A case-control study. *J Periodontol.* 2018 Oct;89(10):1241-1248. Pubmed PMID: 30044495.
- [42]. Teja KV, Ramesh S, Priya V. Regulation of matrix metalloproteinase-3 gene expression in inflammation: A molecular study. *J Conserv Dent.* 2018 Nov-Dec;21(6):592-596. Pubmed PMID: 30546201.
- [43]. Ravinthar K. Recent advancements in laminates and veneers in dentistry. *Res J Pharm Technol.* 2018;11(2):785-7.
- [44]. R H, Ramani P, Ramanathan A, R JM, S G, Ramasubramanian A, K M. CYP2 C9 polymorphism among patients with oral squamous cell carcinoma and its role in altering the metabolism of benzo[a]pyrene. *Oral Surg Oral Med Oral Pathol Oral Radiol.* 2020 Sep;130(3):306-312. Pubmed PMID: 32773350.
- [45]. Rajakeerthi R, Nivedhitha MS. Natural Product as the Storage medium for an avulsed tooth—A Systematic Review. *Cumhuriyet Dent J.* 2019 Jun 11;22(2):249-56.
- [46]. Samuel SR. Can 5-year-olds sensibly self-report the impact of developmental enamel defects on their quality of life? *Int J Paediatr Dent.* 2021 Mar;31(2):285-286. Pubmed PMID: 32416620.
- [47]. Samuel SR, Acharya S, Rao JC. School Interventions-based Prevention of Early-Childhood Caries among 3-5-year-old children from very low socioeconomic status: Two-year randomized trial. *J Public Health Dent.* 2020 Jan;80(1):51-60. doi: 10.1111/jphd.12348. Epub 2019 Nov 10. PMID: 31710096.
- [48]. Bhat SP, Sheth R, Kumar P, Khilosiya A. Root canal morphology and assessment of incidence, type, and position of isthmus in permanent mandibular central incisor in North Indian population: An in vitro study. *Endodontology.* 2017 Jul 1;29(2):107.
- [49]. Siddique R, Sureshbabu NM, Somasundaram J, Jacob B, Selvam D. Qualitative and quantitative analysis of precipitate formation following interaction of chlorhexidine with sodium hypochlorite, neem, and tulsi. *J Conserv Dent.* 2019 Jan-Feb;22(1):40-47. Pubmed PMID: 30820081.
- [50]. Siqueira JF Jr. Aetiology of root canal treatment failure: why well-treated teeth can fail. *Int Endod J.* 2001 Jan;34(1):1-10. Pubmed PMID: 11307374.
- [51]. Sridharan G, Ramani P, Patankar S, Vijayaraghavan R. Evaluation of salivary metabolomics in oral leukoplakia and oral squamous cell carcinoma. *J Oral Pathol Med.* 2019 Apr;48(4):299-306. Pubmed PMID: 30714209.
- [52]. Tabassum S, Khan FR. Failure of endodontic treatment: The usual suspects. *Eur J Dent.* 2016 Jan-Mar;10(1):144-147. Pubmed PMID: 27011754.
- [53]. Teja KV, Ramesh S. Shape optimal and clean more. *Saudi Endodontic Journal.* 2019 Sep 1;9(3):235.
- [54]. Varghese SS, Ramesh A, Veeraiyan DN. Blended Module-Based Teaching in Biostatistics and Research Methodology: A Retrospective Study with Postgraduate Dental Students. *J Dent Educ.* 2019 Apr;83(4):445-450. Pubmed PMID: 30745352.
- [55]. Vertucci FJ. Root canal anatomy of the mandibular anterior teeth. *J Am Dent Assoc.* 1974 Aug;89(2):369-71. Pubmed PMID: 4527223.
- [56]. Vertucci FJ. Root canal anatomy of the human permanent teeth. *Oral Surg Oral Med Oral Pathol.* 1984 Nov;58(5):589-99. Pubmed PMID: 6595621.
- [57]. Vertucci FJ, Haddix JE. 'Tooth Morphology and Access Cavity Preparation', Cohen's Pathways of the Pulp. 2011;136-222.
- [58]. Vijayashree Priyadharsini J. In silico validation of the non-antibiotic drugs acetaminophen and ibuprofen as antibacterial agents against red complex pathogens. *J Periodontol.* 2019 Dec;90(12):1441-1448. Pubmed PMID: 31257588.
- [59]. Vijayashree Priyadharsini J, Smiline Girija AS, Paramasivam A. In silico analysis of virulence genes in an emerging dental pathogen *A. baumannii* and related species. *Arch Oral Biol.* 2018 Oct;94:93-98. Pubmed PMID: 30015217.
- [60]. Vikram NR, Prabhakar R, Kumar SA, Karthikeyan MK, Saravanan R. Ball Headed Mini Implant. *J Clin Diagn Res.* 2017 Jan;11(1):ZL02-ZL03. Pubmed PMID: 28274084.
- [61]. Witherspoon DE, Small JC, Regan JD. Missed canal systems are the most likely basis for endodontic retreatment of molars. *Tex Dent J.* 2013 Feb;130(2):127-39. PMID: 23930451.
- [62]. Yadav RK, Wadhvani KK, Tikku AP, Chandra A, Hasija M. Use of recent diagnostic methods in locating multiple canals: A case series of six canals in maxillary first molar. *European Journal of General Dentistry.* 2012 Sep 1;1(3):207.
- [63]. Zhang R, Wang H, Tian YY, Yu X, Hu T, Dummer PM. Use of cone-beam computed tomography to evaluate root and canal morphology of mandibular molars in Chinese individuals. *Int Endod J.* 2011 Nov;44(11):990-9. doi: 10.1111/j.1365-2591.2011.01904.x. Epub 2011 Jun 10. PMID: 21658074.