

## Unicystic Mural Ameloblastoma: An Case Report and Review of literature

Case Report

Rezin Ahmed<sup>1</sup>, Pradeep D<sup>2\*</sup>, M.R.Muthusekhar<sup>3</sup><sup>1</sup> Saveetha Dental College, Saveetha Institute of Medical and Technical Sciences, Saveetha University, Chennai 600 077, Tamilnadu, India.<sup>2</sup> Senior Lecturer, Department of Conservative Dentistry and Endodontics, Saveetha Dental College, Saveetha Institute of Medical and Technical Sciences, Saveetha University, Chennai 600 077, Tamilnadu, India.<sup>3</sup> Professor and Head, Department of Periodontics, Saveetha Dental College, Saveetha Institute of Medical and Technical Sciences, Saveetha University, Chennai, India.

### Abstract

Ameloblastoma is a benign odontogenic neoplasm which frequently affects the mandible. The term ameloblastoma includes several clinicoradiological and histological types. Apart from the most commonly encountered clinicopathologic models, there are few variants, whose biological profile is unknown or not elicited. Among these types, unicysticameloblastoma is the least encountered variant of the ameloblastoma. Unicysticameloblastoma refers to those cystic lesions that show clinical, radiographic, or gross features of a jaw cyst but on histologic examination show a typical ameloblastomatous epithelium lining the cyst cavity, with or without luminal and/or mural tumor proliferation. Unicysticameloblastoma is a less encountered variant of the ameloblastoma and is believed to be less aggressive. As this tumor shows considerable similarities with dentigerous cysts, both clinically and radiographically, the biologic behaviour of this tumor group was reviewed. Moreover, recurrence of unicysticameloblastoma may be long delayed, and a long-term postoperative followup is essential for proper management of these patients. Here we are presenting a case of unicysticameloblastoma in an 18-year-old female patient.

### Introduction

Many benign lesions cause mandibular swellings, and these can be divided into odontogenic and nonodontogenic origin. The most common tumor of odontogenic origin is ameloblastoma which develops from epithelial cellular elements and dental tissues in their various phases of development. More than 80% of all ameloblastomas are solid or multicystic variants, with unicysticameloblastoma being an important clinicopathologic form of ameloblastoma and occupying the remaining 20% of the cases along with peripheral ameloblastoma [1]. Unicysticameloblastoma, a variant of ameloblastoma, was first described by Ackermann et al. in 1988 [2]. Unicysticameloblastoma (UCA) is the most common term used to designate its different pathological entities. Sometimes these can present as a multilocular radiolucency which makes the use of the term “cystic ameloblastoma” more appropriate. However, some authors still believe that the notion that cystic ameloblastomas can have a “true” clinically multicystic pattern is arguable and contend with the use of the term “unicysticameloblastoma” [3, 4].

The unicysticameloblastoma is a less encountered variant of the ameloblastoma, referring to those cystic lesions that show clinical and radiographic characteristics of an odontogenic cyst but in histologic examination show a typical ameloblastomatous epithelium lining part of the cyst cavity, with or without luminal and/or mural tumor proliferation [5]. This paper illustrates a case of unicystic (mural) ameloblastoma of the mandible in an 18-year-old female.

### Case Report

An 27-year-old male patient reported to our outpatient department with a chief complaint of swelling in the lower right front teeth region, for 3 months. Patient was apparently well 3 months back and noticed a swelling, for 3 months. Pain was of dull aching type, which was intermitted, and it aggravates on putting mastication and relieves on rest. Pain was not associated with fever and no medication was taken. On extraoral examination a diffuse swelling was seen on the lower third of the face extending onto

#### \*Corresponding Author:

Pradeep D,

Senior Lecturer, Department of Conservative Dentistry and Endodontics, Saveetha Dental College, Saveetha Institute of Medical and Technical Sciences, Saveetha University, Chennai 600 077, Tamilnadu, India.

E-mail: [pradeep@saveetha.com](mailto:pradeep@saveetha.com)**Received:** April 28, 2021**Accepted:** July 09, 2021**Published:** July 29, 2021**Citation:** Rezin Ahmed, Pradeep D, M.R.Muthusekhar. Unicystic Mural Ameloblastoma: An Case Report and Review of literature. *Int J Dentistry Oral Sci.* 2021;8(7):3534-3537. C doi: <http://dx.doi.org/10.19070/2377-8075-21000722>**Copyright:** Pradeep D<sup>2</sup>2021. This is an open-access article distributed under the terms of the Creative Commons Attribution License, which permits unrestricted use, distribution and reproduction in any medium, provided the original author and source are credited.

Figure 1.

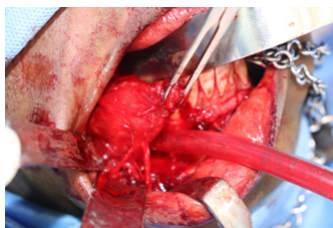


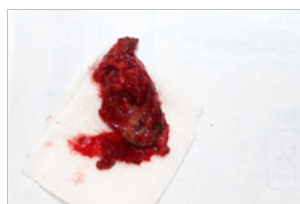
Figure 2.

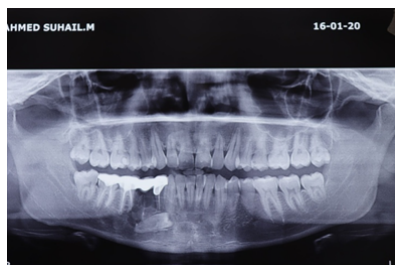

Figure 3.

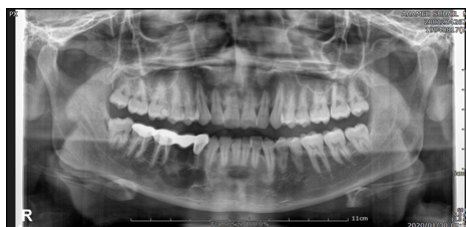

Figure 4.



the left side with mild obliteration of mentolabial sulcus which is measuring about app  $4 \times 3$  cm in size. Overlying skin was normal; no visible pulsations and no discharge were seen. On palpation, the swelling was soft in consistency and tender; no local rise of temperature was felt. It was nonpulsatile and noncompressible, and no discharge was present. On intraoral examination, a single diffuse swelling was seen in the mandibular right buccal vestibule irt 43, 44, 45, and regions measuring approximately  $4 \times 2$  cms. It extends anterioposteriorly-from the mandibular labial frenum to 45 and superior-inferiorly from the attached gingival to the labial vestibule. Tenderness was elicited on palpation irt 43, 44, and 45. The swelling was firm in consistency, and surface was smooth. It was nonfluctuant and nonreducible and no discharge was noticed, non were pulsations felt (Figure 2). On needle aspiration, brown yellow fluid was aspirated. Based on the patient's history and clinical finding, the diagnosis was given as dentigerous cyst.

## Discussion

Ameloblastoma is a benign, locally aggressive odontogenic neoplasm with variable clinical expression and accounts for 1% of all cysts/tumors of jaws and 18% of all odontogenic neoplasms. It is typically slow growing, locally aggressive and rarely metastasizes but has a high rate of recurrence (55–90%) if not removed

adequately.

As per the WHO system of 2003, ameloblastoma is classified based on differences in biologic behavior, treatment plan and recurrence rate as follows:

- (1) classic solid/multicystic ameloblastoma,
- (2) unicystic ameloblastoma,
- (3) peripheral ameloblastoma,
- (4) desmoplastic ameloblastoma, including the so-called hybrid lesions [3].

Unicystic ameloblastoma (UCA) is a rare type of ameloblastoma, accounting for about 6% of ameloblastomas. It usually occurs in a younger age group of 16–20 years, with about 50% of the cases occurring in the second decade of life as in our case [9, 10]. The gender distribution shows a slight male predilection with a male to female ratio of 1.6:1. However, when the tumor is not associated with an unerupted tooth, the gender ratio is reversed to a male to female ratio of 1:1.8 [11]. More than 90% are located in the mandible in the posterior region, followed by the parasymphysis region, the anterior maxilla, and the posterior maxilla [9]. UCA is usually asymptomatic, although a large tumor may cause painless swelling of the jaws with facial asymmetry [9]. Mucosal ulceration is rare but may be caused by continued growth of the tu-

mor [12]. The clinical and radiographic findings in most cases of unicysticameloblastoma suggest that the lesion is an odontogenic cyst, particularly dentigerous cyst. However, few are not associated with impacted teeth which are called nondentigerous variant [12]. The mean age of nonimpacted tooth-related cystic ameloblastoma was 5 years in comparison to 16.5 years for the impacted tooth-related variant [2]. Most of the UCAs are associated with an impacted tooth, the mandibular third molar being involved most often. But in our case it was associated with impacted mandibular canine, and it is a dentigerous variant. These findings correlate with those reported by Philipsen et al. and Ackermann et al.

The radiographic appearance of UCAs has been divided into 2 main patterns: unilocular and multilocular, and these have clear preponderance for the unilocular pattern. This preponderance is predominantly marked for the dentigerous variant, where the unilocular to multilocular ratio is 4.3:1, and for the nondentigerous type, this ratio is 1.1:1 [4, 13]. The involved teeth show varying degrees of root resorption [3].

Eversole et al. and Paikkatt et al. identified predominant radiographical patterns for UCA: unilocular, scalloped macromultilocular, pericoronal, interradicular, or periapical expansile radiolucencies [4, 14]. Our case study had a peculiar radiographic presentation of multilocular radiolucency crossing the midline of the mandible. The early ameloblastic changes within the cyst wall were first described by Vickers and Gorlin in 1970, and their histologic criteria for the diagnosis of unicysticameloblastoma includes a cyst lined by ameloblastic epithelium with a tall columnar basal layer, subnuclear vacuoles, reverse polarity of hyperchromatic nucleus, and a thin layer of oedematous, degenerating stellate reticulum-like cells on the surface [15]. The mural extension into the cystic wall is the frequently seen feature, and the term mural UCA is used when the thickened lining (either plexiform or follicular) penetrates the adjacent capsular tissue [1, 9].

In a clinicopathologic study of 57 cases of unicysticameloblastoma, Ackermann classified this entity into the following three histologic groups [2, 16]:

Group I-luminal UA (tumor confined to the luminal surface of the cyst);

Group II-intraluminal/plexiform UA (nodular proliferation into the lumen without infiltration of tumor cells into the connective tissue wall);

Group III-mural UA (invasive islands of ameloblastomatous epithelium in the connective tissue wall not involving the entire epithelium). According to this classification, our case study belongs to Group III.

Histologic subgrouping by Philipsen and Reichart has also been described:

Subgroup 1-luminal UA;

Subgroup 1.2-luminal and intraluminal;

Subgroup 1.2.3-luminal, intraluminal and intramural;

Subgroup 1.3-luminal and intramural.

A definitive diagnosis of unicystic ameloblastoma can only be done by histological examination of the entire lesion and cannot be predicted preoperatively on clinical or radiographic grounds. As preoperative incisional biopsy is not representative of the en-

tire lesion, it may result in an incorrect classification. The epithelial lining of a UCA is not always uniformly characteristic and is often lined partly by a nonspecific thin epithelium that mimics the dentigerous cyst lining. Thus, true nature of the lesion becomes evident only after enucleation when the entire specimen is available for microscopy [12]. The pathogenesis of cystic ameloblastomas remains obscure. Whether UCA originates de novo as a neoplasm or whether it is a result of neoplastic transformation of nonneoplastic cyst epithelium has long been debated. Some investigators believe that UCA arises from preexisting odontogenic cysts, in particular a dentigerous cyst, while others maintain that it arises de novo. Ackermann et al. (1988) and Robinson and Martínez (1977) argued that as the epithelium of odontogenic cysts and ameloblastomas have a common ancestry, a transition from a nonneoplastic to a neoplastic one could be possible, even though it occurs infrequently [2, 17].

Leider et al. (1985) proposed three pathogenic mechanisms for the evolution of UA [18].

(1) The reduced enamel epithelium which is associated with a developing tooth undergoes ameloblastic transformation with subsequent cystic development.

(2) Ameloblastomas arise in dentigerous cysts or in others in which the neoplastic ameloblastic epithelium is preceded temporarily by a nonneoplastic stratified squamous epithelial lining.

(3) A solid ameloblastoma undergoes cystic degeneration of the ameloblastic islands, with subsequent fusion of multiple microcysts and develops into unicystic lesions.

Several attempts have been made in the past to distinguish the lining of the UCAs from that of odontogenic cysts. However, immunohistochemical markers like lectins (*Ulexeuropaeus* agglutinin I and *Bandeiraea simplicifolia* agglutinin I) and proliferating cells (proliferating cell nuclear antigen (PCNA) and Ki-67) may assist in their differential diagnosis [19]. However, Eversole et al. contend that currently unaided histologic assessment for UCA remains the gold standard for diagnosis, because of a variable response of UCA to tissue markers. Histologically, the minimum criteria for diagnosing a lesion as UCA are the demonstration of a single cystic sac lined by odontogenic (ameloblastomatous) epithelium often seen only in focal areas [20]. Treatment planning depends on the histological type of UA. The UA which is diagnosed as subgroups 1 and 1.2 may be treated conservatively (careful enucleation), whereas Subgroups 1.2.3 and 1.3 should be treated aggressively [11]. The histological typing of the current case was 1.2 and hence, the lesion was treated conservatively with careful enucleation. The recurrence rate for UAs after conservative surgical treatment (curettage or enucleation) is generally reported to be 10–20% [11] and on average, less than 25% [10]. This is considerably less than 50–90% recurrence rates which are noted after the curettage of conventional solid or multicysticameloblastomas [11, 21]. Lau and Samman reported recurrence rates of 3.6% for resection, 30.5% for enucleation alone, 16% for enucleation followed by Carnoy's solution application, and 18% by marsupialisation followed by enucleation (where the lesion is reduced in size) [22].

Whatever surgical approach the surgeon decides to take, long-term followup is mandatory as recurrence of unicysticameloblastoma may be long delayed. The case was followed for 9 months; there was no recurrence noted till now (Figures 10 and 11)

## Conclusion

The diagnosis of unicysticameloblastoma was based on clinical, radiological, histopathologic, and CT features. It is a tumor with a strong propensity of recurrence, especially when the ameloblastic focus penetrates the adjacent tissue from the wall of the cyst. Radiographically, most of ameloblastomas show multilocularity, whereas unicysticameloblastomas show a single large unilocular radiolucency. Very rarely, we come across a case with presentation of both multilocular and unicystic type in the same person crossing midline. Unicystic variant of ameloblastoma with aggressive histologic behaviour also might be successfully treated with marsupialisation with subsequent enucleation, and this approach can be considered as an alternative to resection.

## References

- [1]. Philipsen HP, Reichart PA. Unicysticameloblastoma. A review of 193 cases from the literature. *Oral Oncol.* 1998 Sep;34(5):317-25. Pubmed PMID: 9861335.
- [2]. Ackermann GL, Altini M, Shear M. The unicysticameloblastoma: a clinicopathological study of 57 cases. *J Oral Pathol Med.* 1988 Nov;17(9-10):541-6.
- [3]. Reichart PA, Philipsen HP. *Odontogenic tumors and allied lesions.* London: Quintessence; 2004 Jan.
- [4]. Eversole LR, Leider AS, Strub D. Radiographic characteristics of cystogenicameloblastoma. *Oral Surg Oral Med Oral Pathol.* 1984 May;57(5):572-7. Pubmed PMID: 6587306.
- [5]. Li TJ, Wu YT, Yu SF, Yu GY. Unicysticameloblastoma: a clinicopathologic study of 33 Chinese patients. *Am J SurgPathol.* 2000 Oct;24(10):1385-92. Pubmed PMID: 11023100.
- [6]. S. C. White and M. J. Pharoah, *Oral Radiology: Principles and Interpretation,* Mosby, St. Louis, Mo, USA, 5th edition, 2004.
- [7]. R. P. Langlais, O. E. Langland, and C. J. Nortje, *MultilocularRadiolucencies, Chapter-3, Diagnostic Imaging of Jaws,* Williams & Wilkins, 1995.
- [8]. R. Rajendran and B. Sivapathasundharam, *Shafer's Textbook of Oral Pathology,* Elsevier, New Delhi, India, 5th edition, 2006.
- [9]. Kiran Kumar KR, George GB, Padiyath S, Rupak S, KUMAR KUMAR KR, GEORGE G, et al. Mural unicysticameloblastoma crossing the midline: a rare case report. *Int. J. Odontostomat.* 2012;6(1):97-103.
- [10]. Gardner DG, Corio RL. Plexiformunicysticameloblastoma. A variant of ameloblastoma with a low-recurrence rate after enucleation. *Cancer.* 1984 Apr 15;53(8):1730-5. Pubmed PMID: 6697311.
- [11]. B. W. Neville, D. D. Damm, C. M. Allen, and J. E. Bouquot, "Odontogenic cysts and tumors," in *Oral and Maxillofacial Pathology,* pp. 610–618, W. B. Saunders, St. Louis, Mo, USA, 2nd edition, 2002.
- [12]. Roos RE, Raubenheimer EJ, van Heerden WF. Clinico-pathological study of 30 unicysticameloblastomas. *J Dent Assoc S Afr.* 1994 Nov;49(11):559-62. Pubmed PMID: 9508960.
- [13]. A. Peter, P. A. Reichart, and H. P. Philipsen, "Unicysticameloblastoma," in *Odontogenic Tumors and Allied Lesions,* pp. 77–86, Quintessence, London, UK, 2004, editorial and consensus conference held in Lyon, France (WHO,IARD) in July 2003 in conjunction with preparation of new WHO Blue Book, Pathology and genetics of tumors of head and neck.
- [14]. Paikatt VJ, Sreedharan S, Kannan VP. Unicysticameloblastoma of the maxilla: a case report. *J Indian SocPedodPrev Dent.* 2007 Apr 1;25(2):106-110.
- [15]. Braunshtein E, Vered M, Taicher S, Buchner A. Clear cell odontogenic carcinoma and clear cell ameloblastoma: a single clinicopathologic entity? A new case and comparative analysis of the literature. *J Oral Maxillofac Surg.* 2003 Sep;61(9):1004-10. Pubmed PMID: 12966474.
- [16]. Philipsen HP, Reichart PA. Classification of odontogenic tumors and allied lesions. *Odontogenic tumors and allied lesions Quintessence Pub. Co. Ltd.* 2004;21(3).
- [17]. Robinson L, Martinez MG. Unicysticameloblastoma: a prognostically distinct entity. *Cancer.* 1977 Nov;40(5):2278-85. Pubmed PMID: 922668.
- [18]. Leider AS, Eversole LR, Barkin ME. Cystic ameloblastoma: a clinicopathologic analysis. *Oral Surg Oral Med Oral Pathol.* 1985 Dec 1;60(6):624-30.
- [19]. Li TJ, Browne RM, Matthews JB. Expression of proliferating cell nuclear antigen (PCNA) and Ki-67 in unicysticameloblastoma. *Histopathology.* 1995 Mar;26(3):219-28.
- [20]. Konouchi H, Asaumi J, Yanagi Y, Hisatomi M, Kawai N, Matsuzaki H, et al. Usefulness of contrast enhanced-MRI in the diagnosis of unicysticameloblastoma. *Oral Oncol.* 2006 May;42(5):481-6. Pubmed PMID: 16488178.
- [21]. Ameerally B, McGurk M, Shaheen O. Atypical ameloblastoma: report of 3 cases and a review of the literature. *Br J Oral Maxillofac Surg.* 1996 Jun;34(3):235-9. Pubmed PMID: 8818257.
- [22]. Lau SL, Samman N. Recurrence related to treatment modalities of unicysticameloblastoma: a systematic review. *Int J Oral Maxillofac Surg.* 2006 Aug;35(8):681-90. Pubmed PMID: 16782308.