

Comparison Of Three-Dimensional Anchorage Loss In En-Masse Retraction And Two Step Retraction During Orthodontic Treatment- A Cephalometric Study.

Research Article

Pratham Shetty¹, Mukul shetty^{2*}, Roopak D Naik³¹ Department of orthodontics, AJ Institute of Dental Science, Mangalore, India² Department of orthodontics, AB Shetty Memorial Institute of Dental Science, Nitte(Deemed to be university), Deralakatte, India.³ Department of orthodontics, SDM college of Dental sciences and Hospital, A constituent unit of Shree Dharmasthala Manjunatheswara University, Dharwad, India.

Abstract

Objectives: The purpose of this study was to compare the anchorage loss in three dimensions during en-masse and two-step retraction during space closure in orthodontic treatment.

Materials And Methods: Pre and post-treatment radiographs of 64 critical anchorage cases were taken. Samples were divided equally into two groups. Group 1: en-masse retraction and group 2: two-step retraction. In group 1 (n=32), the anterior teeth were retracted using sliding mechanics. In group 2 (n=32), canines were distalized first on a round wire using NiTi coil spring following which the remaining incisors were retracted on a rectangular wire. A lateral cephalogram was used to measure anchorage loss in sagittal and vertical dimensions. Postero-anterior cephalogram was used to measure the anchorage loss in the transverse dimension. Tracing was superimposed and anchorage loss measured using McNamara's analysis and Grummon's analysis.

Results: Anchorage loss was seen in all three planes in both the retraction groups. In en-masse retraction, anchorage loss was significant in sagittal and vertical dimensions when compared with two-step retraction. In the transverse dimension, the anchorage loss was not significant.

Conclusion: In critical anchorage cases, two-step retraction is better than en-masse retraction in preserving the anchorage in all three dimensions.

Keywords: Anchorage Loss; En-Masse Retraction; Two-Step Retraction; Space Closure.

Introduction

Anchorage control is an important factor in successful orthodontic treatment. It plays a pivotal role in the effective management of space obtained by extraction of teeth for correcting severe crowding, excessive overjet and bimaxillary protrusion. A certain degree of anchorage loss is seen during space closure irrespective of the mechanics used. Salzmann stated that regardless of the skill one may possess in the mechanics of space closure following the extraction of the teeth, the teeth in the posterior buccal segment will be displaced mesially to some extent[1].

Anchorage loss (AL) is a potential side effect of orthodontic mechanotherapy. In simple terms, anchorage loss can be defined

as the amount of mesial movement of the posterior segment during premolar extraction space closure[2]. Anchorage loss can occur in all three planes of space i.e. sagittal plane, vertical plane and transverse plane. Anchorage loss in sagittal plane occurs because of mesial movement of molars and proclination of anteriors. Extrusion of molars and anteriors causes anchorage loss in the vertical plane, whereas in the transverse plane, anchorage loss occurs because of buccal flaring or lingual dumping of the posterior segment.

Most of the orthodontic cases require extraction of 1st premolars, to create space, for the successful correction of the malocclusion. Closure of extraction space becomes an important stage of orthodontic mechanotherapy especially in maximum anchorage cases where more than 75% of the extraction space is utilized for

*Corresponding Author:

Mukul Shetty,

Department of orthodontics, AB Shetty Memorial Institute of Dental Science, Nitte(Deemed to be university), Deralakatte, India.

Tel : 91-9900414358

E-mail: mukulshetty28@gmail.com.

Received: May 04, 2021**Accepted:** July 09, 2021**Published:** July 18, 2021

Citation: Pratham Shetty, Mukul shetty, Roopak D Naik. Comparison Of Three-Dimensional Anchorage Loss In En-Masse Retraction And Two Step Retraction During Orthodontic Treatment- A Cephalometric Study. *Int J Dentistry Oral Sci.* 2021;8(7):3362-3367. doi: <http://dx.doi.org/10.19070/2377-8075-21000683>

Copyright: Mukul Shetty©2021. This is an open-access article distributed under the terms of the Creative Commons Attribution License, which permits unrestricted use, distribution and reproduction in any medium, provided the original author and source are credited.

anterior retraction.

Various retraction techniques have been designed to effectively utilize the extraction space. Retraction techniques can be broadly classified into en-masse and two-step retraction techniques. Usually, en-masse retraction is the choice of retraction in which all the anterior teeth are retracted together to close the extraction space. Whereas in maximum anchorage cases “two-step” technique is preferred[3-5]. Here the canines are retracted first followed by the incisors to close the extraction space. However, any force acting on the anchorage unit would result in a certain degree of unwanted movement of the anchor teeth.

Most of the studies evaluate anchorage loss in sagittal dimension only. Vertical and transverse dimensions have not been considered. Vertical changes occurring in the molar region during treatment do, however, influence the skeletal relationship significantly. Also, sagittal anchorage loss hardly ever occurs without an extrusional component[6]. Changes in transverse dimension result in palatal hanging cusp and undesirable arch expansion. This causes poor settling of occlusion and also influences the skeletal relation.

Available literature does not provide adequate evidence on three-dimensional anchorage losses in various retraction methods. Hence, there is a need to assess the anchorage loss in these three dimensions. The purpose of this study is to compare anchorage loss in all three planes of space during en-masse and two-step retractions. Also, to derive a clinical implication regarding which technique will be useful for clinician/orthodontist in choosing appropriate treatment mechanics for space closure.

Materials And Methods

This prospective study was conducted after getting approval from the Institutional Review Board (IRB) and Ethical Committee (IRB. No. 2017/P/OR/20). Randomization was done using a simple randomization technique to ensure a 1:1 allocation ratio in both groups. The name of the groups “En-masse” and “two-step retraction” was written on 64 pieces of paper and was placed inside identical looking envelopes. They were then sealed and placed in a box. The envelopes were shuffled inside the box, and each patient was told to pick one envelope from the box. The patient was then assigned to the designated group. Informed consent was attained from the patient before the start of this study. This study included 64 patients, ages ranging from 17-19 years.

Subjects were randomized to 2 treatment techniques: en-masse retraction (n=32) and two-step retraction (n=32).

Inclusion Criteria

1. No previous history of orthodontic treatment.
2. A full complement of permanent teeth.
3. Patients with skeletal class II with normo divergent growth pattern.
4. Critical anchorage with first premolar extraction.
5. Maxillary arch anchorage was reinforced using transpalatal arch.
6. All the patients were treated with preadjusted edgewise appliance.

Exclusion Criteria

1. Patient with congenitally missing teeth, teeth missing due to previous extractions or impacted teeth.
2. Developmental deformities.
3. Periodontally compromised teeth.
4. Asymmetric extraction.

The subjects for both techniques were treated with pre-adjusted edgewise appliances (MBT prescription, 0.022 X 0.028-in bracket slot, 3M Unitek, Monrovia, Calif).The selected subjects were exposed to radiographic examination after placing K-separators. K separators made of 0.018 SS were separators were placed to help in identifying the first maxillary molars of both sides of dental arch more accurately. Following which lateral cephalogram and posterior-anterior cephalogram were made using standard protocols. First maxillary molars were traced for both sides and mean was taken for assessment of sagittal and vertical anchorage loss (in mm). Digital lateral cephalogram and postero-anterior cephalogram were made at two intervals following the standard protocols i.e; T0-pre-treatment and T1-end of space closure. Lateral cephalogram was made to measure anchorage loss in sagittal and vertical dimensions while the anchorage loss in transverse dimensions was measured using posterior-anterior cephalogram.

In the en-masse sample, the 6 anterior teeth were retracted as a single unit to close the extraction space sliding mechanics(Figure 1). While, in the two-step sample, the canines were retracted first by closed coil NiTi springs, 9mm in length (Libral Traders Pvt Ltd) from the molar hook onto the canine hooks bilaterally after calibrating the force to 150gms using a CORREX gauge until they contacted the second premolars(Figure 2).The 4 incisors were

Figure 1. En-masse retraction with sliding mechanics.

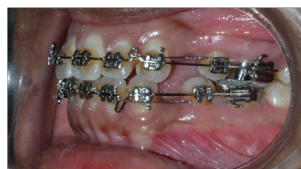
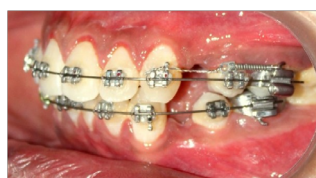


Figure 2. Canine retraction in 2 step retraction mechanics.



then retracted by using sliding mechanics. TPA was used in both groups to augment the anchorage.

Cephalometric Assessment

Radiographs of all the selected subjects were taken in the Natural Head Position (NHP) using KODAK 9000 EXTRAORAL IMAGING machine. The radiographic films were exposed at 80 KV/8mA for 0.8 seconds. The lateral cephalograms were made under standardized conditions with the Frankfort horizontal plane kept parallel to the floor and the mid-facial plane kept in a vertical position[7].

For postero-anterior cephalogram, the film to source distance was standardized to 5 feet and the distance between the film and the patient was 6 inches. The head position was carefully checked so that the Frankfurt horizontal dimension was kept parallel to the floor.

The hard tissue landmarks and reference planes were taken as defined by Alexander Jacobson and Thomas Rakosi[8-9].

Following landmarks and plane were used on lateral cephalogram(Figure 3).

ANS- anterior nasal spine- anterior most point on the palatine bone

PNS- posterior nasal spine- posterior most point on the palatine bone

ANS-PNS plane- a line joining the ANS and PNS points

Following landmarks and planes were used on postero anterior cephalogram(Figure 4).

The hard tissue landmarks and reference planes were taken as defined by Wei, Ricketts, Athanasiou, Grummons and Kappeyene.

1. Cg - Crista galli.
2. ANS- Anterior Nasal Spine.
3. Midsagittal reference dimension- Line passing from Crista Galli through the anterior nasal spine to the chin area.

4. Um, upper molar- The most prominent lateral point on the buccal surface of the first (right and left) permanent maxillary molar.

Measurement Procedure

McNamara's superimposition techniques were used to quantify and compare anchor loss in sagittal and vertical dimensions in lateral cephalogram[10] and Grummons analysis was used to evaluate anchorage loss in transverse dimensions on a postero-anterior cephalogram[11].

Procedure For Measuring Sagittal And Vertical Anchorage Loss

Landmarks identified on the lateral cephalogram of both pre-treatment and end of space closure stage were traced on the acetate tracing paper. The tracing was then transferred onto a plain sheet of paper on which McNamara's superimposition technique was performed. The maxillary molar was superimposed on ANS-PNS (palatal) plane at ANS on pre-treatment and end of space closure tracings. The mesial displacement of the maxillary first molar, at the mesial surface, was compared in pre-treatment and end of space closure radiographic tracing. The difference measured (in millimeters) using Mitotoyu digital caliper (Mitotoyu, Japan) was the anchorage loss in sagittal dimension.

To measure the anchorage loss in vertical dimension (extrusion), a perpendicular was dropped from the ANS-PNS plane to the tip of the mesio-buccal cusp of the maxillary first molar. Pre-treatment and end of space closure radiographic tracing were superimposed on the ANS-PNS plane at the perpendicular on a plain sheet of paper. Extrusion of the molar was measured using Mitotoyu digital caliper (Mitotoyu Japan) on the tracing. The difference was evaluated as anchorage loss in the vertical dimension.

Procedure For Measuring Transverse Anchorage Loss

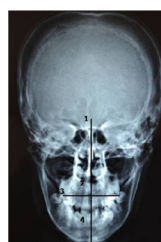
To measure the anchorage loss in the transverse dimension postero-anterior cephalogram was used. Following the landmark iden

Figure 3. Landmarks and plane were used on lateral cephalogram.
1.ANS- Anterior Nasal Spine, 2. PNS- Posterior Nasal Spine, 3. ANS-PNS plane.

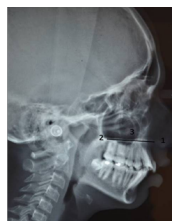

Figure 4. Landmarks and planes were used on postero anterior cephalogram.

1. CG- Crista galli, 2. ANS- Anterior Nasal Spine, 3. Um- buccal surface of the upper 1st molar, 4. Mid sagittal reference dimension.



tification, the tracing was transferred onto a white sheet of paper on which Grummon's analysis was performed. Distance from the buccal surface of the maxillary first molar to the mid sagittal reference plane was measured using Mitotoyu digital caliper bilaterally, in both pre-treatment and end of space closure radiographs. An expansion that occurs at the end of space closure was considered as the anchorage loss in the transverse dimension.

Statistical Analysis

The collected data was entered into the computer (MS-Office, Excel 2010) and subjected to statistical analysis using the statistical package- SPSS version 20. Not normal distribution was determined by Kolmogorov-Smirnov and Shapiro-Wilk test. To verify whether there was any statistically significant difference in the en-masse and two-step retraction techniques Mann Whitney U test and Wilcoxon test were performed. Statistical differences were determined at the 95% confidence level ($P < 0.05$).

Results

This study included a total of 64 subjects with 34 males and 30 females with a mean age of 18.45 -19.71 years. Molar displacement was seen in all three planes of space. The measurements were made using Mitotoyu digital caliper. Mesial displacement of the molar (sagittal anchorage loss) was seen in both en-masse and two-step retraction groups. Extrusion of the molar (vertical anchorage loss) was seen in both groups. Buccal flaring of the molar (transverse anchorage loss) was seen in both groups.

Anchorage loss was observed in all three planes in patients treated

with both en-masse retraction and two-step retraction. The mean and standard deviation were calculated for the anchorage loss in all three planes for both groups.(Table 1).Table 2 compares the significance of anchorage loss in the en-masse group and two-step retraction groups.

Discussion

Anchorage loss (AL) is the amount of mesial movement of the first permanent molar during premolar extraction space closure. Anchorage loss can express itself in all three planes. It can manifest as a mesial migration of the molars, proclination of incisors, extrusion of posteriors, or buccal flaring of posteriors.

Kuhlberg conducted a study to compare the efficiency of en masse retraction and two step retraction techniques and he found that separate canine retraction was less taxing the anchor unit[5]. The results were similar to that of Roth[4],Profitt and Fields[3]. They suggested two-step retraction technique is better than the en-masse retraction technique to treat the maximum anchorage requirement case. Contrary to this, Tian-Min Xu et al[12], and HeoW, Nahm DS, Baek Sfound no difference between the two techniques with respect to the mesial movement of the anchorage teeth in critical anchorage cases[13]. Also, when canines are retracted individually, they tend to tip and rotate more than when the anterior teeth are retracted as a single unit, thus requiring additional time and effort to re-level and realign. Many other studies questioned the advantage of two-step retraction over en-masse retraction[14-15].

In the present study, anchorage loss in the sagittal plane, trans-

Table 1: The mean and standard deviation of the anchorage loss.

	Mean		Standard deviation	
	Group 1	Group 2	Group 1	Group 2
	(n=32)	(n=32)	(n=32)	(n=32)
Sagittal	2.358	2.216	0.144	0.185
Vertical	0.733	0.658	0.088	0.066
Transverse	0.983	0.966	0.164	0.143

Group 1-en-masse retraction,
Group 2- two step retraction.

Table 2. Comparison of anchorage loss in en-masse group and two-step retraction group using Mann-Whitney U and Wilcoxon test.

	Group	N	Mean Rank	Sum of Ranks	Mann-Whitney U	Wilcoxon W	p value
Sagittal	1	12	15.38	184.5	37.5	115.5	0.045*
	2	12	9.63	115.5			
Vertical	1	12	15.38	184.5	37.5	115.5	0.045*
	2	12	9.63	115.5			
Transverse	1	12	14.96	179.5	42.5	120.5	0.079
	2	12	10.04	120.5			

Group 1: en-masse retraction group,
Group 2: two step retraction group, N: sample size. p value < 0.05 - Significant (significant at 95% CI).

verse plane and vertical plane was measured using two different retraction techniques commonly used in orthodontics, viz., en-masse retraction and two-step retraction.

Patients treated with both en-masse retraction and two-step retraction techniques showed anchorage loss in sagittal direction. The class I force used to retract the maxillary anterior teeth resulted in mesialization of the maxillary first molars in both the retraction groups causing burning of anchorage. The anchorage provided by teeth depends on the size of the teeth, ie the root surface area of the teeth. The combined root surface area of the anterior teeth is almost the same as the 1st molar and 2nd premolar. Attempting to move all the anterior teeth distally simultaneously will result in an equal mesial movement of the posterior teeth [16]. The more teeth that are incorporated into an anchorage unit the less likely unwanted tooth movement will occur.

In en-masse retraction, the anterior segment comprising of canine and incisors are retracted by taking anchorage from the maxillary second premolar and the first molar. A force of about 350 gms was used for retraction. The number of teeth forming the anchorage unit is less. During retraction heavy forces are used to distalize the six anterior teeth. Inevitably the reciprocal force acting on the posterior teeth will also be high which causes mesialization of the anchorage unit. But in two-step retraction, the canine is retracted first until it contacts the second premolar. One anterior tooth is being retracted against two posterior teeth. Also, the force used to retract canine is low (150gms) and so will be the reactionary forces acting on the posterior teeth, hence, the anchorage loss is negligible following canine retraction. Canine is consolidated with the remaining posterior teeth forming a bigger anchorage unit. Following this the remaining incisors are retracted using sliding mechanics. As there is an increase in the number of teeth in the anchorage unit it disperses the load over a greater surface thereby decreasing the strain or distortion of the periodontal structures within the anchorage unit [17]. So the force acting per unit area of the anchorage unit is less than the threshold force required for tooth movement. Hence, the anchorage loss in two-step retraction was less as compared to en-masse retraction group. The anchorage loss, in sagittal dimension, in en-masse group as compared with that of the two-step retraction group at the end of space closure was significantly higher.

Anchorage loss was also seen in the vertical plane in both groups. But the anchorage loss in the en-masse group was statistically significant when compared with that of the two-step retraction group. (Table 2)(pvalue =0.045). To correct the deep bite condition, brackets in the anterior segment were bonded incisally. In an attempt to intrude the anterior teeth, the reciprocal force acts on the posterior teeth resulting in extrusion. The extrusion is a more commonly seen phenomenon than intrusion as intrusion requires the application of light controlled forces along the long axis of the teeth. This is hard to achieve in continuous archwire mechanics. If intrusion of one tooth is pitted against the extrusion of the other tooth then, extrusion will dominate [18].

Sagittal anchorage loss is always accompanied by some amount of extrusion of the molars. The changes seen in the vertical plane helps in maintaining the mandibular plane angle in cases where there is more sagittal movement of the molars. The change in the vertical plane is also attributed to the oro-facial musculature of the patients. The occlusal forces may neutralize the extrusive

forces produced by the orthodontic appliance.

On measuring anchorage loss in the transverse dimension there was some amount of buccal flaring of the molars seen in both the retraction techniques. But, the difference was not significant. The preformed NiTi wire used in the initial stages of leveling and aligning of the teeth is usually wider than the arch width. Also, the curve of wasp in the wire used in order to open the bite and level the maxillary creates a moment at the buccal tube of the molars which results in buccal flaring. These could be possible reasons for changes in transverse dimension seen in both the retraction groups. But on statistical analysis, it was found that the change in transverse dimension was not significant. The results showed that the anchorage loss in en-masse retraction was statistically significant (p-value = 0.045) as compared with two-step retraction.

Conclusion

The results of the present study show that there was anchorage loss in the sagittal dimension and vertical dimension in both the retraction groups. But it was significantly higher in the en-masse retraction group when compared with the two-step retraction group. This is attributed to the number of teeth in the anchorage unit which is higher in the two-step retraction group when compared with the en-masse retraction group. The anchorage loss in the transverse dimension was similar for both groups.

References

- [1]. Salzman JA. Principles of orthodontics. 2nd ed. Philadelphia: Lippincott; 1966.
- [2]. Geron S, Shpack N, Kandos S, Davidovitch M, Vardimon AD. Anchorage loss—a multifactorial response. *Angle Orthod.* 2003 Dec;73(6):730-7. Pubmed PMID: 14719740.
- [3]. Proffit WR, Fields HW. The second stage of comprehensive treatment: correction of molar relationship and space closure. *Contemporary orthodontics.* 3rd ed. St Louis: Mosby; 2000:552-75.
- [4]. Roth RH. Treatment mechanics for the straight wire appliance. In: Graber TM, Vanarsdall RL, editors. *Orthodontics, current principles and techniques.* 2nd ed. St Louis: Mosby; 1994. p. 685-711.
- [5]. Kuhlberg AJ. Steps in orthodontic treatment. In: Bishara SE, editor. *Textbook of orthodontics.* Philadelphia: W. B. Saunders; 2001. p. 240-242.
- [6]. Melsen B, Bosch C. Different approaches to anchorage: a survey and an evaluation. *Angle Orthod.* 1997;67(1):23-30. Pubmed PMID: 9046396.
- [7]. Lundström A, Lundström F. The Frankfort horizontal as a basis for cephalometric analysis. *Am J OrthodDentofacialOrthop.* 1995 May 1;107(5):537-40.
- [8]. Jacobson A. *Radiographic cephalometry: from basics to video imaging* Carol Stream Quintessence; 1st ed. CHICAGO. 1995
- [9]. Rakosi T. *An atlas and manual of cephalometric radiography.* 1st ed. London: Wolfe Medical; 1982: 35-42.
- [10]. McNamara Jr JA. A method of cephalometric evaluation. *Am J OrthodDentofacialOrthop.* 1984 Dec 1;86(6):449-69.
- [11]. Grummons DC. A frontal asymmetry analysis. *J. Clin. Orthodont.* 1987 Jul; 21(7):448-65.
- [12]. Xu TM, Zhang X, Oh HS, Boyd RL, Korn EL, Baumrind S. Randomized clinical trial comparing control of maxillary anchorage with 2 retraction techniques. *Am J OrthodDentofacialOrthop.* 2010 Nov 1;138(5):544.e1-544.e9.
- [13]. Heo W, Nahm DS, Baek SH. En Masse retraction and two-step retraction of maxillary anterior teeth in Nov Class I women. *Am J OrthodDentofacialOrthop.* 2007 Nov;77(6):973-8. Pubmed PMID: 18004930.
- [14]. Staggers JA, Germane N. Clinical considerations in the use of retraction mechanics. *J ClinOrthod.* 1991 Jun;25(6):364-9.
- [15]. Rizk MZ, Mohammed H, Ismael O, Bearn DR. Effectiveness of en masse versus two-step retraction: a systematic review and meta-analysis. *ProgOrthod.* 2018 Jan 5; 18(1): 41.
- [16]. Yee JA, Türk T, Elekdag-Türk S, Cheng LL, Darendeliler MA. Rate of tooth movement under heavy and light continuous orthodontic forces. *Am J OrthodDentofacialOrthop.* 2007 Nov;132(5):544-50.

thodDentofacOrthop. 2009 Aug 1;136(2):150.e1-e9.

- [17]. Steven J. Lindauer. The basics of orthodontic mechanics. *SeminOrthod.* 2001 MARCH; 7(1):2-15.
- [18]. Wu J, Liu Y, Wang D, Zhang J, Dong X, Jiang X, et al. Investigation of effective intrusion and extrusion force for maxillary canine using finite element analysis. *Comput Methods Biomech Biomed Engin.* 2019 Dec;22(16):1294-1302. Pubmed PMID: 31553278.