

A Comparative Evaluation Of The Apical Foraminal Deformation Caused By Three Rotary File Systems: An In Vitro Study

Research Article

Krishna Doshi¹, S. Delphine Priscilla Antony², Pradeep Solete^{3*}

¹ Department of Conservative Dentistry and Endodontics, Saveetha Dental College, Saveetha Institute of Medical and Technical Sciences, Saveetha University, Chennai - 600077, India.

² Senior Lecturer, Department of Conservative Dentistry and Endodontics, Saveetha Dental College, Saveetha Institute of Medical and Technical Sciences, Saveetha University, Chennai- 600077, India.

³ Reader, Department of Conservative Dentistry and Endodontics, Saveetha Dental College and Hospitals, Saveetha Institute of Medical and Technical Sciences, Saveetha University, Chennai- 600077, India.

Abstract

Background: Apical foramen enlargement is considered beneficial during endodontic treatment of necrotic teeth. However, this causes deformation and deviation of the apical foramen which may lead to faulty obturations, sealer extrusion, etc.

Aim: To compare the apical foramen deformation caused by Protaper Gold, ProFit S3, and Hyflex CM rotary file systems in mandibular molars.

Materials and Methods: Thirty mesial root canals in fifteen extracted mandibular molars were included in the study. Access cavities were prepared, WL was established at the apical foramen. The canals were divided into 3 groups (n=10) : Group 1 - Protaper Gold (PTG); Group 2 - ProFit S3 (PS3); Group 3 - Hyflex CM (HCM). Instrumentation was done up to file size #25/0.06. Pre and post instrumentation AF areas (A0, A1) were assessed using a stereomicroscope at 100X magnification. Foraminal deformation was calculated for each canal by subtracting A1-A0. Statistical analysis was done using ANOVA and posthoc Tukey tests.

Results: Apical foraminal deformation was present in all samples. The mean area of apical foramen, postoperatively, was 0.01804mm for Protaper Gold, 0.01046mm for ProFit S3 and 0.01476mm for Hyflex CM systems. ProFit S3 system showed the least AF deformation compared to Protaper Gold and Hyflex CM systems.

Conclusion: ProFit S3 system showed the least foraminal deformation compared to the Protaper Gold and Hyflex CM systems. The alloy, taper, and cross-section of the file may play an important role in the degree of deformation produced.

Keywords: Apical Deformation; Foraminal Deformation; Protaper Gold; ProFit S3; Hyflex CM; Stereomicroscope.

Introduction

The primary goal of endodontic treatment is to obtain adequate disinfection of the root canal space in order to prevent recurrence of apical periodontitis [1, 2]. This involves chemo-mechanical preparation of the root canals followed by a three-dimensional root canal filling. An important step in this process is determining the working length of the canal. According to the endodontic glossary, 'Working length' is defined as the distance from a stable coronal reference point to the point at which root canal preparation and obturation must terminate [3]. Numerous authors have

discussed their opinions on this subject and have come to conclusions as to what must be the ideal working length. Ingle (1973) stated that the WL must be 0.5mm short of the external root surface; Weine (1982) stated that it must be 1mm short of the radiographic apex; Guldener (1985) stated that for necrotic teeth it must be 0.5mm short of the tooth length while it should be 1mm short for vital teeth; Frank (1988) stated that it must be 0.5-1mm short of the apex; etc [4]. Langeland et al [5] stated that root canal preparation and obturation must end at the apical constriction irrespective of the vitality of the tooth. On the other hand, some authors advocated penetration of the foramen to or beyond

*Corresponding Author:

Pradeep Solete,
Reader, Department of Conservative Dentistry and Endodontics, Saveetha Dental College and Hospitals, Saveetha Institute of Medical and Technical Sciences, Saveetha University, Chennai- 600077, India.
E-mail: pandu.pradeep@gmail.com

Received: May 05, 2021

Accepted: June 20, 2021

Published: June 28, 2021

Citation: Krishna Doshi, S. Delphine Priscilla Antony, Pradeep Solete. A Comparative Evaluation Of The Apical Foraminal Deformation Caused By Three Rotary File Systems: An In Vitro Study. *Int J Dentistry Oral Sci.* 2021;8(6):2865-2869. doi: <http://dx.doi.org/10.19070/2377-8075-21000558>

Copyright: Pradeep Solete®2021. This is an open-access article distributed under the terms of the Creative Commons Attribution License, which permits unrestricted use, distribution and reproduction in any medium, provided the original author and source are credited.

the radiographic apex. Schilder et al [6] declared his aim was to debride and fill up to the apex, as well as fill the lateral canals and apical ramifications.

In cases of apical periodontitis especially in necrotic teeth, recognizing the presence of microorganisms in the apical portion of the canal has contributed to the acceptance of larger apical preparations [7, 8] and cleaning, debridement, and enlargement of the apical foramen [9] during root canal instrumentation since it can overcome the potential limits of irrigation in the apical area, optimizing root canal disinfection [10, 11]. Achieving a larger apical diameter during foraminal enlargement, however, might lead to apical transportation. This transportation of the apical foramen can lead to complications in subsequent cleaning and filling procedures [12].

With the advent of nickel-titanium instruments in endodontics, root canal preparations have become easier and more predictable. Nickel-titanium files are known for their elasticity and resistance to torsional fatigue when compared to hand stainless steel files [13]. Several types of thermal treatments have been developed with the aim of optimizing the mechanical properties of NiTi alloy [14, 15]. Some of them include M wire technology, R-phase, controlled memory, gold files, blue files, etc. They are known to have better flexibility, fracture resistance, resistance to cyclic fatigue, etc.

Protaper Gold is a heat-treated file with advanced metallurgy and a progressively tapered design. Hyflex CM is manufactured based on the controlled memory technology and is claimed to be highly flexible. ProFit S3 (PS3) is a new endodontic file system manufactured using new heat-treated technology and having a titanium oxide coating.

Mesial root canals of mandibular first molars are reported to be curved both in buccolingual and mesiodistal directions [16]. Maintaining a centered preparation with minimal apical deformation is difficult and hence these teeth are more prone to ledging and canal transportations.

Since no previous study has compared the apical foramen deformation caused by these three rotary systems, the aim of this study was to compare and evaluate the apical foramen deformation caused by Protaper Gold, Profit S3, and Hyflex CM rotary file systems in mandibular molars.

Previously our team has a rich experience in working on various research projects across multiple disciplines [17-31] Now the growing trend in this area motivated us to pursue this project.

Materials And Methods

Thirty mesial root canals in Vertucci's Type IV configuration in fifteen extracted mandibular molars with fully developed roots were included in the study. The teeth exhibited no defects, their root canals were not calcified, showed no internal or external root resorption, no prosthetic crowns or dental posts, no signs of prior endodontic treatment, and no aberrant canal morphology. Only teeth with apical curvature between 20 and 40 degrees were included. Preoperative stereomicroscopic images were taken at 100X magnification and the apical foramen dimensions were

assessed (A0).

Access cavities were prepared using Endo Access bur, 21 mm size 2 (Dentsply Maillefer, Swiss made) and K-file (Mani, Utsunomiya, Tochigi, Japan) of size #10 hand files were used to achieve the initial patency of the canal to full working length (WL), visible at the apical foramen, and the WL was established at this length. The canals were randomly divided into 3 groups (n=10): Group 1 - Protaper Gold (PTG); Group 2 - ProFit S3 (PS3); Group 3 - Hyflex CM (HCM). Instrumentation was done using the file systems of the respective groups up to file size #25/0.06. Postoperative assessment of the apical foramen dimensions was done using the stereomicroscope (A1).

Apical foraminal deformation produced by instrumentation was calculated for each canal using the formula:

$$\text{Apical deformation} = A1 - A0$$

According to this formula, a result of '0' indicates no apical deformation.

The data were evaluated statistically using SPSS software (Version 23.0) by one-way analysis of variance (ANOVA) followed by the post hoc Tukey test to explore apical foraminal deformation in each group. The level of significance was set at 0.05.

Results And Discussion

Table 1 represents the mean preoperative as well as postoperative apical foramen areas for each group. The mean area of apical foramen, postoperatively, was 0.01804mm for Protaper Gold, 0.01046mm for Profit S3 and 0.01476mm for Hyflex CM systems. There was no significant difference between the preoperative AF areas. There was a significantly lower postoperative AF deformation after using Profit S3 compared to the Protaper Gold system. There was a significantly lower postoperative AF deformation after using Profit S3 compared to Hyflex CM system. Profit S3 system showed the least AF deformation compared to Protaper Gold and Hyflex CM systems.

Nickel-titanium rotary files have a number of advantages over the stainless steel hand files including good flexibility, improved fracture resistance, improved torsional and cyclic fatigue, increased speed of canal preparation, etc. Protaper Gold files were developed with advanced metallurgy and have a progressively tapered design that is claimed by the manufacturer to enhance cutting efficiency and safety. These files have a convex triangular cross-section and a progressive taper, hence the name 'Protaper'. The manufacturer claims that this property helps in navigating challenging curves in the apical region of the canal while giving a proper shape to the canal. The file also has a feature of a shorter handle for improved accessibility to the teeth [32].

'Hyflex CM' is a NiTi rotary file system made using the novel "controlled memory" technology. Controlled memory wire (CM wire) is manufactured by a unique process that controls the material's memory, making the files extremely flexible, but without the shape memory that is typical of other NiTi files. The file maintains the shape of the canal even after its removal. This prevents canal straightening and hence it is widely used in curved canals

Table 1. Representing the mean and standard deviation of the preoperative and postoperative apical foramen areas.

Groups		Pre-op Area (A0)	Post-op Area (A1)	Apical Deformation (A1-A0)
Protaper Gold	Mean	0.004	0.018	0.014
	SD	0.001	0.005	0.005
Profit S 3	Mean	0.004	0.010	0.006
	SD	0.001	0.004	0.002
Hyflex Cm	Mean	0.005	0.015	0.010
	SD	0.003	0.003	0.000

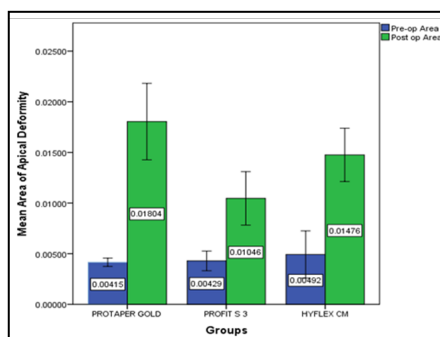
Table 2: Showing the inter-group comparisons of apical deformation. Statistically significant difference observed between PTG and PS3 as well as PS3 and HCM groups (p<0.05) by ANOVA and posthoc Tukey tests.

	(I) Groups	(J) Groups	Mean Difference (I-J)	Sig.
Pre-op Area	Protaper Gold	Profit S 3	-0.000	0.985
		Hyflex CM	-0.001	0.653
	Profit S 3	Protaper Gold	0.000	0.985
		Hyflex CM	-0.001	0.751
	Hyflex Cm	Protaper Gold	0.001	0.653
		Profit S 3	0.001	0.751
Post op Area	Protaper Gold	Profit S 3	.00758000*	.001*
		Hyflex CM	0.003	0.229
	Profit S 3	Protaper Gold	-.00758000*	.001*
		Hyflex CM	-0.004	.089*
	Hyflex Cm	Protaper Gold	-0.003	0.229
		Profit S 3	0.004	.089*

Figure 1: Demonstrating mandibular molar teeth used for the study.

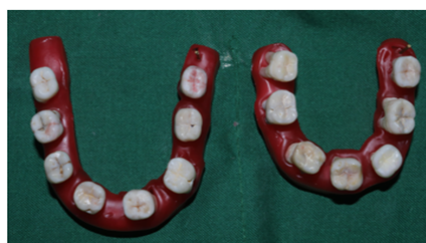

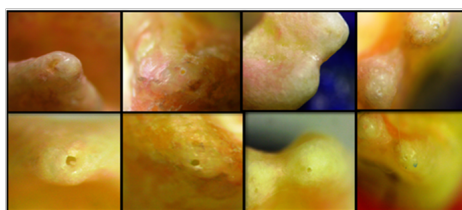
Figure 2. Representing a bar graph representing the mean apical area of deformity of the different groups pre and post instrumentation. Statistically significant difference observed between PTG and PS3 as well as PS3 and HCM groups (p<0.05).



[33].

ProFit S3 (PS3) is a new endodontic file system introduced in the year 2019. It is a blue file manufactured using new heat-treated technology. This rotary system has a titanium oxide coating and hence the blue color. It has a variable taper design, which varies

between 4% and 8%, with a rectangular cross-section. In cross-section, the file makes a two-point contact with the canal walls, thereby reducing the apical extrusion of debris. PS3 has good shape memory, flexibility, and increased resistance to fracture [34]. The cross-section of PTG files is convex triangular, PS3 is offset rectangular and Hyflex CM is double fluted. All the files have a

Figure 3: Showing the pre and post instrumentation stereomicroscopic images of the apical foramen.

non-cutting tip. The PS3 and PTG both have a variable taper and both are heat-treated file systems, the difference is that PTG has a sequence of instruments to be used and whereas PS3 is a single file system [34].

Apical enlargement and deformation post instrumentation may be clinically correlated with debris or irrigant extrusion and post operative pain experienced by the patient [35]. Hence foraminal enlargement must be kept to a minimum during instrumentation. In our study, PTG showed the highest apical deformation post instrumentation, followed by Hyflex CM and Profit S3. The higher apical deformation of the Protaper gold system may be due to its higher taper (8%) in the apical 3 mm. Also, Hyflex CM and Profit S3 have 2 point contact that reduces aggressiveness of file and hence apical foramen enlargement and deformation.

Our study was in agreement with previous studies that have proved that major apical foramen deformation is present when instrumentation is done upto the apex or beyond the apex [36-38]. A previous study done by Frota et al in 2017 assessed the apical foramen deformation that occurred during root canal preparation with different reciprocation systems: Reciproc, WaveOne (M-Wire), and ProDesign R (Shape Memory Technology Wire) at two different working lengths (WLs): 0.0 and 1.0 mm beyond the AF. they concluded that AF deformation was dependent on the alloy as well as the taper; and PDR showed the lowest AF deformation values at both WLs [39].

Another study by Silva Santos et al in 2018 compared the foraminal deformation caused by rotary and reciprocating motions using scanning electron microscope. They concluded that the kinematics did not play a role in the apical foramen deformation as both the motions caused similar deformation [36].

Gustavo et al concluded that manual stainless steel and mechanical NiTi patency maneuverers produced similar apical foramen deformation [40].

The results of the present study suggest that instrumentation at the apex promoted major apical foramen deformation in all three systems. The alloy, taper, and cross-section of the file may play an important role in the degree of deformation produced. However, findings of an in vitro study should be carefully evaluated before being clinically considered. Further studies evaluating the influence of foraminal enlargement on cleaning efficacy and root canal filling ability are suggested. Moreover, clinical studies are paramount to assess outcomes of treatments performed with instrumentation at or beyond the apex.

Our institution is passionate about high quality evidence based research and has excelled in various fields [21, 41-50].

Conclusion

Within the limitations of this study, it can be concluded that the Profit S3 system showed the least apical foramen deformation compared to the Protaper Gold and Hyflex CM systems. The alloy, taper, and cross-section of the file may play an important role in the degree of deformation produced. Further in vitro as well as clinical studies are recommended to assess the debris extrusion, micro-crack formation, cleaning efficacy and root canal filling ability as well as post-operative pain caused after instrumentation with these systems.

Acknowledgement And Declarations

The authors would like to acknowledge the institution and all the staff members of the Department of Conservative Dentistry and Endodontics for their support towards completion of this research. The authors deny any conflicts of interest associated with this paper.

References

- [1]. Ingle JI, Baumgartner JC. Ingle's endodontics 6. BC Decker; Maidenhead: McGraw-Hill Education [distributor]; 2008.
- [2]. Cohen S, Burns RC, Walton R, Torabienjad M. Pathways of the Pulp (1). Learning. 1998;30(10).
- [3]. Endodontists A. Glossary: Contemporary Terminology for Endodontics.
- [4]. Ricucci D. Apical limit of root canal instrumentation and obturation, part 1. Literature review. *Int Endod J*. 1998 Nov;31(6):384-93. Pubmed PMID: 15551606.
- [5]. Langeland K. The histopathologic basis in endodontic treatment. *Dent Clin North Am*. 1967 Nov;491-520. Pubmed PMID: 5262479.
- [6]. Schilder H. Filling root canals in three dimensions. 1967. *J Endod*. 2006 Apr;32(4):281-90. Pubmed PMID: 16554195.
- [7]. Goldberg F, Massone EJ. Patency file and apical transportation: an in vitro study. *J Endod*. 2002 Jul;28(7):510-1. Pubmed PMID: 12126377.
- [8]. Buchanan LS. Management of the curved root canal. *J Calif Dent Assoc*. 1989 Apr;17(4):18-25, 27. Pubmed PMID: 2481012.
- [9]. de Souza Filho FJ, Benatti O, de Almeida OP. Influence of the enlargement of the apical foramen in periapical repair of contaminated teeth of dog. *Oral Surg Oral Med Oral Pathol*. 1987 Oct;64(4):480-4. Pubmed PMID: 3477772.
- [10]. Card SJ, Sigurdsson A, Orstavik D, Trope M. The effectiveness of increased apical enlargement in reducing intracanal bacteria. *J Endod*. 2002 Nov;28(11):779-83. Pubmed PMID: 12470024.
- [11]. Fornari VJ, Silva-Sousa YT, Vanni JR, Pécora JD, Versiani MA, Sousa-Neto MD. Histological evaluation of the effectiveness of increased apical enlargement for cleaning the apical third of curved canals. *Int Endod J*. 2010 Nov;43(11):988-94. Pubmed PMID: 20722756.
- [12]. Weine FS, Kelly RF, Lio PJ. The effect of preparation procedures on original canal shape and on apical foramen shape. *J Endod*. 1975 Aug;1(8):255-62. Pubmed PMID: 10697472.
- [13]. Walia HM, Brantley WA, Gerstein H. An initial investigation of the bending and torsional properties of Nitinol root canal files. *J Endod*. 1988 Jul;14(7):346-51. Pubmed PMID: 3251996.
- [14]. Pereira ES, Peixoto IF, Viana AC, Oliveira II, Gonzalez BM, Bueno VT, et al. Physical and mechanical properties of a thermomechanically treated NiTi wire used in the manufacture of rotary endodontic instruments. *Int Endod J*. 2012 May;45(5):469-74. Pubmed PMID: 22188417.

- [15]. Ebihara A, Yahata Y, Miyara K, Nakano K, Hayashi Y, Suda H. Heat treatment of nickel-titanium rotary endodontic instruments: effects on bending properties and shaping abilities. *Int Endod J*. 2011 Sep;44(9):843-9. Pubmed PMID: 21564139.
- [16]. Cunningham CJ, Senia ES. A three-dimensional study of canal curvatures in the mesial roots of mandibular molars. *J Endod*. 1992 Jun;18(6):294-300. Pubmed PMID: 1402588.
- [17]. Govindaraju L, Gurunathan D. Effectiveness of Chewable Tooth Brush in Children-A Prospective Clinical Study. *J Clin Diagn Res*. 2017 Mar;11(3):ZC31-ZC34. Pubmed PMID: 28511505.
- [18]. Christabel A, Anantanarayanan P, Subash P, Soh CL, Ramanathan M, Muthusekhar MR, et al. Comparison of pterygomaxillary dysjunction with tuberosity separation in isolated Le Fort I osteotomies: a prospective, multi-centre, triple-blind, randomized controlled trial. *Int J Oral Maxillofac Surg*. 2016 Feb;45(2):180-5. Pubmed PMID: 26338075.
- [19]. Soh CL, Narayanan V. Quality of life assessment in patients with dentofacial deformity undergoing orthognathic surgery--a systematic review. *Int J Oral Maxillofac Surg*. 2013 Aug;42(8):974-80. Pubmed PMID: 23702370.
- [20]. Mehta M, Deeksha, Tewari D, Gupta G, Awasthi R, Singh H, et al. Oligonucleotide therapy: An emerging focus area for drug delivery in chronic inflammatory respiratory diseases. *Chem Biol Interact*. 2019 Aug 13;308:206-215. Pubmed PMID: 31136735.
- [21]. Ezhilarasan D, Apoorva VS, Ashok Vardhan N. Syzygium cumini extract induced reactive oxygen species-mediated apoptosis in human oral squamous carcinoma cells. *J Oral Pathol Med*. 2019 Feb;48(2):115-121. Pubmed PMID: 30451321.
- [22]. Campeau PM, Kasperaviciute D, Lu JT, Burrage LC, Kim C, Hori M, et al. The genetic basis of DOORS syndrome: an exome-sequencing study. *Lancet Neurol*. 2014 Jan;13(1):44-58. Pubmed PMID: 24291220.
- [23]. Kumar S, Sneha S. Knowledge and awareness regarding antibiotic prophylaxis for infective endocarditis among undergraduate dental students. *Asian Journal of Pharmaceutical and Clinical Research*. 2016;154.
- [24]. Christabel SL, Gurunathan D. Prevalence of type of frenal attachment and morphology of frenum in children, Chennai, Tamil Nadu. *World J Dent*. 2015 Oct;6(4):203-7.
- [25]. Kumar S, Rahman RE. Knowledge, awareness, and practices regarding biomedical waste management among undergraduate dental students. *Asian Journal of Pharmaceutical and Clinical Research*. 2017;10(8):341.
- [26]. Sridharan G, Ramani P, Patankar S. Serum metabolomics in oral leukoplakia and oral squamous cell carcinoma. *J Cancer Res Ther*. 2017 Jul-Sep;13(3):556-561. Pubmed PMID: 28862226.
- [27]. Ramesh A, Varghese SS, Doraiswamy JN, Malaiappan S. Herbs as an antioxidant arsenal for periodontal diseases. *J Intercult Ethnopharmacol*. 2016 Jan 27;5(1):92-6. Pubmed PMID: 27069730.
- [28]. Thamaraiselvan M, Elavarasu S, Thangakumaran S, Gadagi JS, Arthie T. Comparative clinical evaluation of coronally advanced flap with or without platelet rich fibrin membrane in the treatment of isolated gingival recession. *J Indian Soc Periodontol*. 2015 Jan-Feb;19(1):66-71. Pubmed PMID: 25810596.
- [29]. Thangaraj SV, Shyamsundar V, Krishnamurthy A, Ramani P, Ganesan K, Muthuswami M, et al. Molecular Portrait of Oral Tongue Squamous Cell Carcinoma Shown by Integrative Meta-Analysis of Expression Profiles with Validations. *PLoS One*. 2016 Jun 9;11(6):e0156582. Pubmed PMID: 27280700.
- [30]. Ponnulakshmi R, Shyamaladevi B, Vijayalakshmi P, Selvaraj J. In silico and in vivo analysis to identify the antidiabetic activity of beta sitosterol in adipose tissue of high fat diet and sucrose induced type-2 diabetic experimental rats. *Toxicol Mech Methods*. 2019 May;29(4):276-290. Pubmed PMID: 30461321.
- [31]. Ramakrishnan M, Bhurki M. Fluoride, Fluoridated Toothpaste Efficacy And Its Safety In Children-Review. *International Journal of Pharmaceutical Research*. 2018 Oct 1;10(04):109-14.
- [32]. Singh S, Abdul MSM, Sharma U, Sainudeen S, Jain C, Kalliath JT. An in vitro Comparative Evaluation of Volume of Removed Dentin, Canal Transportation, and Centering Ratio of 2Shape, WaveOne Gold, and ProTaper Gold Files Using Cone-Beam Computed Tomography. *J Int Soc Prev Community Dent*. 2019 Sep 30;9(5):481-485. Pubmed PMID: 31620381.
- [33]. Zhao D, Shen Y, Peng B, Hapasalo M. Micro-computed tomography evaluation of the preparation of mesiobuccal root canals in maxillary first molars with Hyflex CM, Twisted Files, and K3 instruments. *J Endod*. 2013 Mar;39(3):385-8. Pubmed PMID: 23402512.
- [34]. Antony SD, Subramanian AK, Nivedhitha MS, Solete P. Comparative evaluation of canal transportation, centering ability, and dentin removal between ProTaper Gold, One Curve, and Profit S3: An in vitro study. *Journal of Conservative Dentistry*. 2020 Nov 1;23(6):632.
- [35]. Silva EJ, Menaged K, Ajuz N, Monteiro MR, Coutinho-Filho T de S. Post-operative pain after foraminal enlargement in anterior teeth with necrosis and apical periodontitis: a prospective and randomized clinical trial. *J Endod*. 2013 Feb;39(2):173-6. Pubmed PMID: 23321226.
- [36]. Silva Santos AM, Portela FMSE, Coelho MS, Fontana CE, De Martin AS. Foraminal Deformation after Foraminal Enlargement with Rotary and Reciprocating Kinematics: A Scanning Electronic Microscopy Study. *J Endod*. 2018 Jan;44(1):145-148. Pubmed PMID: 29033083.
- [37]. Hu W, Whitten B, Sedgley C, Svec T. Effect of three NiTi files on transportation of the apical foramen. *Int Endod J*. 2014 Nov;47(11):1064-71. Pubmed PMID: 24433271.
- [38]. González Sánchez JA, Duran-Sindreu F, de Noé S, Mercadé M, Roig M. Centring ability and apical transportation after overinstrumentation with ProTaper Universal and ProFile Vortex instruments. *Int Endod J*. 2012 Jun;45(6):542-51. Pubmed PMID: 22264187.
- [39]. Frota MMA, Bernardes RA, Vivan RR, Vivacqua-Gomes N, Duarte MAH, Vasconcelos BC. Debris extrusion and foraminal deformation produced by reciprocating instruments made of thermally treated NiTi wires. *J Appl Oral Sci*. 2018 Jan 18;26:e20170215. Pubmed PMID: 29364346.
- [40]. Loprete G, Basilaki J, Romero M, Hecht P. Evaluation of apical foramen deformation produced by manual and mechanized patency maneuvers. *Acta Odontol Latinoam*. 2014;27(2):77-81. Pubmed PMID: 25523959.
- [41]. Vijayashree Priyadharsini J. In silico validation of the non-antibiotic drugs acetaminophen and ibuprofen as antibacterial agents against red complex pathogens. *J Periodontol*. 2019 Dec;90(12):1441-1448. Pubmed PMID: 31257588.
- [42]. J PC, Marimuthu T, C K, Devadoss P, Kumar SM. Prevalence and measurement of anterior loop of the mandibular canal using CBCT: A cross sectional study. *Clin Implant Dent Relat Res*. 2018 Aug;20(4):531-534. Pubmed PMID: 29624863.
- [43]. Ramesh A, Varghese S, Jayakumar ND, Malaiappan S. Comparative estimation of sulfiredoxin levels between chronic periodontitis and healthy patients - A case-control study. *J Periodontol*. 2018 Oct;89(10):1241-1248. Pubmed PMID: 30044495.
- [44]. Ramadurai N, Gurunathan D, Samuel AV, Subramanian E, Rodrigues SJL. Effectiveness of 2% Articaine as an anesthetic agent in children: randomized controlled trial. *Clin Oral Investig*. 2019 Sep;23(9):3543-3550. Pubmed PMID: 30552590.
- [45]. Sridharan G, Ramani P, Patankar S, Vijayaraghavan R. Evaluation of salivary metabolomics in oral leukoplakia and oral squamous cell carcinoma. *J Oral Pathol Med*. 2019 Apr;48(4):299-306. Pubmed PMID: 30714209.
- [46]. Mathew MG, Samuel SR, Soni AJ, Roopa KB. Evaluation of adhesion of *Streptococcus mutans*, plaque accumulation on zirconia and stainless steel crowns, and surrounding gingival inflammation in primary molars: randomized controlled trial. *Clin Oral Investig*. 2020 Sep;24(9):3275-3280. Pubmed PMID: 31955271.
- [47]. Samuel SR. Can 5-year-olds sensibly self-report the impact of developmental enamel defects on their quality of life? *Int J Paediatr Dent*. 2021 Mar;31(2):285-286. Pubmed PMID: 32416620.
- [48]. R H, Ramani P, Ramanathan A, R JM, S G, Ramasubramanian A, et al. CYP2 C9 polymorphism among patients with oral squamous cell carcinoma and its role in altering the metabolism of benzo[a]pyrene. *Oral Surg Oral Med Oral Pathol Oral Radiol*. 2020 Sep;130(3):306-312. Pubmed PMID: 32773350.
- [49]. Chandrasekar R, Chandrasekar S, Sundari KKS, Ravi P. Development and validation of a formula for objective assessment of cervical vertebral bone age. *Prog Orthod*. 2020 Oct 12;21(1):38. Pubmed PMID: 33043408.
- [50]. Vijayashree Priyadharsini J, Smiline Girija AS, Paramasivam A. In silico analysis of virulence genes in an emerging dental pathogen *A. baumannii* and related species. *Arch Oral Biol*. 2018 Oct;94:93-98. Pubmed PMID: 30015217.