

## Establishing Post Orthodontic Norms for Incisor Positioning In South Indian Population Using Tetragon Analysis

Research Article

Nitin V Muralidhar<sup>1\*</sup>, Jyothi Kiran H<sup>2</sup>, Raghunath N<sup>3</sup>

<sup>1</sup> Reader, Department of Orthodontics & Dentofacial Orthopaedics, JSS Dental College and Hospital, JSS Academy of Higher Education & Research Karnataka, Mysuru – 570015, India.

<sup>2</sup> Department of Orthodontics & Dentofacial Orthopaedics, JSS Dental College and Hospital, JSS Academy of Higher Education & Research, Karnataka, Mysuru – 570015, India.

<sup>3</sup> Prof & Head of Department, Department of Orthodontics & Dentofacial Orthopaedics, JSS Dental College and Hospital, JSS Academy of Higher Education & Research, Karnataka, Mysuru – 570015, India.

### Abstract

This study aims at providing ideal cephalometric norms to position the maxillary and mandibular incisors at the end of orthodontic treatment in the ethnic south Indian population.

**Materials and methods:** 65 individuals having Class I malocclusion with bimaxillary protrusion were considered for this study with 20 males and 45 females, who needed orthodontic treatment with extraction of all the first pre molars. Fastlitch's Tetragon analysis (U1-PP;U1-L1,L1-MP,MP-PP, Pt -Or /Pt -PNS, Pt-PNS/PP, PP- Pt/Or) was employed to identify the changes brought about due to orthodontic treatment.

**Results:** The orientation of the maxillary incisors in the South Indian population was found to be similar to that of the norms given by Fastlitch, but the Lower incisors were more proclined and as a result there was decreased interincisal angulation noted and with a predominantly low angle individuals were noted.

**Conclusion:** This study provides the clinician a definitive end point to orient the maxillary and mandibular incisors in case of ethnic south Indian population after orthodontic treatment.

**Keywords:** Cephalometric Norms; Planned Incisor Positioning; Tetragon Analysis.

### Introduction

The position of the upper central incisor plays a vital role in smile esthetics, Ramos [1] Orthodontists rely on the normative values based on cephalometric analysis ever since Broadbent [2] introduced lateral cephalometric radiography in 1931. In spite of the norms most of the times it is not possible to achieve the ideal incisor position as prescribed.

Only a skillful orthodontist with an artistic viewpoint will be able to successfully place the incisors aesthetically. To support the decision of the orthodontist, many researchers like Steiners [3], Downs [4], Tweeds [5] and many others have put forth their analysis for an ideal upper incisor position.

Steiner [3] was the one of the first researchers to imply that cephalometric norms of one ethnic group need not necessarily be applied to other ethnic groups. Gradually many researchers and clinicians started noticing the variations in the normative values in their respective population groups. Following which a number of cephalometric analysis specific to their ethnic groups were put forward like Paek's [6] study of Korea population, Nanda's [7] study of north Indians, Garcia's [8] study of the Mexican Americans and so on. All these studies indicate that the normative values of one ethnic group cannot be applied to the other groups as normative values due to differences on facial patterns. Hence customized cephalometric norms must be developed for each ethnic group.

#### \*Corresponding Author:

Nitin V Muralidhar, MDS,  
Reader, Department of Orthodontics & Dentofacial Orthopaedics, JSS Dental College and Hospital, JSS Academy of Higher Education & Research  
Karnataka, Mysuru – 570015, India.  
Tel: +9448413146  
E-mail: dr.nitinmuralidhar@jssuni.edu.in

**Received:** September 15, 2021

**Accepted:** November 28, 2021

**Published:** December 07, 2021

**Citation:** Nitin V Muralidhar, Jyothi Kiran H, Raghunath N. Establishing Post Orthodontic Norms for Incisor Positioning In South Indian Population Using Tetragon Analysis. *Int J Dentistry Oral Sci.* 2021;8(12):5197-5200. doi: <http://dx.doi.org/10.19070/2377-8075-210001042>

**Copyright:** Nitin V Muralidhar, MDS©2021. This is an open-access article distributed under the terms of the Creative Commons Attribution License, which permits unrestricted use, distribution and reproduction in any medium, provided the original author and source are credited.

The principal aim of any analysis is to provide a simple, reliable and reproducible method. One such analysis was introduced by Dr. Jorge Fastlicht [9] in the year 2000 known as the “Tetragon: A Visual cephalometric analysis”. Since the Tetragon analysis was carried out on Caucasian and White North American subjects whose norms may differ with those of the ethnic Asian population, hence this study was carried out on south Indian subjects from Mysuru district, Karnataka, India, to find out the ideal cephalometric parameters to position the maxillary and mandibular incisors using the Tetragon analysis.

### Aims & Objectives

To determine the normative values of maxillary and mandibular incisor positioning using Tetragon analysis after orthodontic treatment in South Indian Population.

### Materials and Methods

The sample consisted of sixty-five individuals out of which 20 were males and 45 were females with an average age of 18-25 years.

#### Inclusion Criteria

Class I malocclusion with bimaxillary protrusion individuals.  
Patients who needed fixed orthodontic therapy with extraction of all first premolar teeth.  
Subjects who are native of Mysuru district were selected for the study.

#### Exclusion criteria

Subjects with craniofacial deformities.  
Subjects requiring functional appliance therapy or orthopaedic appliance therapy.  
Subjects requiring orthognathic surgery for correction of jaw deformities.

#### Method of collecting the data

The patient's pre-treatment and post-treatment cephalograms, which were taken as a part of routine orthodontic treatment protocol, were digitally analyzed using the Nemoceph software by a

single operator twice to avoid any operator variability. Due consent was taken from the patients before commencing the study. All the patients were treated with MBT 022” slot prescription.

Tetragon analysis was employed to decipher the pre-treatment and post-treatment lateral cephalograms to evaluate the changes in the orientation of incisors in relation to the jaw bases.

#### Tetragon (Fig 1&2)

U1-PP: The angle formed between the palatal plane (PP) with the long axis of the maxillary central incisors.

U1-L1: Angulation between the long axis of maxillary and the mandibular central incisors.

L1-MP: Angulation of the mandibular incisor long axis with the mandibular plane.

MP-PP: Angulation between the mandibular plane and the PP.

According to Fastlicht's analysis, the Tetragon comprises of four sides, forming four angles which will add upto 360°. If any of the angle sare modified, either by growth or by orthodontic treatment, the angles of the Tetragon will tend change, but their sum will still remain 360°. In the advent that the angles are not adding upto 3600, an inference can be inferred that either that the tracing is inaccurate or that one or more angles have been calculated incorrectly.

#### TRIGON (Fig 3)

Pt.-Or/Pt-PNS: Angulation between Pt-Or plane and Pt-PNS plane.

Pt.-PNS/PP: Angulation between the Pt-PNS and the PP.

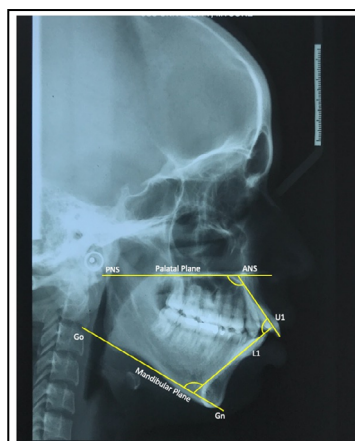
Pt.-Or/PP: Angulation between the Pt.-Or plane and the PP.

The Trigon consists of three sides, with three angles that will add up to 180°. In any case, these 3 angles must always be 180°.

In a scenario where the Palatal plane and the Pt-Or plane are parallel, the angulation between these two planes will be neutral or 0°, but the sum of the remaining two r angles will still be 180°.

**Statistical analysis used:** Descriptive analysis – Mean and standard deviation was used and Paired T-test was used to compare the pre and post treatment changes.

Figure 1. Tetragon analysis: Pre treatment Cephalogram.



PNS: Posterior Nasal Spine, ANS: Anterior Nasal Spine, U1: Upper Incisor; L1: Lower Incisor, Gn: Gnathion, Go: Gonion

## Results

Paired t-test was used to compare between standard mean values and post treatment values. It was observed that there was significant difference between the standard mean values and post treatment values of the mandibular plane to the palatal plane (Go-Gn to PP), lower incisor inclination to the mandibular plane (L1-IMPA) and the interincisal angulation (U1-L1) with  $p < 0.05$ . But there was no significant difference observed between standard mean values and post treatment values of the upper incisor inclination to the palatal plane (U1 to PP) with  $p$  value 0.511. There was no difference between both males and females across all parameters. (Table 1)

The Trigon values of the Pt-Or plane and Pt-PNS angle the Pt-

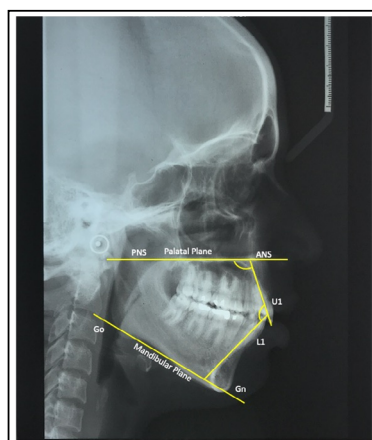
PNS/PP plane angle was statistically significant and the Pt-Or-PP angle was not statistically significant. (Table 2)

## Discussion

In this study the maxillary incisor inclination to the palatal plane (U1-PP) after the treatment was similar to the values of Fastlicht [9]. However, the study conducted by John and Valiathan [10] (1991) found increased proclination of the maxillary incisors in case of Class II individuals. The reason maybe the difference in type of malocclusion chosen for the study.

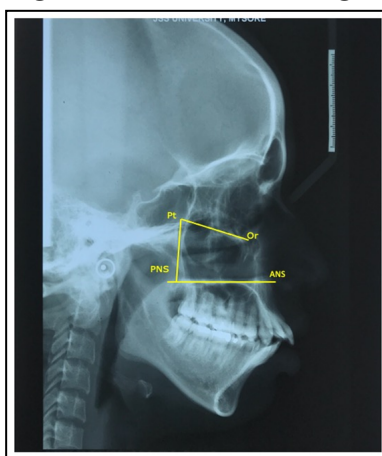
The interincisal angulation (U1-L1) was decreased and is statistically significant as this value is dependent on both the maxillary and mandibular incisor inclinations and maxillary incisor retraction was more contributory towards increasing the interincisal

Figure 2. Tetragon analysis: Post treatment Cephalogram.



PNS: Posterior Nasal Spine, ANS: Anterior Nasal Spine, U1: Upper Incisor; L1: Lower Incisor, Gn: Gnathion, Go: Gonion

Figure 3. Construction of Trigon.



Or: Orbitale, Pt: Pterygoid vertical, ANS: Anterior Nasal Spine, PNS: Posterior Nasal Spine

Table 1. Tetragon Values.

Tetragon Measurements	Std Mean value	Pre -treatment Mean	Post -Treatment values	Paired difference	P value
					(Compared with the Std. Mean Value)
Go-Gn- PP	30	24	24	5.81 ± 7.64	<0.001
U1-PP	110	118.031	109	+1.05 ± 12.84	0.511 NS
IMPA	90	98.631	92	-3.79 ± 12.46	0.026
U1-L1 (Angle)	130	108.292	126	4.34 ± 8.25	<0.001

Table 2. Trigon Values.

Trigon Measurements	Mean Values	Post Treatment Values (Average)	P Value
Pt-Or/Pt-PNS	85°	81.16 - 6.39	<0.001
Pt-PNS/PP	87°	89.4827 - 7.25	0.001
Pt-Or/PP	8°	7.39 - 2.89	0.1169 NS

Table 3. Comparative mean values of Tetragon &amp; Trigon angles.

Tetragon Measurements	Std Mean value	Mean values for South Indian Population
Go-Gn- PP	30°	24°
U1-PP	110°	109°
IMPA	90°	92°
U1-L1 (Angle)	130°	126°
Trigon Measurements		
Pt-Or/Pt-PNS	85°	81°
Pt-PNS/PP	87°	89°
Pt-Or/PP	8°	7°

angulation. The results can be compared with that of Basciftci and Usumex [11] (2003) who compared the class I and Class II malocclusions.

The lower incisor inclination in relation to the mandibular plane (IMPA) was more than the mean values postulated by Broadbent [12], Riolo [13] and Schwartz [14]. The amount of retraction of lower incisors was less than that of the maxillary incisor retraction.

In this study the value of the mandibular plane to the palatal plane (Go-Gn-PP) shows statistically significant when compared with the normative values but exhibited no change when compared with the pre-treatment values. This indicates that there was no alteration of dentition in the vertical dimension.

The Trigon values of Pt -Or /Pt -PNS and Pt-PNS/PP showed statistically significant values but not clinically significant as there was no major Orthopaedic treatment carried out like myo-functional therapy and the palatal plane to the Pt-Or plane did not exhibit any significant change indicating no alteration of the skeletal jaw bases in the vertical dimension.

This study was conducted only on individuals having Class I malocclusion with bimaxillary protrusion. Further studies with must be carried out with a larger sample size and across all types of malocclusions to derive the cephalometric norms for the Indian population. Table 3.

## Summary & Conclusion

According to this study the South Indian population exhibited a more proclined mandibular incisors than the maxillary incisors when compared to the established norms and accordingly there was increased interincisal angulation. The study also revealed that the South Indian Population exhibited a predominantly horizontal growing individuals as compared to the Caucasian population.

Therefore this study provides the clinician a definitive direction to orient the incisors and apply appropriate treatment mechanics to suit the local population needs.

## References

- Ramos AL, Sakima MT, Pinto Ados S, Bowman SJ. Upper lip changes correlated to maxillary incisor retraction—a metallic implant study. *Angle Orthod.* 2005 Jul;75(4):499-505. PubMed PMID: 16097216.
- Broadbent BH. A new x-ris technique and its application to orthodontia. *The Angle Orthodontist.* 1931 Apr;1(2):45-66.
- Steiner CC. Cephalometrics for you and me. *American journal of orthodontics.* 1953 Oct 1;39(10):729-55.
- DOWNS WB. Variations in facial relationships; their significance in treatment and prognosis. *Am J Orthod.* 1948 Oct;34(10):812-40. PubMed PMID: 18882558.
- Tweed CH. The Frankfort-mandibular incisor angle (FMIA) in orthodontic diagnosis, treatment planning and prognosis. *The Angle Orthodontist.* 1954 Jul;24(3):121-69.
- Park IC, Bowman D, Klapper L. A cephalometric study of Korean adults. *Am J OrthodDentofacialOrthop.* 1989 Jul;96(1):54-9. PubMed PMID: 2750721.
- Nanda R, Nanda RS. Cephalometric study of the dentofacial complex of North Indians. *Angle Orthod.* 1969 Jan;39(1):22-8. PubMed PMID: 5250522.
- Garcia CJ. Cephalometric evaluation of Mexican Americans using the Downs and Steiner analyses. *Am J Orthod.* 1975 Jul;68(1):67-74. PubMed PMID: 1056145.
- Fastlicht J. Tetragon: A visual cephalometric analysis. *J ClinOrthod* 2000;34(6):353-60.
- John KK, Valiathan A. Steiner's analysis on adults from Kerala with normal, Class II and Class III occlusions—a comparison. *J IndOrthod Soc.* 1991;22:13-9.
- Basciftci FA, Usumez S. Effects of extraction and nonextraction treatment on class I and class II subjects. *Angle Orthod.* 2003 Feb;73(1):36-42. PubMed PMID: 12607853.
- Broadbent Jr BH, Golden WH, BROWN RG. Bolton standards of dentofacial development growth. *Plastic and Reconstructive Surgery.* 1977 Jan 1;59(1):115.
- Riolo ML, Moyers RE, McNamara JA, Hunter AS. *An Atlas of Craniofacial Growth, Centre for Human Growth and Development, University of Michigan.* Ann Arbor, Michigan. 1974.
- Schwarz AM. Roetgenostatics: A practical evaluation of X -ray headplate. *Am J Orthod.* 1961;47:561-585.