

## Comparison Of Efficacy Of Aceclofenac Sodium And Piroxicam In Patients Undergoing Surgical Removal Of Impacted Third Molar - A Randomised Controlled Trial

Research Article

Dr. Yandeti Srinivasulu<sup>1\*</sup>, Dr. Abdul Wahab<sup>2</sup>, Dr. Dinesh Prabu<sup>3</sup>

<sup>1</sup> Department of Oral and Maxillofacial surgery, Saveetha Dental College and Hospital, Saveetha Institute of Medical and Technical Sciences (SIMATS), Saveetha University, 162, Poonamallee High Road, Chennai 600077, Tamil Nadu, India.

<sup>2</sup> Professor, Department of Oral and Maxillofacial Surgery, Saveetha Dental College and Hospital, Saveetha Institute of Medical and Technical Sciences (SIMATS), Saveetha University, 162, Poonamallee High Road, Chennai 600077, Tamil Nadu, India.

<sup>3</sup> Senior Lecture, Department of Oral and Maxillofacial Surgery, Saveetha Dental College and Hospital, Saveetha Institute of Medical and Technical Sciences (SIMATS), Saveetha University, 162, Poonamallee High Road, Chennai 600077, Tamil Nadu, India.

### Abstract

**Aim:** The aim of the study was assessing the efficacy of Piroxicam vs Aceclofenac sodium as an analgesic after removal of third molars when given post operatively. The study was a side-by-side comparison of two medications.

**Materials And Methods:** A prospective randomized study conducted with 40 patients that required removal of mesio angularly impacted mandibular third molar. The systematic statistical analysis was performed after the data collection was done. Patients were categorized into two groups (Group 1 : piroxicam, Group 2 : Aceclofenac sodium) in a crossover manner. Subjective and objective observations recorded that include age, gender, and pain score using visual analog scale. Each patient was evaluated using a visual analogue scale.

**Results:** Pain intensity at the postoperative 1st, 3rd, 5th, 7th day postoperative was less in Piroxicam group than Aceclofenac and there was significant difference seen statistically ( $p < 0.001$ ). Swelling and Trismus were not statistically significant, however there were significant reduction in Swelling and Trismus on 3rd day.

**Conclusion:** Piroxicam had better efficacy and tolerability profile than Aceclofenac 100 mg in the management of pain after surgical removal of impacted mandibular third molar. Piroxicam is easy to use and the quick action of this formulation are advantages that are likely to improve patient compliance.

**Keywords:** Anti Inflammatory; Piroxicam; Aceclofenac Sodium; Mandibular Third Molar.

### Introduction

Careful evacuation of affected mandibular third molars is one of the most widely recognized strategies in Oral Maxillofacial Surgical practice [1]. Because of unavoidable post surgical complications, it is often difficult for a patient to decide to remove a third molar [2]. Pain experienced by the patient after surgical removal of a third molar is typically moderate to severe which is lasting for more than 24 hours [3]. Aside from the discomfort, growing, and trismus associated with aggravation, there are other unfavourable consequences for these people who have their third molars carefully removed [4, 5]. Patients related factors, tooth related factors and operative factors are affecting postop-

erative morbidity. In younger individuals, the surrounding bone is more fragile and stronger, whereas in older patients, the bone is firmer, necessitating greater bone removal, resulting in increased postoperative growth and trismus [6, 7]. In general, external cold dressing, modulating the closure technique, varying the dressing agents, open versus closed dressing, modulating the extent of surgical trauma, skill of surgeon, surgical technique, modifying the flap design, pharmacological methods, anti-inflammatory drugs, and analgesics may be used to treat pain, swelling, and trismus after lower third molar surgery, antibacterial mouthwashes and steroidal therapy [1]. Non-steroidal Anti-Inflammatory Drugs are effective in managing pain associated with oral surgery. They have more of a therapeutic effect and act by inhibition of Cyclooxy-

#### \*Corresponding Author:

Dr. Yandeti Srinivasulu,

Department of Oral and Maxillofacial surgery, Saveetha Dental College and Hospital, Saveetha Institute of Medical and Technical Sciences (SIMATS), Saveetha University, 162, Poonamallee High Road, Chennai 600077, Tamil Nadu, India.

Tel: +91-8317643422

E-mail: [srinivasuluyandeti@gmail.com](mailto:srinivasuluyandeti@gmail.com)**Received:** July 23, 2021**Accepted:** November 10, 2021**Published:** November 15, 2021

**Citation:** Dr. Yandeti Srinivasulu, Dr. Abdul Wahab, Dr. Dinesh Prabu. Comparison Of Efficacy Of Aceclofenac Sodium And Piroxicam In Patients Undergoing Surgical Removal Of Impacted Third Molar - A Randomised Controlled Trial. *Int J Dentistry Oral Sci.* 2021;8(11):5013-5016. doi: <http://dx.doi.org/10.19070/2377-8075-210001010>

**Copyright:** Dr. Yandeti Srinivasulu ©2021. This is an open-access article distributed under the terms of the Creative Commons Attribution License, which permits unrestricted use, distribution and reproduction in any medium, provided the original author and source are credited.

genase (COX) that in turn inhibits prostaglandin production. The two isoforms of COX are known as COX-1, COX-2. COX-1 is a constitutive structure that is available in practically all tissues and is answerable for the physiological elements of prostanoids, bringing about gastric mucosal assurance and vascular homeostasis. COX-2 is found in a set number of tissues, for example, kidney, prostate and mind which is for the most part liable for the union of prostanoids [8].

Aceclofenac, like diclofenac and indomethacin, has anti-inflammatory effects and is effective in the treatment of dental pain [9]. After oral administration, it is rapidly absorbed, with a plasmatic concentration peaking between 1 h 25 min and 3 h. Because the medicine has a 4-hour half-life, a daily dose of 200 mg is recommended [10].

Piroxicam is a non-steroidal pain reliever and mitigation that is artificially added to other available drugs. As a pain reliever, Piroxicam is progressively more powerful than Aspirin, Ibuprofen. Piroxicam is an inhibitor of prostaglandin union, being a particular reversible inhibitor of the cyclooxygenase venture of arachidonic corrosive digestion.

## Materials and Methods

**Study setting and Data collection:** A prospective randomized study conducted with 40 patients that required removal of mesio angularly impacted mandibular third molar. The systematic statistical analysis was performed after the data collection was done. Patients were categorized into two groups (Group1: piroxicam Group 2: Aceclofenac sodium) in a crossover manner. Subjective and objective observations recorded that include age, gender, and pain score using visual analog scale. Each patient was evaluated using a visual analogue scale.

Patients were reported to Saveetha Dental College for pain treatments. The Patients were reported to the Department of Oral and Maxillofacial Surgery for surgical removal of third molar impaction.

Ethical committee approval for this study was obtained from the Institutional Ethics Committee with the following ethical approval number. SDC/SIHEC/2020/DIASDATA/0619-0320.

## Sampling

The study population included patients who underwent treatment

for pericoronitis at Saveetha Dental College by means of Systematic Sampling.

- Inclusion Criteria- Patients of all age groups and gender with impacted mandibular third molars with diagnosis of pericoronitis were included.
- Exclusion Criteria- Patients with impacted teeth other than third molars, and common dental problems were excluded from the study.

Duplicate patient records and incomplete data were excluded. Datas were reviewed by an external reviewer. Totally, n= 650 patients were included. Demographic data such as the patient's age, gender and pericoronitis, pericoronal abscess were also recorded.

## Data Analysis

The data was tabulated in Microsoft Excel 2016 (Office 10) before being exported to SPSS (Statistical Package for Social Sciences) for Windows version 20.0, SPSS Inc, Chicago IU, USA) for statistical analysis.. Chi-square test was employed with a level of significance set at  $p < 0.05$ .

## Results

There were 26 female patients and 14 male patients, with an average age of 30 years. Data collected by means of the Visual Analogue Scale. The difference in postoperative pain scores between the groups was statistically significant at any of the time points studied patients in the piroxicam Group had a lower pain score at all time points. Data collected by means of the 0–4 Scale are Group 1 had a lower pain score at all time points. At 5 h after surgery, the difference between the groups was statistically significant. The comparison of mean pain scores at 1st day after surgery revealed a statistically significant difference between the groups, both according to VAS and by the 0–4 Scale. The efficacy of NSAID was larger in Group 1. Gender distribution and age distribution was seen in figure 1 and figure 2. Data collected by means of the 0–4 Scale are shown in Table 1. Group 1 had a lower pain score at all time points. At 5 hours after surgery, the difference between the groups was statistically significant (Kruskal– Wallis nonparametric test).

## Discussion

Postoperative pain resulting from the surgery of impacted mandibular third molars is one of the most frequent complications

**Figure 1. Bar diagram depicting the gender distribution of patients in two age groups where Blue bar represents male and green bar indicates females. X axis indicates the gender and Y axis indicates the no of patients. In this study, incidence of females were more compared to males in both the groups in surgical removal of impacted teeth.**

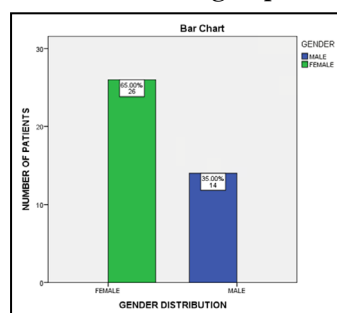


Figure 2. Bar diagram depicting the age distribution of patients in three age groups where Blue bar represents male and green bar indicates females. X axis indicates the age group and Y axis indicates the no of patients. In this study, incidence of females were more compared to males in these age groups, which indicates Female predilection for in patients undergoing surgical removal of impacted third molars..

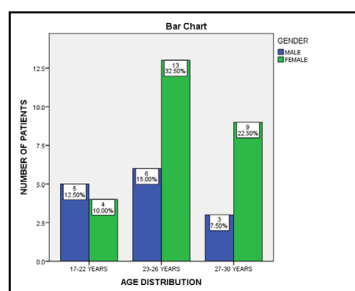


Table 1. Mean pain scores for the 2 groups according to the 0–4 Scale (Kruskal–Wallis nonparametric test).

Day	Group	Mean pain score	Standard Deviation	P Value
1st HOUR	GROUP 1	0.65	0.54	0.132
	GROUP 2	1.04	0.64	
3rd HOUR	GROUP 1	0.7	0.72	0.268
	GROUP 2	1.02	0.71	
5th HOUR	GROUP 1	0.5	0.58	0.030*
	GROUP 2	1.05	0.69	
7th HOUR	GROUP 1	0.61	0.83	0.41
	GROUP 2	0.75	0.73	

\* Statistically significant

[3, 11]. Pain is moderate to severe and likely to affect the patient’s routine [12]. After removal of third molars we can compare the analgesic effect of NSAID after the surgery [13]. However, we used different drugs for the different groups, which complicates the assessment of the best moment for administration.. Therefore, only patients are able to assess the pain that they are feeling. Pain assessment instruments have been created specifically for this purpose. In this study the parameters used to assess pain intensity where the Visual Analogue Scale recommends the number of analgesic tablets taken after the Surgery [14, 7]. Results found with the Visual Analogue Scale showed that Group 1 had a lower pain score at all time points in the study.

In both groups, a 20 mg piroxicam NSAID dose was efficient in controlling pain, with a mean VAS score below 2.5 points, whereas SEYMOUR et al.[15], found a mean pain score of 3 or greater in patients that used 100 mg aceclofenac postoperatively. Mean pain score for Group 1 on the first day after the surgery, the critical pain period [16], was lower, and this difference was statistically significant (P 0.05 and P 0.01 for the 0–4 Scale and VAS, respectively). These results confirm that NSAIDs are more efficient in controlling pain when administered before the onset of the inflammatory process. The parameters we used to establish the study time points were based on literature publications indicating that the most painful period following surgery to extract impacted third molars is 3–6 hours [16, 15]. Also, patient collaboration was necessary, which further limited the assessment period [17].

Pain can be caused by tissue damage and inflammation (inflammatory pain), damage to the central nervous system (neuropathic pain), or changes in the nervous system's normal function (neuropathic pain) (functional pain) [18]. Excessive touchiness to agony

might be a typical postoperative indication in surgeries [19]. The vibe of torment at the careful site might be expanded and continue for longer periods much after the expulsion of the harmful upgrade, portraying the procedure of hyperesthesia. Such an expansion in affectability may likewise bring about torment at the encompassing region of the careful site which portrays the idea of allodynia [20, 9].

Conclusion

Piroxicam had better efficacy and tolerability profile than Aceclofenac 100 mg in the management of pain after surgical removal of impacted mandibular third molar. Piroxicam is easy to use and the quick action of this formulation are advantages that are likely to improve patient compliance.

References

- [1]. Mohammad S, Singh V, Wadhvani B, Tayade HP, Rathod OK. Sublingual piroxicam in the management of postoperative pain after surgical removal of impacted mandibular third molar. Indian J Dent Res. 2012 Nov-Dec;23(6):839-40. PubMed PMID: 23649080.
- [2]. Balihallimath LJ, Shruti SP. Sublingual piroxicam for management of postoperative pain, trismus and swelling after extraction of lower third molars: an overview.
- [3]. Nørholt SE. Treatment of acute pain following removal of mandibular third molars. Use of the dental pain model in pharmacological research and development of a comparable animal model. Int J Oral Maxillofac Surg. 1998;27Suppl 1:1-41. PubMed PMID: 9638499.
- [4]. Trindade PA, Giglio FB, Colombini-Ishikiriama BL, Calvo AM, Modena KC, Ribeiro DA, Dionísio TJ, Brozoski DT, Lauris JR, Faria FA, Santos CF. Sublingual ketorolac and sublingual piroxicam are equally effective for postoperative pain, trismus, and swelling management in lower third molar removal. Oral Surg Oral Med Oral Pathol Oral Radiol. 2012 Jul;114(1):27-34. PubMed PMID: 22732846.

- [5]. Punwutikorn J, Waikakul A, Ochareon P. Symptoms of unerupted mandibular third molars. *Oral Surg Oral Med Oral Pathol Oral Radiol Endod.* 1999 Mar;87(3):305-10. PubMed PMID: 10102590.
- [6]. Ahmed SS, ElSharawy EA, Hamed TA. Clinical evaluation of Cox-2 inhibitor for management of post operative complications after odontectomy of impacted lower third molar. *J Am Sci.* 2014;10(11):60-3.
- [7]. van der Zwan J, Boering G, Wesseling H, Smit Sibinga CT, van der Weele LT. The lower third molar and anthropometrics. *Int J Oral Surg.* 1982 Dec;11(6):340-50. PubMed PMID: 6820006.
- [8]. Legrand E. Aceclofenac in the management of inflammatory pain. *Expert Opin Pharmacother.* 2004 Jun;5(6):1347-57. PubMed PMID: 15163279.
- [9]. Brogden RN, Wiseman LR. Aceclofenac. *Drugs.* 1996 Jul 1;52(1):113-24.
- [10]. Dooley M, Spencer CM, Dunn CJ. Aceclofenac. *Drugs.* 2001 Aug 1;61(9):1351-78.
- [11]. Ventä I, Ylipaavalniemi P, Turtola L. Long-term evaluation of estimates of need for third molar removal. *J Oral Maxillofac Surg.* 2000 Mar;58(3):288-91. PubMed PMID: 10716110.
- [12]. Savin J, Ogden GR. Third molar surgery--a preliminary report on aspects affecting quality of life in the early postoperative period. *Br J Oral Maxillofac Surg.* 1997 Aug;35(4):246-53. PubMed PMID: 9291262.
- [13]. Waite PD, Reynolds RR. Surgical management of impacted third molars. *Semin Orthod.* 1998 Jun;4(2):113-23. PubMed PMID: 9680909.
- [14]. Smith AC, Brook IM. Inhibition of tissue prostaglandin synthesis during third molar surgery: use of preoperative fenbufen. *Br J Oral Maxillofac Surg.* 1990 Aug;28(4):251-3. PubMed PMID: 2119796.
- [15]. Seymour RA, Frame J, Negus TW, Hawkesford JE, Marsden J, Matthew IR. The comparative efficacy of aceclofenac and ibuprofen in postoperative pain after third molar surgery. *Br J Oral Maxillofac Surg.* 1998 Oct;36(5):375-9. PubMed PMID: 9831059.
- [16]. Berge TI, Bøe OE. Predictor evaluation of postoperative morbidity after surgical removal of mandibular third molars. *Acta Odontol Scand.* 1994 Jun;52(3):162-9. PubMed PMID: 8091963.
- [17]. Gallardo E, Carstens M, Ayarza M. Analgesic and antiinflammatory effects of glucamethacin (a nonsteroidal antiinflammatory analgesic) after the removal of impacted third molars. *Oral Surg Oral Med Oral Pathol.* 1990 Feb;69(2):157-60. PubMed PMID: 2304739.
- [18]. Borsook D. Neurological diseases and pain. *Brain.* 2012 Feb;135(Pt 2):320-44.
- [19]. van Gool AV, Ten Bosch JJ, Boering G. Clinical consequences of complaints and complications after removal of the mandibular third molar. *Int J Oral Surg.* 1977 Feb;6(1):29-37. PubMed PMID: 402320.
- [20]. Kelly DJ, Ahmad M, Brull SJ. Preemptive analgesia I: physiological pathways and pharmacological modalities. *Can J Anaesth.* 2001 Nov;48(10):1000-10. PubMed PMID: 11698320.