

## Erysipelas Revealing a Cook's Syndrome

Case Report

K. Achehboune\*, H. Baybay, N. Aqil, R. Chaoui, Z. Douhi, S. Gallouj, F.Z. Mernissi

Department of Dermatology, CHU Hassan II, Fez, Morocco.

### Abstract

Cook's syndrome (CS) is a rare disease, described for the first time by cooks and all. It is characterized by the association of anonychia and/or congenital onychodystrophy, hypoplasia and/or the absence of distal phalanges of the hands and feet and a bradydactyly of the fingers with digitalization of the thumb. We report the case of a patient with congenital anonychia with left foot bradydactylia, which is probably a variant of CS.

**Keywords:** Erysipelas; Génodermatosis; Cook's Syndrome.

**Abbreviations:** CS: Cook's Syndrome.

### Introduction

Cook's syndrome is a rare condition characterized by anonychia and/or congenital onychodystrophy, hypoplasia, and/or the absence of distal phalanges of the hands and feet and bradydactyly of the fifth fingers with digitalization of the thumb [1]. Erysipelas, an infectious dermo-hypodermatitis, frequently occurs on lymphoedema. We report the case of a patient presenting with congenital anonychia with absence of distal phalanges of the left foot which is a variant of Cook's syndrome revealing by erysipelas on the right leg.

### Observation

It was a 54-year-old, female, who had been consanguineous, without a similar case in the family, with normal psychomotor development, who had been hospitalized for erysipelas of the left lower limb associated with lymphedema. Clinical examination revealed a painful oedematous erythematous placard on the dorsal surface of the left foot to the middle 1/3 of the leg, intertrigo with diffuse purulent fissure, without signs of local gravity, 5-fold bradydactyly. toes, an onychodystrophy of the first toe and anonychia of the last four toes, the examination of the remaining nails had not shown similar abnormalities nor associated malformations (Figure 1). The standard radiography of the left foot had justified a hypoplasia of the second phalanx with absence of the

last phalanx of the four toes and hypoplasia of the last phalanx of the first toe, the radiograph hand and foot against side were without particularities (Figure 2).

Our patient was treated with amoxicillin protected with a favorable course: complete regression of edematous erythematous placemat and persistence of a slight lymphedema (Figure 3).

Prophylactic antibiotic with penicillin delayed every 3 weeks in the long term was prescribed to prevent recurrence, given lymphoedema.

### Discussion

Cook's syndrome is an autosomal dominant ectodermal dysplasia, reported as a rare variety by the Office of Rare Diseases of the National Institutes of Health [2].

Cook et al., [1] described for the first time a syndrome characterized by onychodystrophy or anonychia, brachydactyly of the fifth finger, and digitalization of the thumb, with absence or hypoplasia of distal phalanges of the hands and feet, in seven persons with two generations of the same family, and suspected an autosomal dominant disease [1].

According to Seitz et al., The regulatory proteins signal the for-

#### \*Corresponding Author:

Achehboune Kaoutar,  
Department of Dermatology, CHU Hassan II Fez, Morocco.  
E-mail: [achehboune.kaoutar@gmail.com](mailto:achehboune.kaoutar@gmail.com)

**Received:** November 08, 2018

**Accepted:** May 28, 2019

**Published:** May 30, 2019

**Citation:** K. Achehboune, H. Baybay, N. Aqil, R. Chaoui, Z. Douhi, S. Gallouj, et al., Erysipelas Revealing a Cook's Syndrome. *Int J Clin Dermatol Res.* 2019;7(3):207-208.  
**doi:** <http://dx.doi.org/10.19070/2332-2977-1900051>

**Copyright:** K. Achehboune©2019. This is an open-access article distributed under the terms of the Creative Commons Attribution License, which permits unrestricted use, distribution and reproduction in any medium, provided the original author and source are credited.

Figure 1 (A, B). Edematous erythematous placard of the dorsal surface of the left foot arriving at the middle 1/3 of the leg, a bradydactyly of the 5 toes, an onychodystrophy of the first toe and anonychia of the last four toes.

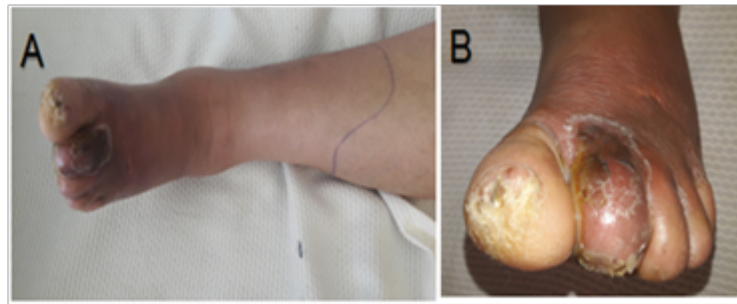


Figure 2 (C, D). Standard radiography of the left foot showed hypoplasia of the second phalanx with absence of the last phalanx of the four toes and hypoplasia of the last phalanx of the first toe.

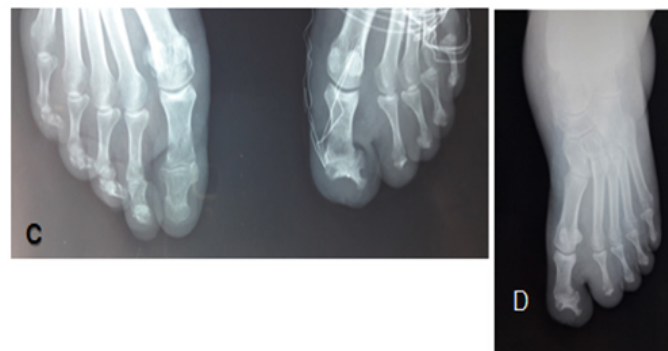
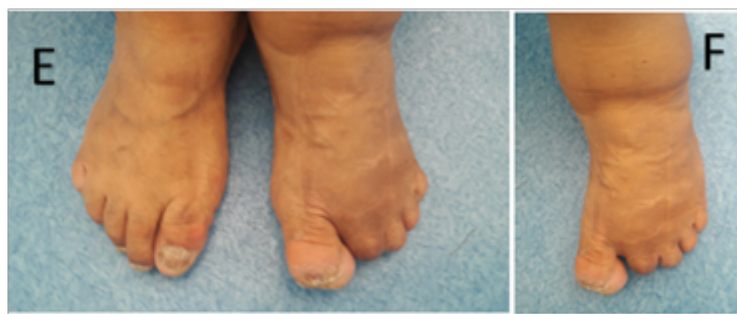
Figure 3 (E, F). Photos of our patient after 3 months of the erysipelas episode.



mation of bone mesenchyme at the level of the distal phalanx; it develops at the same time as the nails. Nail growth is closely related to the size of the distal end of the phalanx, the growth of the nail is faster on a larger phalanx [3]. Therefore, there is a link between phalanx growth and nail development.

To date, only 20 cases of Cook syndrome have been reported in the literature [4]. Padmavathy L and all. had reported a variant of Cook's syndrome affecting the 2 small fingers of the hands [5]. A single similar case of anonychia and congenital bradydactyly of the left foot in a 45-year-old male reported in India is probably a variant of this syndrome [2]. We report a second, in a 54-year-old woman revealed by erysipelas of the leg, the latter could be favored by lymphoedema secondary to abnormalities observed during the Cook's syndrome.

## Conclusion

Erysipelas on a lymphoedema must make look for the underlying pathologies of which the Cook's syndrome is part. The trained

dermatologist must think about the abnormalities mentioned above and restore a prophylactic treatment.

## References

- [1]. Cooks RG, Hertz M, Katznelson MB, Goodman RM. A new nail dysplasia syndrome with onychonychia and absence and/or hypoplasia of distal phalanges. *Clin Genet.* 1985 Jan;27(1):85-91. PubMed PMID: 3978841.
- [2]. Chatterjee D. Congenital anonychia and brachydactyly of the left foot - Cooks syndrome variant: Case report and review of literature. *Indian J Hum Genet.* 2014 Apr;20(2):206-8. doi: 10.4103/0971-6866.142914. PubMed PMID: 25400355.
- [3]. Seitz CS, Hamm H. Congenital brachydactyly and nail hypoplasia: clue to bone-dependent nail formation. *Br J Dermatol.* 2005 Jun;152(6):1339-42. PubMed PMID: 15949005.
- [4]. Shashikumar BM, Harish MR, Bhadbhade SP, Deepadarshan K. Cooks syndrome. *Indian J Paediatr Dermatol.* 2015 Apr 1;16(2):93.
- [5]. Padmavathy L, Kanthimathi B, Lakshmana Rao, Adaikappan M. Congenital anonychia affecting both little fingers-a "forme fruste" of cooks syndrome? A case report. 2016.