

**Chronic Cutaneous Blastomycosis**

Case Report

Rishi K. Gandhi<sup>1</sup>, Catherine A. Ulman<sup>2</sup>, Karl K. Kellawan<sup>3</sup>, Thomas G. Olsen<sup>3</sup>, Julian J. Trevino<sup>3</sup>, Smita Krishnamurthy<sup>4\*</sup>

<sup>1</sup> Department of Dermatology, University of Cincinnati, USA.

<sup>2</sup> Department of Dermatology, Ohio State University, USA.

<sup>3</sup> Department of Dermatology, Wright State University, USA.

<sup>4</sup> Departments of Dermatology and Pathology, Wright State University, USA.

**Abstract**

We present an interesting case of chronic cutaneous blastomycosis occurring in a 71-year-old veterinarian diagnosed by morphologic examination, highlighting the clinical presentation, morphologic appearance, and treatment of chronic cutaneous blastomycosis. This case emphasizes the importance of careful clinicopathologic correlation and morphologic examination in diagnosing cutaneous blastomycosis.

**Keywords:** Cutaneous Blastomycosis; Chronic Blastomycosis; Blastomyces Dermatitidis.

**\*Corresponding Author:**

Smita Krishnamurthy MD,  
Department of Pathology, Wright State University, 140 White Hall, 3640  
Col. Glenn Hwy, Dayton, OH 45435, USA.  
Tel: (937) 775-2625  
Fax: (937) 775-2633  
E-mail: smita.krishnamurthy@wright.edu

**Received:** September 01, 2015

**Accepted:** October 08, 2015

**Published:** October 12, 2015

**Citation:** Krishnamurthy S, et al., (2015) Chronic Cutaneous Blastomycosis. *Int J Clin Dermatol Res.* 3(4), 68-70. doi: <http://dx.doi.org/10.19070/2332-2977-1500018>

**Copyright:** Krishnamurthy S<sup>©</sup> 2015. This is an open-access article distributed under the terms of the Creative Commons Attribution License, which permits unrestricted use, distribution and reproduction in any medium, provided the original author and source are credited.

**Case Report**

A 71 year-old male veterinarian developed swelling and an erythematous eruption on his right 4<sup>th</sup> finger two weeks after receiving a puncture wound from the claw of a cat. The patient denied pain, pruritus, or ulceration, and review of systems was negative. Four weeks later, the patient developed tender right epicondylar lymphadenopathy. His primary care physician treated him empirically with multiple antibiotics including amoxicillin/clavulanic acid, doxycycline, and rifampin. His lymphadenopathy resolved; however, the rash persisted.

The patient presented to the dermatology clinic 20 months after the initial erythematous eruption. During this period, he performed an autopsy of a dog that died from pulmonary blastomycosis. At the time of presentation to the dermatologist, his past medical history was unremarkable. Physical examination showed a 3-cm erythematous, crusted plaque on the dorsal surface of his

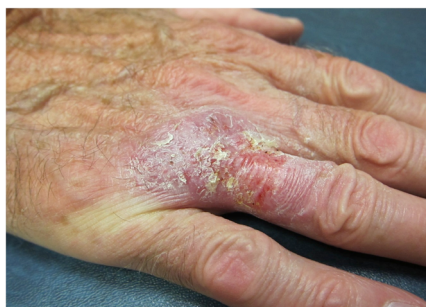right 4<sup>th</sup> metacarpophalangeal joint (Figure 1). The eruption did not improve after a two-week course of topical Clobetasol ointment, which initiated a more extensive workup. Since the initial clinical differential diagnosis was an eczematous process versus squamous cell carcinoma, tissue cultures were not obtained at the time of biopsy. Blood cultures for bacteria, fungi, and mycobacteria, complete blood count with differential, and purified protein derivative (PPD) tests were all unremarkable. A chest x-ray was normal, without evidence of parenchymal lesions or infiltrates. A hand x-ray was also normal, without evidence of osteomyelitis.

A deep shave biopsy of the finger lesion demonstrated pseudoepitheliomatous hyperplasia, intraepidermal and dermal abscesses, and mixed granulomatous inflammation, suggestive of an infectious process (Figure 2). A PAS stain revealed scattered 10 µm thick-walled yeasts with broad based budding (Figure 3). An acid-fast bacillus (AFB) stain was negative for mycobacterial organisms. The morphologic features including the large size of the yeasts with thick cellular walls and broad-based budding were consistent with blastomycosis. The patient was treated with oral itraconazole with significant improvement of cutaneous lesions within 3 weeks of therapy with only mild residual scarring.

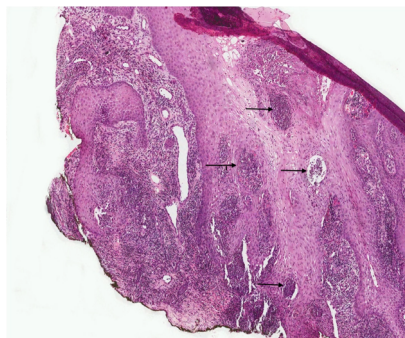
**Discussion**

Blastomyces dermatitidis is a thermally dimorphic fungus, which grows in mycelial form in soil, and yeast form in host tissue. It is endemic to the Great Lakes region and the Mississippi and Ohio River basins [1]. Transmission typically involves a 1-3 month incubation period from inhalation of conidia, with lymphovascular spread from a primary pulmonary infection [1, 2]. The skin is the most common site for dissemination, followed by bone, especially the long bones, ribs, and vertebrae, genitourinary tract, and central nervous system [3]. Cutaneous involvement occurs in approximately 40-80% of cases and skin lesions are typically verrucoid and dermatitic. Cutaneous involvement may manifest as papulopustular lesions, cutaneous ulcerations, or subcutaneous

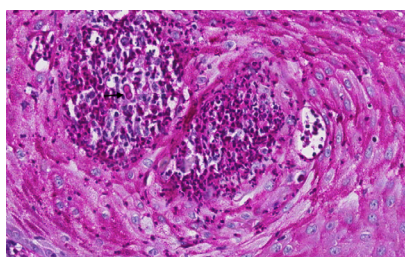
**Figure 1. Erythematous crusted plaque on the dorsal surface of the right 4<sup>th</sup> digit at initial presentation to the dermatology clinic 20 months after initial onset.**



**Figure 2. Shave biopsy specimen illustrating pseudoepitheliomatous hyperplasia, intraepidermal and dermal abscesses, and mixed inflammation (H&E stain, Original Magnification x5).**



**Figure 3. Non-encapsulated, 10 μm, thick-walled, broad-based budding yeasts within giant cells (PAS Stain, Original Magnification x20).**



nodules [1, 2, 4]. Common sites of cutaneous dissemination include the face and mucous membranes [4].

Adult males between the ages of 25 and 50 are most commonly affected, and the estimated incidence is 0.6 cases per million persons per year in the United States [2, 4]. The diagnosis of blastomycosis can be reliably made through morphologic examination of exudate, sputum, or tissue [5, 6]. Morphologic examination of blastomyces dermatitidis is diagnostic due to its characteristic size (8 to 15 μm), thick refractile cell wall, and the presence of broad-based budding yeasts [5, 6]. Additionally, morphologic diagnosis can be aided through the use of GMS and PAS stains [6]. Positive fungal culture can also provide a definitive diagnosis [1, 2]. However, studies have shown that cultures are only positive in 64% to 67% of blastomycosis cases, which supports the necessity of careful morphologic examination [5, 6]. There are serologic methods available for detection, but they have low sensitivity and specificity [3].

Primary cutaneous blastomycosis is very rare, and follows traumatic implantation of the fungus, which has been documented in lab or morgue workers, and from animal bites and scratches. Additionally, there have been documented case reports of blastomyces dermatitidis being transmitted percutaneously through accidental exposure during the autopsy of a patient with systemic

blastomycosis [7]. However, most cutaneous blastomycosis cases are secondary to spread from a subclinical pulmonary infection [3].

Clinically, primary cutaneous blastomycosis differs from disseminated cutaneous blastomycosis from a primary pulmonary infection. While disseminated cutaneous blastomycosis is characteristically more verrucous, primary cutaneous blastomycosis presents as a relatively painless, indurated, sometimes ulcerated lesion at the site of inoculation [3]. Additionally, unlike pulmonary blastomycosis, primary cutaneous blastomycosis is more likely to be associated with lymphangitis and localized lymphadenopathy [7].

In our case, although the presence of a non-verrucous plaque with localized lymphadenopathy lends support to the diagnosis of primary cutaneous blastomycosis, the possibility of secondary cutaneous blastomycosis with a subclinical pulmonary focus cannot be completely excluded [7]. Additionally, there are documented cases of transmission of blastomycosis during autopsy [5]; however, the lesion in our case was present for many months before the patient performed the autopsy, making this an unlikely source of his infection. The clinical differential diagnosis for cutaneous blastomycosis is wide and includes squamous cell carcinoma, other deep fungal infections (Coccidiomycosis, Cryptococcus), tuberculosis, lupus vulgaris, pyoderma gangrenosum, bromoderma,

and iododerma [2, 3, 8].

Oral antifungal agents aimed at eradication have demonstrated remarkable success [8]. In general, mild to moderate disease can be treated with itraconazole [1]. Itraconazole is generally better tolerated than Amphotericin B, which is used in treating life threatening disease, immunocompromised patients, pregnant patients, or in those with central nervous system involvement [1, 2, 8].

This case illustrates a chronic presentation of cutaneous blastomycosis, and emphasizes the importance of careful clinicopathologic correlation and morphologic examination in diagnosing cutaneous fungal infections [6].

## References

[1]. Watts B, Argekar P, Saint S, Kauffman CA (2007) Clinical problem solving. Building a diagnosis from the ground up-a 49-year-old man came to the clinic with a 1-week history of suprapubic pain and fever. *N Engl J Med*

356(14): 1456-1462.

[2]. Assaly RA, Hammersley JR, Olson DE, Farrouk A, Zaher A, et al. (2003) Disseminated blastomycosis. *J Am Acad Dermatol* 48(1): 123-127.

[3]. Mason AR, Cortes GY, Cook J, Maize JC, Thiers BH (2008) Cutaneous blastomycosis: a diagnostic challenge. *Int J Dermatol* 47(8): 824-830.

[4]. Weil M, Mercurio MG, Brodell RT, Elewski BE (1996) Cutaneous lesions provide a clue to mysterious pulmonary process. *Arch Dermatol* 132(7): 822,824-825.

[5]. Taxy JB (2007) Blastomycosis: contributions of morphology to diagnosis a surgical pathology, cytopathology, and autopsy pathology study. *Am J Surg Pathol* 31(4): 615-623.

[6]. Patel AJ, Gattuso P, Reddy VB (2010) Diagnosis of blastomycosis in surgical pathology and cytopathology: correlation with microbiologic culture. *Am J Surg Pathol* 34(2): 256-261.

[7]. Wilson JW, Cawley EP, Weidman FD, Gilmer WS (1955) Primary cutaneous North American blastomycosis. *AMA Arch Dermatol* 71(1): 39-45.

[8]. Chapman SW, Bradsher RW, Campbell GD, Pappas PG, Kauffman CA (2000) Practice guidelines for the management of patients with blastomycosis. *Clin Infect Dis* 30(4): 679-683.