

## Surgical Treatment Of Pseudarthrosis Of Carpal Scaphoid (About 30 Cases)

Review Article

M.Lahsika\*, S.Senhaji, A.Krite, H.Abid, M.El Idrissi, A. El Ibrahim, A. El Mrini

Department of Traumatology and Orthopedics,UHC Hassan II, Fez, Morocco.

### Abstract

Pseudarthrosis of the carpal scaphoid is the main complication of scaphoid fracture, which itself is a fracture that is most often overlooked. Its evolution inevitably leads to disabling term osteoarthritis of the wrist. The treatment is above all surgical. Among the multitude of techniques offered today, that of the cortico-cancellous graft of MATTI-RUSSE remains a benchmark. Between January 2013 and April 2021, we collected 23 cases of scaphoid pseudarthrosis with the aim of assessing the diagnostic conditions, studying the developmental stages and complications of scaphoid pseudarthrosis, and especially to evaluate the technique no longer used. The initial fracture was ignored in all cases with a mean age of non-union of 28.7 months at the time of diagnosis. All the patients benefited from the cortico-cancellous graft with or without osteosynthesis. The mean follow-up was 18 months with extremes of 2 months to 25 months. 21 patients consolidated unmistakably except in 2 patients with a short follow-up that did not allow a judgment to be made on the state of consolidation. The height and shape of the bone were anatomical in 7-18 patients. Overall, we have 78% excellent results and 13% good results, but a slight discrepancy was found between the objective result (85% excellent results) and the subjective result (96% excellent results). Two cases of preoperative DISI as well as 3 cases of decrease in the author of the carpus were taken into account during surgery as well as 5 cases of associated preoperative osteoarthritis. It is therefore necessary to be able to discuss other therapeutic means depending on the stage of development of the pseudarthrosis of the scaphoid.

**Keywords:** Carpalscaphoid pseudarthrosis; Nonunion, Surgery.

### Introduction

Scaphoid nonunion is the failure of a scaphoid fracture to heal after 6 months. This problem has attracted the attention of many authors for a long time, and continues to be the subject of frequent work [1, 2]. Five to ten percent of scaphoid carpal fractures do not permanently heal [1, 3], and untreated progress inevitably leads to osteoarthritis and functional degradation of the wrist due to pain, stiffness and loss of strength [4]. We report a series of 23 cases of pseudarthrosis of the carpal scaphoid, treated surgically in order to analyze the diagnostic, therapeutic and prognostic characteristics.

**Aim:** The aim of our study was to evaluate a series of non-union of the carpal scaphoid treated surgically.

### Material and Methods

Our work consists of a retrospective study of 23 cases of pseudarthrosis of the carpal scaphoid treated surgically. Adult patients with pseudarthrosis of the carpal scaphoid regardless of the initial treatment were included in our study. Patients were examined bilaterally and comparatively at both wrists, and this focused on pain, joint mobility and muscle strength. The radiological examination was also done bilaterally and comparatively comprising an X-ray of the wrists from the front and a X-ray of the front with the handle closed giving a spread view of the scaphoid allowed us to study the pseudarthrosis using the Alnot classification (Fig. 1) [3]. MRI was performed in a single patient to assess the viability of the proximal fragment. Our work consists of a retrospective study of 23 cases of pseudarthrosis of the carpal scaphoid treated surgically.

#### \*Corresponding Author:

Dr. Lahsika Mohammed,  
Resident, Department of Traumatology and Orthopedics,UHC Hassan II, Fez, Morocco.  
E-mail: mlahsika@gmail.com

**Received:** May 03, 2021

**Accepted:** December 22, 2021

**Published:** December 23, 2021

**Citation:** M.Lahsika, S.Senhaji, A.Krite, H.Abid, M.El Idrissi, A. El Ibrahim, A. El Mrini. Surgical Treatment Of Pseudarthrosis Of Carpal Scaphoid (About 30 Cases). *Int J Bone Rheumatol Res.* 2021;6(03):108-110. doi: <http://dx.doi.org/10.19070/2470-4520-2100023>

**Copyright:** M.Lahsika©2021. This is an open-access article distributed under the terms of the Creative Commons Attribution License, which permits unrestricted use, distribution and reproduction in any medium, provided the original author and source are credited.

## Results

Twenty-three carpal scaphoid pseudarthrosis were treated surgically. There were 7 women for 16 men (30.43% vs. 69.57%). The average age was 35 (between 21 and 57). The average time between fracture and graft was 27 months (between 4 months and 55 months). The fracture involved the body of the scaphoid in 87% of cases and in 9% of cases the proximal pole. Using the ALNOT classification we found 56.52% stage I, 39.13% stage IIA, 21.73% stage IIB, and 13.04% stage IIIA.

All the patients were operated on by the MATTI-RUSSE technique and in 2 patients a preoperative DISI was reducible and fixed with a provisional radiolunar pin using the Cooney technique [5]. The graft was stabilized by internal fixation in all patients, Herbert screwing in 22 cases, pinning in 1 case. The mean follow-up was 18 months with extremes of 2 months to 25 months. 21 patients consolidated unmistakably except in 2 patients with a short follow-up that did not allow a judgment to be made on the state of consolidation.

The mean follow-up was 18 months (between 2 months and 25 months). 17 patients no longer presented with pain. The other 6 had mild pain once or twice during the month or after heavy labor. Postoperative joint mobility was improved in 19 patients, the mean range of motion increased from 60°/50° preoperatively to 80°/60° postoperatively. 91% of our patients were able to resume their activities. As for grip strength, its assessment was primarily subjective, based on patient reports, and was generally satisfactory.

Obvious radiological union was obtained in 21 cases (91.30%) with a mean delay of 11 weeks (between 6 and 14 weeks) (Fig 2, 3).

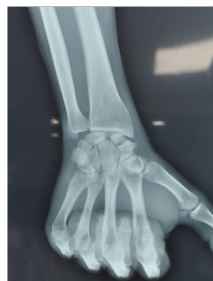Among the 2 cases of DISI (Dorsal intercalated segment instability) found preoperatively with a radiolunar angle measured at 22 °, radiological consolidation without DISI was obtained. The carpal height was restored in the 3 patients who presented a preoperative decrease. Analysis of the radiographic images revealed 5 cases of radioscapolunate osteoarthritis, which remained stationary, with no notable radiological evolution after 25 months of follow-up. The diagnosis of the initial fracture was unrecognized in 10 patients (43.47%). Taking into account the Mayo clinic score according to Alnot stages, the overall functional results are summarized in Table I.

## Discussion

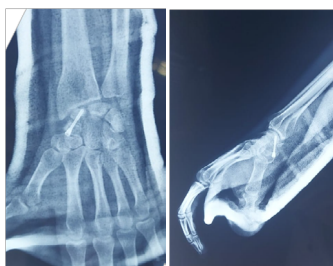The diagnosis of pseudarthrosis of the scaphoid does not seem to pose a problem, unlike that of the initial fracture, which should always be borne in mind in front of any traumatic wrist, even if it is not deformed and asymptomatic.

Overall, any non-union, even asymptomatic one, should be treated, as it will inevitably progress to worsening over time [1, 6]. Its treatment is difficult and controversial [1, 5, 7, 8]. However, there are several therapeutic methods of which it is necessary not only to master the technique but also to know the indication according to the evolutionary stage of the lesions [8]. The corticosteroid-

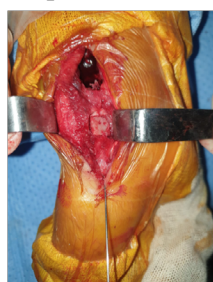
**Figure 1. Frontal wrist x-ray showing pseudarthrosis.**



**Figure 2. Postoperative control x-ray of a MATTY RUSSE procedure.**



**Figure 3. Intraoperative image showing a cortico-cancellous graft in place. We found 1 case of proximal pole necrosis which refused reoperation.**



**Table 1. Overall functional results (Mayo Clinic Score) by Alnot stage.**

	Stage I	Stage IIA	Stage IIB	Stage IIIA	TOTAL
Bad				1	1
Intermediary			1		1
Good	2	1			3
Excellent	10	6	1	1	18
TOTAL	12	7	2	2	23

cancellous graft according to the Matty-Russe technique is a good technique that gives good results provided you follow a few rules [5-7, 9]:

- Iliac harvest.
- Good stabilization of the graft and the carpal scaphoid by stable osteosynthesis.
- Wrist immobilization until final consolidation (3 months).

The use of a vascularized bone graft is a good treatment for small loss of substance from the carpal scaphoid. Its use was first proposed for the treatment of necrosis of the proximal pole, a questionable indication; and for the treatment of failures of classical techniques [2, 4]. However, this graft is technically more difficult to make than a conventional graft [5].

Several series in the literature show great variability in relation to the rate of union between non-vascularized and vascularized grafts. Nevertheless, in view of the literature and the meta-analysis by Ditsios K and Merrell, vascularized grafts seem to be the most logical and most suitable solution in cases of necrosis of the proximal pole [3].

## Conclusion

Pseudarthrosis of the carpal scaphoid are lesions of often late discovery. The therapeutic indications depend on the anatomopathological classification. Hence the value of treating recent pseudarthrosis. The results depend on the stage of development and the type of treatment.

## References

- [1]. Kalb K, Pillukat T, Jonke B, Schmidt A, van Schoonhoven J, Prommersberger KJ. Scaphoid non-union: Experience from more than 280 reconstructions using a medial femur condyle bonegraft. *Handchir Mikrochir Plast Chir.* 2020 Sep;52(5):425-434. PubMed PMID: 32992393.
- [2]. Tphreopousrgdic A, Scaphoid C. LE TRAITEMENT CHIRURGICAL DES PSEUDARTHROSES DU n.d.:7.
- [3]. Alnot JY, Bellan N, Oberlin C, De Cheveigné C. Les fractures et pseudarthroses polaires proximales du scaphoïde carpien. *Ostéosynthèse par vissage de proximal à distal.* *Ann Chir Main.* 1988;7:101-8.
- [4]. Fodor SG, Christopoulos G, Lehmkühl L, Prommersberger KJ, Mühldorfer-Fodor M. Clinical and imaging methods in diagnostics of scaphoid fracture and non-union. *Handchir Mikrochir Plast Chir.* 2020 Sep;52(5):382-391. PubMed PMID: 32992395.
- [5]. Cooney WP 3rd, Dobyns JH, Linscheid RL. Nonunion of the scaphoid: analysis of the results from bone grafting. *J Hand Surg Am.* 1980 Jul;5(4):343-54. PubMed PMID: 6999072.
- [6]. Kastenberger T, Kaiser P, Bode S, Horling L, Schmidle G, Arora R. Treatment of scaphoid non-union: vascularised iliac crest graft or medial femur condyle graft? *Handchir Mikrochir Plast Chir.* 2020 Sep;52(5):419-424. PubMed PMID: 32992398.
- [7]. Mühldorfer-Fodor M, Wagner M, Kottmann T, van Schoonhoven J, Prommersberger KJ. Comparison of scaphoid reconstruction with a non-vascularised bone graft, with and without shockwaves; preliminary results. *Handchir Mikrochir Plast Chir.* 2020 Sep;52(5):404-412. PubMed PMID: 32992391.
- [8]. Bürger H, Gaggli AJ, Kukutschki W, Müller EJ. Free microvascular transfer of segmental corticocancellous femur for the treatment of scaphoid nonunion. *Oper Orthop Traumatol.* 2009 Nov;21(4-5):396-404. PubMed PMID: 20058119.
- [9]. Hegazy G, Alshal E, Abdelaal M, Abdelaziz M, Moawad M, Saqr YM, et al. Kirschner wire versus Herbert screw fixation for the treatment of unstable scaphoid waist fracture nonunion using corticocancellous iliac bone graft: randomized clinical trial. *Int Orthop.* 2020 Nov;44(11):2385-2393. PubMed PMID: 32683460.