

Custom Insert for Dysplastic Glenoid in Reverse Total Shoulder Arthroplasty

Case Report

Samona J^{1*}, Owen J², Martin S³

¹ McLaren Regional Medical Center, Orthopaedic Surgery Department, S. Ballenger Highway, Flint, MI, USA.

² The Feinberg School of Medicine, Northwestern University, Chicago, IL, USA.

³ McLaren Flint, Hurley Medical Center, and Genesys Regional Medical Center, Flint, Michigan, USA.

Introduction and Review of the Literature

Arthritis is the leading cause of disability in the US workforce, leading to debilitating limitations with mobility and function in an otherwise healthy adult. In 2005, 21.6% of US adults (46.4 million) were formally diagnosed with arthritis, and by 2030 is projected to reach 40% (~67 million) [1-3]. A high correlation exists between age and the presence of rotator cuff disease and glenohumeral arthritis. The average age of individuals with unilateral cuff tears is 58.7, 67.8 years for those with bilateral, and 50% likelihood of a bilateral tear after age 60. It is estimated 13% of patients in their fifties suffer from a cuff tears and 54% of patients 60 years or older, with more than half of asymptomatic rotator cuff tears progressing in size and becoming symptomatic within 3 years [4-6]. After the knee, the shoulder is the second most common site of chronic joint pain (63.4% vs. 30.6%) [7]. Shoulder arthroplasty accounted for 3% (vs. 96% for hip and knee) of all inpatient arthroplasty procedures performed in 2006. An increase of 2.5x (from 19,000 to 47,000) in the number of shoulder arthroplasties in the United States occurred between the years of 1998 to 2008, more than 2/3 performed on patients older than age 65 [8]. These numbers are significant because trends show between 2012 and 2050 the US will experience a considerable increase in the proportion of the elderly population. 39.6 million people 65 years or older were living in the US in 2009, representing 12.9% of the population or approximately one in every eight Americans. An estimate of 43.1 million in 2012, compared to 72.1 million in 2030 (19% of the population, more than twice that in 2000), and 83.7 million projected in 2050 [9]. As these numbers grow, the prevalence of rotator cuff arthropathy will follow. In combination with a larger pool of patients, the higher level of activity most older individuals enjoy in current times will surely increase the demand for surgical intervention to alleviate the debility of the aforementioned pathology. This rise in the patient population will increase the number of cases with aberrant anatomy and new tools need

to be developed to deal with these current and future challenges.

The use of (RTSA) reverse total shoulder arthroplasties have skyrocketed in the past decade, in large part due to the success levels and enlarging list of indications. 96% of post operative patients report no or minimal pain and significant improvements [10]. Surgical indications include certain proximal humerus fractures and malunions in elderly patients, pseudoparalysis secondary to irreparable rotator cuff tear in the setting of glenohumeral arthritis, an incompetent coracoacromial arch (humeral "escape" in subcutaneous tissue with hemiarthroplasty), intact bony acromion, low functional demand patients, sufficient glenoid bone stock, physiological age >70, working deltoid muscle (intact axillary nerve), and patients who are poor candidates for conventional shoulder arthroplasty.

Difficulty arises in the setting of patients with eccentric glenoid wear and compromised bone stock with symptomatic rotator cuff arthropathy in candidates for RTSA. On the basis of the existing data, patients undergoing conventional TSA with 10° to 15° of retroversion can be treated with eccentric reaming and use of a glenoid implant, compared to 15° to 25° of retroversion usually can be treated with a combination of slight eccentric reaming, bone grafting, or a posterior augmented implant, verse over 25°.

Of retroversion which is a difficult treatment dilemma. Over the past 5-10 years the use of custom made implants based on CT scans has becoming ever popular for the treatment of patients with increasing degrees of version. This has been done in the realm of conventional TSA on numerous occasions, but only 2 cases have been found from a computer search in terms of these custom implants used for RTSA. One case advertised on YouTube was in the setting of a 2 stage revision in which a conventional TSA was exchanged for antibiotic spacer, and ultimately a custom glenoid implant was inserted for conversion to a RTSA

*Corresponding Author:

Jason Samona DO,
Orthopaedic Surgery Department, McLaren Regional Medical Center, 401 S. Ballenger Highway, Flint, MI 48532, USA.
Tel: 248.939.6263
Fax: 810.342.2150
E-mail: Jasonsamona@yahoo.com

Received: October 04, 2016

Accepted: December 06, 2016

Published: December 07, 2016

Citation: Samona J, Owen J, Martin S (2016) Custom Insert for Dysplastic Glenoid in Reverse Total Shoulder Arthroplasty. *Int J Bone Rheumatol Res.* 3(8), 62-64.
doi: <http://dx.doi.org/10.19070/2470-4520-1600013>

Copyright: Samona J[©] 2016. This is an open-access article distributed under the terms of the Creative Commons Attribution License, which permits unrestricted use, distribution and reproduction in any medium, provided the original author and source are credited.

[11]. Another case was in the setting of a previous complex proximal humerus fracture with subsequent infections and insertion of antibiotic spacers, ultimately resulting in prolonged debility and eventual use of a custom glenoid implant with anterior augmentation for a RTSA [12]. This case report is in the setting of a primary RTSA in the setting of posterior augmentation for severe glenoid retroversion (greater than 25 degrees) with limited bone stock. Lower outcome scores are expected for patients undergoing revision TSA secondary to infection and multiple open surgical procedures on the shoulder [13-15]. Therefore, it is difficult to determine the effectiveness of these implants based on the confounding variables of previous infection and repeat surgical intervention.

Case Report

81 year old male with a history of chronic bilateral shoulder pain from rotator cuff arthroplasty had undergone non operative treatment via intra-articular steroid injections and physical therapy, which was unsuccessful in alleviating his pain. After failure of non operative treatment, the patient decided to undergo operative treatment. Proper physical exam, patient history, and advanced imaging revealed incompetent supraspinatus tendon, as well as severe retroversion of the glenoid of the effected shoulder (see image 1 and 2). During the preoperative process, the choice of a reverse total shoulder arthroplasty was determined to be the ideal construct. The retroversion of the glenoid was greater than 25 degrees, and the bone stock was minimal. Choices for eccentric reaming for placement of the base plate of the glenosphere was not the ideal option, and the through of bone grafting was enter-

tained. Due to minimal bone stock and the technical difficulties associated with such a procedure, the option for a custom glenoid base plate with a posterior augment was deemed the best option. The patient underwent the procedure without any complications, and proceed with an uneventful post operative course. At the time of the shoulder grading, the patient claimed the procedure had significantly improved his previous symptoms of discomfort and debility, and was very pleased with the outcomes of the procedure.

Discussion

This case is unique in that the patient received a custom baseplate with a posterior augment for a dysplastic glenoid, in someone who had never undergone previous surgical intervention to the shoulder in question and no confounding variable of previous infection (see image 3 and 4). Also, the previous reports do not quantify the outcomes of the patients in terms of shoulder scores which have been commonly used in the past to determine level of function/pain. Such scores have been used in the past to grade both TSA and RTSA, which include; DASH score, (Western Ontario Osteoarthritis of the Shoulder [WOOS] index), general shoulder rating scales (University of California at Los Angeles [UCLA] shoulder scale, Constant score, and American Shoulder and Elbow Surgeons [ASES] evaluation form), general pain scales (McGill pain score and visual analogue scale), and a global health measure (Short Form-36 [SF-36]) [16]. This case is unique in that we have produced a positive patient's outcome, therefore giving insight into treatment success of patients in a similar setting.

Image 1. Pre-Operative Imaging of the Shoulder in Question. Left: Arthrogram, Pre and Post Contrast. Bottom Left: CT Reconstruction. Bottom Right: Axial CT Slice Demonstrating Glenoid Retroversion with Dysplasia.

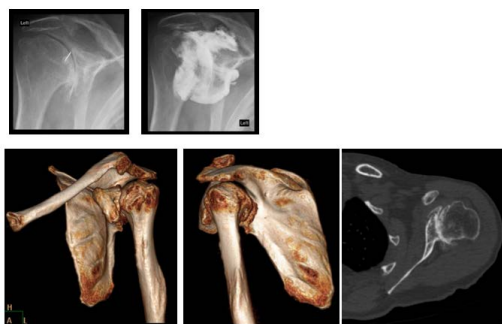


Image 2. Pre-Operative CT Reconstruction of the Shoulder in Question, used as a Template for the Creation of the Custom Implant.

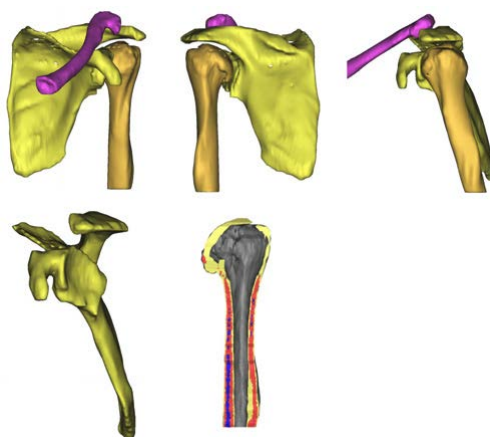


Image 3. Surgical Guide for Implantation of Custom Implant (Special Thank you to Biomet Corp. of Warsaw, Indiana).

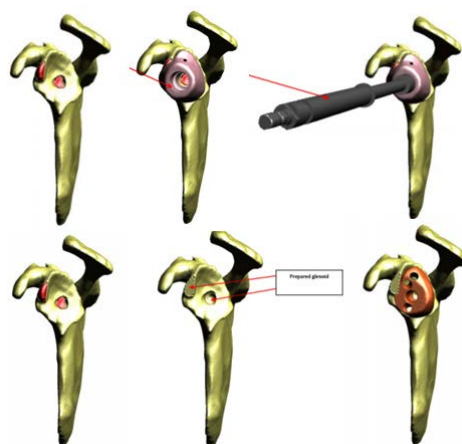
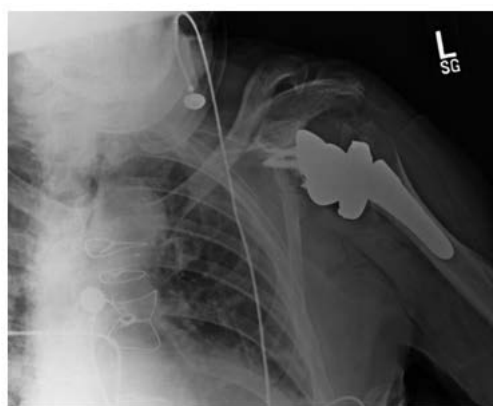

Image 4. Post Operative Plain Films.



The utility of this device is preservation of what little bones stock patients in this situation already have, and it allows for a much less technically demanding procedure to correct for glenoid version. Based on the initial success seen with this procedure, this implant appears to have promising results. We recommend further use of this product and call for increased research into the field as more patients receive this implant. With the rising tide of elderly individuals in the population, along with the high incidence and debilitating nature of rotator cuff arthropathy, these implants provide a viable option to treat the complex assortment of anatomy which conventional surgical methods are a non-viable option.

References

- [1]. Stoddard S, Jans L, Ripple J, Krause L (1998) Chartbook on work and disability in the United States. In An InfoUse Report. Washington DC: U.S. National Institute on Disability and Rehabilitation Research.
- [2]. Centers for Disease Control and Prevention (CDC) (2001): Prevalence of disabilities and associated health conditions among adults-United States, 1999. *MMWR Morb Mortal Wkly Rep.* 50(7): 120-125.
- [3]. Hootman JM, Helmick CG (2006) Projections of US prevalence of arthritis and associated activity limitations. *Arthritis Rheum.* 54(1): 226-229.
- [4]. Sher JS, Uribe JW, Posada A, Murphy BJ, Zlatkin MB (1995) Abnormal findings on magnetic resonance images of asymptomatic shoulders. *J Bone Joint Surg Am.* 77(1): 10-15.
- [5]. Tempelhof S, Rupp S, Seil R (1998) Age-related prevalence of rotator cuff tears in asymptomatic shoulders. *J Shoulder Elbow Surg.* 8(4): 296-299.
- [6]. Yamaguchi K, Tetro AM, Blam O, Evanoff BA, Teefey SA, et al., (2001) Natural history of asymptomatic rotator cuff tears: a longitudinal analysis of asymptomatic tears detected sonographically. *J Shoulder Elbow Surg.* 10: 199-203. doi: 10.1067/mse.2001.113086.
- [7]. Anderson G, American Academy of Orthopaedic Surgeons (2008) *The Burden of Musculoskeletal Disease in the United States: Preevalence, Societal and Economic Cost.* Rosemont, IL : American Academy of Orthopaedic Surgeons.
- [8]. Kim SH, Wise BL, Zhang Y, Szabo RM (2011) Increasing Incidence of Shoulder Arthroplasty in the United States. *J Bone Joint Surg Am.* 93(24): 2249-54.
- [9]. Administration on Aging (AoA). Administration for Community Living. February, 2015. http://www.aoa.acl.gov/Aging_Statistics/index.aspx.
- [10]. Sirveaux F, Favard L, Oudet D, Huquet D, Walch G, et al., (2004) Grammont inverted total shoulder arthroplasty in the treatment of glenohumeral osteoarthritis with massive rupture of the cuff. Results of a multicentre study of 80 shoulders. *J Bone Joint Surg Br.* 86(3): 388-95.
- [11]. Available at: <https://www.youtube.com/watch?v=ytw1LRDzHm8>, February 24, 2015.
- [12]. *Techniques in Shoulder & Elbow surgery, Introducing clinical surgery,* June 2014.
- [13]. Strickland JP, Sperling JW, Cofield RH (2008) The results of two-stage re-implantation for infected shoulder replacement. *J Bone Joint Surg Br.* 90(4): 460-5.
- [14]. Dines JS, Fealy S, Strauss EJ, Allen A, Dines DM, et al., (2006) Outcomes analysis of revision total shoulder replacement. *J Bone Joint Surg Am.* 88(7): 1494-500.
- [15]. S Slimani, H Coudane, D Marçon, E Lesure (2002) Long-Term Prospective Analysis Of Revision Total Shoulder Arthroplasties. *Orthopaedic Proceedings.* http://www.bjjprocs.boneandjoint.org.uk/content/84-B/SUPP_I/41.
- [16]. Lo IK, Litchfield RB, Griffin S, Faber K, Patterson SD, et al., (2005) Quality-of-life outcome following hemiarthroplasty or total shoulder arthroplasty in patients with osteoarthritis. A prospective, randomized trial. *J Bone Joint Surg Am.* 87(10): 2178-85.