

The Highly Variable Typologies of Posterior Malleolus Fractures of the Ankle

Research Article

Ren Wei^{1,3}, Masumi Mauro Holledge¹, Hu Yongcheng^{2,3}, Jike Lu^{1*}

¹ Department of Orthopedic Surgery, United Family Hospital, No.2 Jiangtai Lu, Chaoyang District, Beijing, China.

² Department of Foot and Ankle Surgery, Tianjin Hospital, No. 406, Jie Fang Nan Lu, He Xi District, Tianjin, China.

³ Tianjin Medical University, No.22, Qi Xiang Tai Lu, He Ping District, Tianjin, China.

Abstract

Objectives: Although historical studies frequently classify posterior malleolus fractures (PMFs) according to fragment size, our hypothesis is that PMFs have more complex patterns than is widely recognized. None of the studies so far have provided a comprehensive picture of the complexity of PMFs or guidelines for surgical decision making. The optimal management of PMFs is still unclear. This study aims to look at the typology of PMFs using a combination of initial injury radiographs, preoperative computed tomographic (CT) scans, and intra-operative image intensifier (II) screening, as well as fixation technique and a surgery fixation approach, in order to gain insight into PMFs.

Methods: Between 2013 and 2015, 56 consecutive patients, all with bi- or tri-malleolar fracture or dislocation of ankle joints, with one or more posterior fragments, who were treated at our institute, were identified. We retrospectively analysed the patients' preoperative initial injury radiographs, CT scans, and II data to see the stability of the ankle joints in coronal and sagittal planes, and look at the typology in relation to fracture fixation technique and surgery fixation approach.

Conclusions: Bi- or tri-malleolar fractures of the ankle with associated posterior malleolar fractures appear to be highly variable. We identified certain types of PMFs which we can categorise. Ankle stability in the coronal and sagittal planes on initial injury radiographs, intra-operative II and preoperative CT scans are critical in order to identify different PMFs patterns. PMFs have highly variable typology regardless of fragment size and this must take into consideration when deciding treatment plans.

Keywords: Posterior Malleolus; Tri-Malleolar Ankle Fracture; Type and Pattern; Stability of Ankle; Internal Fixation.

Introduction

Posterior malleolus fractures (PMFs) are relatively common ankle injuries. The most common of these are tri-malleolar ones with an incidence of approximately 7-14.2% [1, 2]. Isolated fractures of the postero-lateral tibial lip (Volkman's triangle) are rare, with an estimated incidence of 0.5-1% [1, 3, 4]. PMFs have also been associated with tibial shaft fractures, with an incidence of 1-25%, but which still appears to be underestimated in the literature [3, 4].

The posterior malleolus plays an integral role in ankle joint stability through its anatomical relationship with the posterior inferior tibio-fibular ligament (PITFL). This has been demonstrated through cadaver studies to contribute 42% to syndesmotic stabil-

ity [5, 6]. Ankle fractures involving the posterior malleolus are said to have worse clinical outcomes because of articular surface incongruity and the resultant development of post-traumatic arthritis [5]. However there is no consensus on how to best evaluate ankle stability following fracture, either radiologically or clinically. There is no clear guide to deciding the best way to reduce and stabilise the posterior malleolus. Although historical studies classify PMFs according to fragment size, none of the studies so far have provided a comprehensive picture of the complexity of PMFs. Our hypothesis is that PMFs show more variety in patterns than is widely recognized. This unrecognised complexity mitigates against the optimum management of PMFs. This study aims to look at the typology of PMFs using a combination of initial injury radiographs, preoperative computed tomographic

*Corresponding Author:

Jike Lu,
Professor, Department of Orthopaedics, United Family Hospital, Beijing, 2 Jiangtai Lu, Chaoyang District, Beijing, 100016 China.
Tel: +86-13911095602
Fax: +86(10) 59277200
E-mail: 13911095602@163.com

Received: May 28, 2016

Accepted: July 07, 2016

Published: July 08, 2016

Citation: Ren Wei, Masumi Mauro Holledge, Hu Yongcheng, Jike Lu (2016) The Highly Variable Typologies of Posterior Malleolus Fractures of the Ankle *Int J Bone Rheumatol Res.* 3(4), 38-45. doi: <http://dx.doi.org/10.19070/2470-4520-160009>

Copyright: Jike Lu © 2016. This is an open-access article distributed under the terms of the Creative Commons Attribution License, which permits unrestricted use, distribution and reproduction in any medium, provided the original author and source are credited.

(CT) scans, and intra-operative II screening in order to gain more insights into PMFs.

Material and Methods

Ethical approval for the study was obtained from two institution review boards. These were a tertiary level major trauma centre and a rural referral hospital. All images and operative notes for all patients, who underwent ankle operative fixation in the three institutions between June 2013 to September 2015, were reviewed.

We retrospectively analysed plain pre-operative radiographs, CT scans, preoperative planning, and those with a dislocation or subluxation had an additional post-reduction radiograph, prior to surgical fixation. Patients who had a PMF or PITFL injury, irrespective of posterior malleolar fixation, were included in the study. Patients with comminuted plafond injuries were excluded from the study. Pre-operative radiographs, prior to operation and post reduction of fracture, were reviewed. CT scans were analysed to shed more light on the fracture patterns and for evidence of syndesmotic injury. We analysed the various fracture patterns of the PMFs, and their Pilon variants, separated into different patterns whenever possible. Indications for ORIF as per the radiographs and CT scans were noted, including the fragment ratio and articular impaction of the PMFs. The type of fixation as shown by intra-operative and postoperative radiographs and patient operative notes was also analysed.

Preoperative initial injury radiographs were divided into fracture patterns which included the following: 1) evidence of dislocation or subluxation of the talus in the coronal and/or sagittal plane; 2) evidence of any syndesmotic widening in AP and mortise views; 3) presence of the double contour sign, indicating a postero-medial fragment; 4) articular fragment size; and 5) associated fibula fracture as per Weber classification. CT scans were also used in assessing syndesmotic injury, indicated by widening of the syndesmosis anteriorly, or posteriorly, on the axial scans. Other important information obtained on CT was related to articular impaction or depression.

Subsequently, a combination of initial injury plain radiographs and CT scans were put into different groups of PMFs, as well as recording what kind operative management was done. The system was partly based on the CT classification proposed by Haraguchi et al., [8] The initial injury radiographs of AP, lateral, and mortise views were used to classify the fibula fractures as per the Danis [9], Weber [10] and Lauge-Hansen [11] classifications. The classification of PMFs based on CT scans is presented in Table 1.

An extensive literature search was then performed, using the MEDLINE (1996 to present), PubMed and Cochrane databases of systematic reviews, to find journal articles referring to posterior malleolar fractures. Keywords used were ankle fractures, trimalleolar, posterior malleolus, outcome, and internal fixation. Search results were limited to humans and articles in the English language.

Results

Out of the 56 patients, 24 were male and 32 female. The average age was 48.83 years (range, 14 to 86). Of these, all patients had a pre-operative CT to assess fracture pattern, and 38 patients had internal fixation of the posterior malleolus, associated with lateral and/or medial malleolar fixation. Choice of fixation varied, with plate fixation being the most popular (34 out of 56 patients). Screw fixation of the PM was seen in 16 patients, while 6 patients had a combination of plate and screw fixation. A postero-lateral approach was used in 44 patients, and postero-medial approach in 5 patients. A combination of postero-medial and postero-lateral approach was utilised in 7 patients.

In this study of 56 patients, 25 cases were postero-lateral oblique fracture (PL), 7 cases were postero-medial-anterior (PMA) fracture, 11 cases were postero-lateral (PL) fracture extending to postero-medial (PM) fracture (PL + PM), and 13 cases were posterior rim (PR) fracture patterns (Table 1).





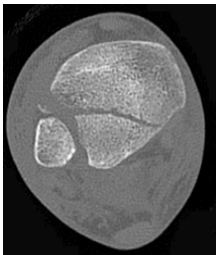
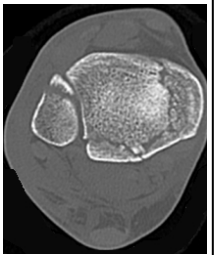
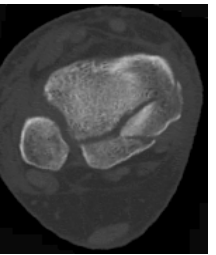
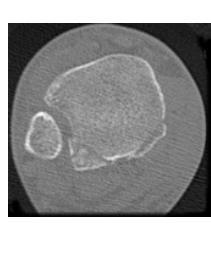
We subsequently used the following modifiers to further classify the PMFs: 1) presence of syndesmotic injury as determined by pre-operative initial injury radiographs, CT or intra-operative II screening, 2) presence of associated fibula fracture, classified as per Danis [9], Weber [10] and Lauge-Hansen [11], 3) evidence of sagittal or coronal plane instability, as determined by preoperative radiographs and CT, particularly noting any evidence of tibio-talar subluxation or dislocation on the sagittal/coronal plane (Table 2).

This can be summarised as follows: Type I fractures include some isolated PMFs or PMFs with non-displaced malleoli fractures. The point of this Type I Typology of PMFs are those in which non-displaced medial or lateral malleolus fractures may be present. In Type I, sagittal or coronal plane instability on initial injury radiographs were categorised as no sagittal or coronal plain instability (Type IA) and with sagittal or coronal instability (Type IB). These were further sub-classified depending on the fracture pattern noted on CT (as per the classification system mentioned above) as A1, A2, B1, and B2. I-A1 were solely posterior rim or PITFL injuries. These did not require surgical management for PMFs, unless there was a syndesmosis instability under II screening but this was unlikely. I-A2 fractures were PMFs of displaced PL, PMA, PL+PM on CT scans. Although there were no sagittal or coronal plane instabilities, and no displaced malleoli fractures, these displaced PMFs were fixed surgically. I-B1 were either non-displaced PMFs or PR types, and they did not require surgical fixation of the PMFs, even though there were sagittal or coronal plane instabilities. I-B2 were displaced PMFs of PL, PMA, PL+PM which were managed surgically by fixation.

Type II fractures include either bi or tri-malleolar fractures associated with a Weber B (A), or Weber C (B), fracture pattern. These were further classified depending on the presence or absence of syndesmotic injury. In IIA2 and IIB2, usually syndesmotic diastasis was present (checked either on initial injury radiographs, or intra-operative II), therefore, syndesmosis fixation was compulsory, in addition to PMF fixation. When the PMF height was less than 1 cm, fixation with plate or screws was not achievable, and those cases were managed by syndesmosis screws.

Type III are PM fractures associated with an ipsilateral tibial diaphyseal fracture. They are further subdivided into two. Type IIIA

Table 1. A combination of initial injury plain radiographs and CT scans were used to see a typology of the PMFs. The system was partly based on the CT classification proposed by Haraguchi et al., [8].

Type	PL	PMA	PL+PM	PR
(% Total 56 cases)	44.5% (25 Cases)	12.5% (7 Cases)	20% (11 Cases)	23% (13 cases)
PMF Features	Posterolateral (PL) oblique fracture line	Postero-medial-anterior (PMA) fracture line	Postero-lateral (PL) fracture extending to postero-medial (PM), fracture line parallel to transmalleolus axis, usually fragment split at the middle	Posterior rim fracture (PR)
Initial plain radiograph				
Axial CT at syndesmosis				

include cases with no sagittal or coronal plane instability and PR type. These cases can be managed without fixation of the PMFs. Type IIIB is for surgical fixation of PMFs of PL, PMA, PL+PM type with more than a 2 mm articular step-off, if they are unable to be reduced closely, or with sagittal instability.

In terms of the fixation of the PMFs, our preferred method involves two or three screws in a parallel position to enhance the lag screw effect. An inverted triangular configuration of the lag screw placement was most commonly used in our cases. Postero-lateral fractures can be fixed using a postero-lateral approach. Presence of an additional posteromedial fragment may require an additional postero-medial approach.

If AP radiographs showing the double contour sign indicated an additional posteromedial fragment, we did CT evaluation, in order to ascertain the exact fracture pattern, its displacement and comminution, articular impaction and fragment size.

In most PMF cases, the PITFL tends to stay intact. Therefore, with secure fixation of the PMFs, we can stabilise the syndesmosis [12, 13]. However we recommend that intra-operative screening, under image intensifier, should always be performed after stabilising the PMFs to rule out any possibility of occult syndesmotic diastasis. This is because there are similar tri-malleolar fractures. We found that IB2 and IIA2 had different degrees of syndesmosis diastasis involvement.









Discussion

This study showed variables in size and location of PMFs. We categorised different PMFs types, based on a combination of initial injury radiographs, pre-operative CT scans, and intra-operative II screening. Haraguchi et al., [8] classified PMFs, based on the orientation of the fracture line, as postero-lateral oblique type (67%), medial-extension type (19%), and small-shell type (14%). Based on our assessment of PMFs, we can also detect postero-lateral fractures extending postero-medially (PL+PM 12.5%) (Table 1). On top of this additional 4th type, we further made a classification including correlating types B and C of the Danis-Weber system (Table II), and separated PMFs with diaphysial fracture of ipsilateral tibia, such as Type III, altogether making 10 subtypes.


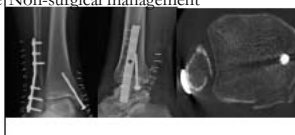






In order to see the typology of PMFs, we utilised a combination of initial injury radiographs, pre-operative CT scans, and intra-operative II screening. This combination of diagnostic tools makes categorisation more complicated. Conventional plain radiography (i.e. AP, mortise, and lateral) is necessary in the primary diagnosis and estimation of fragment size, especially with a fracture of the dorsal tibial margin, which is best seen in the standard lateral view [17]. Although a lateral view with external rotation of the ankle may help increase diagnostic yield [18], plain radiographs of the ankle may underestimate the size of the fragment, and make it difficult to estimate the percentage of the joint surface affected.

Table 2. We utilised typology of Figure 1 and modified to further classify the PMFs: 1) presence of syndesmotic injury as determined by pre-operative initial injury radiographs, CT scan, or intra-operative II screening, 2) presence of associated fibula fracture classified and 3) evidence of sagittal or coronal plane instability, particularly any evidence of tibio-talar subluxation or dislocation on the sagittal plane. This new, modified classification system can be used to decide the management of the PMFs.

Type 1: PMFs with or without non-displaced malleoli fractures.

A		No Sagittal plane instability	
IA1	PR type of PITFL injury alone		Non-surgical management or fixation of syndesmosis after intra-operative II screening
			
IA2	displaced PL, PMA, PL+PM type and failed closed reduction		Surgical fixation
			
B		Sagittal plane instability	
IB1	Non-displaced PMFs or PR type		Non-surgical management
			
IB2	displaced PL, PMA, PL+PM type		Surgical fixation
			

Type 2: displaced bi- or tri-malleolar fractures with sagittal plane instability.

A		Weber B lateral malleolar fracture	
IIA1	Without syndesmotic diastasis or RP type		Non-surgical management
			
IIA2	Syndesmotic diastasis, and/or displaces PL PMA, PL+PM type		Surgical fixation +/- Syndesmosis fixation
			
B		Weber C lateral malleolar fracture	
IIB1	Without syndesmotic diastasis or Non displaced PMFs or RP		Non-surgical management
			
IIB2	Syndesmotic diastasis, and/or displaces PL PMA, PL+PM type		Surgical fixation +/- Syndesmosis fixation
			

Type 3: PMFs with diaphysial fracture of ipsilateral tibia.

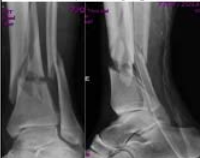

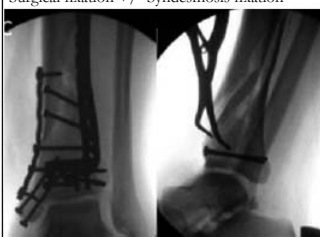
<p>IIIA</p>	<p>PR type, no sagittal and coronal instability on initial injury radiographs or intra-operative. LI</p> 	<p>Non surgical management</p>
<p>IIIB</p>	<p>PI, PMA, PL+PM type with > 2 mm articular step, unable to be reduced closely or with sagittal instability</p> 	<p>Surgical fixation +/- Syndesmosis fixation*</p> 

Figure 1. Our preferred method to fix PMFs is an inverted triangular configuration of the lag screw placement.

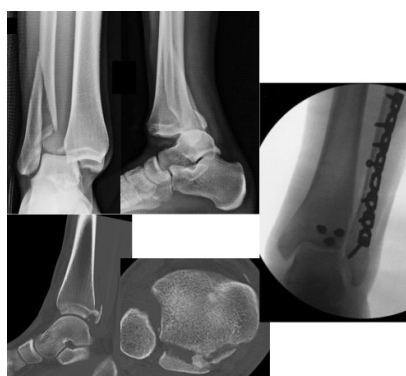

Figure 2. AP radiographs showing the double contour sign indicate an additional postero-medial fragment. The postero-medial fragment was fixed by our novel postero-medial approach.

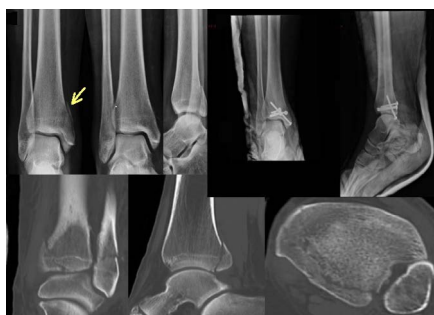
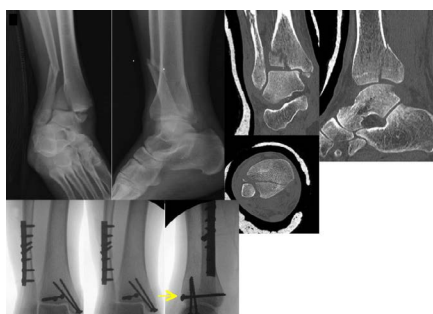
Figure 3. A variety of different approaches have been described for fixation of the posterior malleolus including the percutaneous anterior to posterior screws. It uses ligamentotaxis to reduce the posterior malleolus in the presence of an attached and intact PITFL. However this type of reduction cannot always ensure adequate articular reduction and malrotation correction in PMFs.



CC

In addition, it is difficult to find occult posterior malleolus fragments, due to the high fracture line variability and lack of regulation [8, 19]. Irwin et al., [5] also mentioned that many PMFs were underestimated or missed. This can lead to poor clinical outcomes through delays in appropriate operative management. Although pre-reduction radiographs for fractures that were dislocated/subluxed provide useful information regarding the possibility of sagittal or coronal instability, and the presence of syndesmotic injury, CT scans do not have images of lines overlapping and therefore show lesser accuracy for detection.

Three-dimensional imaging has been demonstrated to be a useful tool in the detection of occult fragments associated with tibial shaft fractures [20, 21]. Perioperative CT scans provide more appropriate assessment and visualisation of PMFs; perioperative use of CT scans may prompt identification of PMF type and assist in surgical decision-making around stabilisation [24]. They can detect the greatly varied fracture lines that X-rays cannot distinguish. Therefore CT scans are recommended, in combination with plain radiography, for the diagnosis and measurement of fragment size, articular impaction and comminution [5]. A further development of the PMF classification system is required to find a way of relating the different diagnostic tools and their results, at least the radiographs and CT scans.

In this study, we categorised PMFs in different fracture patterns, based on fracture development, as follows: Stage I: involved non-displaced PMFs with no syndesmotic diastasis, usually no sagittal plane instability (Type IA1 and 1A2). Stage II: PMF fragment hinged on PITFL shifting laterally with internal rotation of the distal fragment of the fibula, posterior aspect of syndesmosis, usually combined with sagittal or coronal plane instability (IB1 and IB2). Stage III: further supination-external rotation or pronation — external rotation plus axial forces causing rupture of the anterior inferior tibiofibular ligament (AITFL), distal fragment of fractured fibula shifting anteriorly or posteriorly on the sagittal plane, that could also be externally or internally rotated depending on the foot position at the end stage of the injury (as determined from CT scans for rotational profile of distal fibula). This stage is always combined with sagittal and/or coronal plane instability and syndesmosis injury (Type II category).

Tibial shaft fractures, commonly spiral low-energy fractures of the distal third of the tibia, are often associated with occult posterior malleolus fractures, though the exact prevalence is difficult to assess due to low detection rates. PMFs may be overlooked in this setting, while addressing the more obvious and painful tibial shaft fractures. Stuermer et al., [22] suggested that additional attention should be paid to the ankle in the presence of the following criteria: indirect traumas with a rotation component or pronation-eversion trauma, spiral fractures of the tibia in the distal third, and tibial shaft fractures, associated with a fracture of the fibula in the proximal third, or an intact fibula. Hou et al., [23] concluded that a CT or MRI should be conducted in this context after a detection rate as low as 32-64% was found only using plain radiographs. A “communication line” seen on plain radiographs, connecting the medial inferior apex of the spiral tibia fracture line with the posterior superior apex of the posterior malleolus fracture, may be a useful diagnostic clue [21]. Accordingly, we separated PMFs with diaphyseal fracture of ipsilateral tibia as Type III. These indications provide a guide to increasing diagnostic suspicion.

In the course of our analysis, we also looked at operative indications for surgical treatment of PMFs. Most orthopaedic surgeons consider two main indications for surgical fixation of the posterior malleolus, where the ankle is considered unstable and a posterior fragment larger than 25-33% of the articular surface of the plafond and/or greater than 2 mm displacement after fibular reduction [8, 13, 19, 27]. In the most recent meta-analysis no consensus was found in the literature regarding which sizes of fragments of PMFs should be fixed, as supported by Gardner et al., [27] who also observed great variation between surgeons [16]. Two authors found that fragments smaller than 25% needn't be fixed when anatomical reduction is acceptable, while Laungenhuijsen et al., [14] found that anatomical reduction should be achieved when the fragments are larger than 10% of the tibial articular surface [15, 20].

In addition to fragment sizes, PMFs lead to ankle instability and incongruity through PITFL disruption causing post-traumatic arthritis, as confirmed by Laungenhuijsen et al., and De Vries et al., in follow-up clinical studies of 6.9 and 13 years respectively [14, 15]. Incongruity associated changes in contact stress rates and incongruity-associated instability events may be important patho-mechanical determinants of post-traumatic arthritis [16]. The postero-anterior (sagittal plane) instability caused by PMFs, with secondary medial lateral instability (coronal plane), may be a far more important patho-mechanical cause of post-traumatic arthritis.

We emphasised in our analysis that ankle stability should be assessed using preoperative initial injury radiographs and intra-operative II images in decision-making about whether to operate on PMFs, because the fracture patterns were highly variable. Thus our stability-based PMF classification system, in addition to fragment sizes, identified a variety of types of PMFs and was more practical in guiding surgical decision making in the future, subject to further study.

In the course of our analysis, we also looked at which type of PMFs need syndesmotic fixation. In order to know whether or not we can avoid syndesmotic fixation with syndesmotic diastasis with PMFs, a random clinical trial with a long-term follow-up would be required. Such a study could have a huge impact on the management of syndesmotic diastasis with PMFs. However, this study shows that PMF fracture patterns are highly variable. Therefore the identification of similar fracture patterns is important.

Although syndesmotic injury itself can be treated by standard trans-syndesmotic fixation, although this has a high rate of syndesmotic mal-reduction (52%) [25], we believe that fixation of the posterior malleolus is biomechanically superior to syndesmotic screw fixation. Ogilvie-Harris et al's [6] cadaveric study support this idea. When Miller et al., [13] compared the functional outcomes of three groups with open posterior malleolus fixation, locked syndesmotic screws and combined fixation; he concluded that syndesmotic fixation through the posterior malleolus is at least equivalent to that with syndesmotic screw. Patients who receive a syndesmotic screw may undergo additional fixation of the posterior malleolus fragment; showing that 16-36% of syndesmotic screws may be unnecessary [26].

Methods of reduction do not always include internal fixation, showing the mechanism of ligamentotaxis can be effective in

maintaining joint congruity [14]. Harper's [28] cadaveric study has shown that if the fibula is in a stable anatomic position, no posterior talar subluxation will occur and therefore PMFs need not be fixed. Most avulsion fractures can be treated non-operatively with success. However, taking into account the biomechanics of the syndesmosis, Weening and Bhandari [26] recommend the fixation of all posterior malleolus fragments. This may be due to the superior syndesmotic stability obtained through fixation of the posterior malleolus over the use of trans-syndesmotic screw fixation, as demonstrated by Gardner et al's cadaveric study where fixation of the PMF restored 70% of syndesmotic stability compared with 40% through syndesmotic screw fixation [25]. Syndesmotic reduction plays a significant role in contributing to functional outcome as even minimal displacement may lead to post-traumatic arthritis [26, 29]. This suggests that anatomic reduction of all displaced PMFs can prevent posterior talar subluxation and restore articular congruency to minimise post-traumatic osteoarthritis and improve the prognosis of tri-malleolar fractures [30]. However, we found no consensus in the literature on the treatment of syndesmotic injury. We believe posterior malleolus fixation is more accurate and more stable than syndesmotic screw fixation. We are awaiting the long-term outcomes for those patients who have had anatomic reduction and fixation of the posterior malleolar fragment, without syndesmosis transfixation.

A variety of different approaches have been described for fixation of the posterior malleolus: the medial approach, postero-medial approach, poster-lateral lateral transmalleolar approach and the percutaneous anterior to posterior screws. We identified many factors such as the type and size of the PMF, ankle stability and the height of the fibular fracture line and these factors should be considered when choosing the best approach.

The most important factor to consider is the location of the fracture fragment because its deep position can be difficult to access. Incorrect approach often results in malrotation of the posterior malleolus, especially if reduction is not under direct vision.

The medial approach is suitable for the medial fragment. We found that approximately 32.5% of the posterior malleolus fracture lines extend into the medial malleolus (Type PMA and PL+PM). The medial approach through the posterior location of the tarsal tunnel may cause irritation to the structure in the tunnel, especially the tibialis posterior tendon. It would be helpful to consider the postero-lateral approach as a workhorse of PMF fixation treatment, frequently used both in literature and the present study.

The traditional method for fixation of the posterior malleolus utilises the anterior approach, using indirect reduction and an anteroposterior screw. It uses ligamentotaxis to reduce the posterior malleolus, in the presence of an attached and intact PITFL [26] (Figure 3). However this type of reduction cannot always ensure adequate articular reduction and malrotation correction in PMFs.

Bois and Dust's [33] retrospective study demonstrated the satisfactory short and mid-term clinical results of a postero-medial approach technique. Based on our observation, we also recommend a postero-medial approach, particularly, we emphasise the approach without disturbing the tibialis posterior tendon: subperiosteal dissection of the postero-medial fragment, proceeding to elevate the tibialis posterior tendon sheath with periosteum together, while retracting laterally to expose the posterior malleolus

fragment, allowing a screw fixation with countersink. Repair of the periosteum was meticulously performed at the end of surgery (Figure 2). The postero-medial approach is suitable for large postero-medial biased fragments, which allow fixation of the posterior and medial malleoli from the same incision. The skin incision follows the postero-medial border of the distal tibia and medial malleolus, and continues in line with the tibialis posterior tendon, toward the talonavicular joint.

However this approach limits visualisation of the posterior-lateral malleolus fragment, and an additional posterolateral approach may be required if the posterior malleolus is split into two parts medially and laterally, as we described. This direct reduction and fixation of the posterior lateral malleolus, using a postero-lateral approach, allows appropriate visualisation and stable fixation, with studies demonstrating satisfactory clinical outcomes [34, 35]. The longitudinal skin incision is made above the interval between the posterior border of the fibula and the lateral border of the Achilles tendon. The posterior malleolus fragment is accessed and fixed via the interval between the peroneus brevis and flexor hallucis longus. This incision has the added benefit of allowing simultaneous reduction and fixation of the lateral malleolus.

In terms of fixation method, it seems both anti-glide plate fixation and screw only fixation can achieve equally rigid fixation. We used at least three cannulated screws in a triangle configuration, as recommended in the fixation of the neck of femur fractures [36]. However, a biomechanical study is required to confirm this claim. The buttress plate maintains reduction, prevents superior migration of the fragment and can be placed in the intramuscular plane, through the postero-lateral approach, thus causing less irritation. Excessively large or crushed fragments can be fixed with screws in combination with the buttress plate with external fixation or traction used, as required.

Conclusion

PMFs appear to be highly variable. We identified certain types of PMFs which we can categorise. Ankle stability in the coronal and sagittal planes on initial injury radiographs, intra-operative II and preoperative CT scans are critical in order to identify different PMF patterns. Variable PMF patterns complicate assessment of sagittal stability and the articular congruity in the surgical decision making process, therefore a classification system is needed to accurately describe PMF types encountered in clinical practice, to provide a desirable guide for best practice surgical management.

References

- [1]. Koval KJ, Lurie J, Zhou W, Sparks MB, Cantu RV, et al., (2005) Ankle fractures in the elderly: what you get depends on where you live and who you see. *Journal of Orthopaedic Trauma*. 19(9): 635-639.
- [2]. Court-Brown CM, McBirnie J, Wilson G (1998) Adult ankle fractures — an increasing problem? *Acta Orthopaedica Scandinavica*. 69(1): 43-47.
- [3]. Kukkonen J, Heikkilä JT, Kyyronen T, Mattila K, Gullichsen E, et al., (2006) Posterior malleolar fracture is often associated with spiral tibial diaphyseal fracture: a retrospective study. *The Journal of Trauma*. 60(5): 1058-1060.
- [4]. Boraiah S, Gardner MJ, Helfet DL, Dean G, Lorich (2008) High association of posterior malleolus fractures with spiral distal tibial fractures. *Clinical Orthopaedics and Related Research*. 466(7): 1692-1698.
- [5]. Irwin TA, Lien J, Kadakia AR (2013) Posterior malleolus fracture. *The Journal of the American Academy of Orthopaedic Surgeons*. 21(1): 32-40.
- [6]. Ogilvie-Harris DJ, Reed SC, Hedman TP (1994) Disruption of the ankle syndesmosis: biomechanical study of the ligamentous restraints. *Arthro-*

- copy: the Journal of Arthroscopic & Related Surgery : official publication of the Arthroscopy Association of North America and the International Arthroscopy Association. 10(5): 558-560.
- [7]. Drijfhout van Hooff CC, Verhage SM, Hoogendoorn JM (2015) Influence of Fragment Size and Postoperative Joint Congruency on Long-Term Outcome of Posterior Malleolar Fractures. *Foot & Ankle International*. 36(6): 673-678.
 - [8]. Haraguchi N, Haruyama H, Toga H, Kato F(2006) Pathoanatomy of posterior malleolar fractures of the ankle. *The Journal of Bone and Joint Surgery, American*. 88(5): 1085-1092.
 - [9]. Danis R. Les fractures malleolaires. In: Danis R, (ed.). *Theorie et pratique de l'osteosynthese*. Paris: Masson, 1949.
 - [10]. Weber BG. *Die verletzungen des oberen sprunggelenkes*. 2nd ed. Berne: Verlag Hans Huber. 1972.
 - [11]. Laugel-Hansen N (1950) Fractures of the ankle. II. Combined experimental-surgical and experimental-roentgenologic investigations. *Archives of Surgery*. 60(5): 957-985.
 - [12]. Hermans JJ, Beumer A, de Jong TA, Kleinrensink GJ (2010) Anatomy of the distal tibiofibular syndesmosis in adults: a pictorial essay with a multimodality approach. *Journal of Anatomy*. 217(6): 633-645.
 - [13]. Miller AN, Carroll EA, Parker RJ, David L, Helfet, Dean G, Lorich (2010) Posterior malleolar stabilization of syndesmotic injuries is equivalent to screw fixation. *Clinical Orthopaedics and Related ERsearch* 468(4): 1129-1135.
 - [14]. Langenhuijsen JE, Heetveld MJ, Ultee JM, Steller EP, Butzelaar RM (2002) Results of ankle fractures with involvement of the posterior tibial margin. *The Journal of Trauma*. 53(1): 55-60.
 - [15]. De Vries JS, Wijgman AJ, Sierevelt IN, Schaap GR (2005) Long-term results of ankle fractures with a posterior malleolar fragment. *The Journal of Foot and Ankle Surgery : official publication of the American College of Foot and Ankle Surgeons*. 44(3): 211-217.
 - [16]. van den Bekerom MP, Haverkamp D, Kloen P (2009) Biomechanical and clinical evaluation of posterior malleolar fractures. A systematic review of the literature. *The Journal of Trauma*. 66(1): 279-284.
 - [17]. Neumaier Probst E, Maas R, Meenen NM (1997) Isolated fracture of the posterolateral tibial lip (Volkman's triangle). *Acta Radiologica*. 38(3): 359-362.
 - [18]. Ebraheim NA, Mekhail AO, Haman SP (1999) External rotation-lateral view of the ankle in the assessment of the posterior malleolus. *Foot & Ankle International*. 20(6): 379-383.
 - [19]. Papachristou G, Efsthopoulos N, Levidiotis C, Chronopoulos E (2003) Early weight bearing after posterior malleolar fractures: an experimental and prospective clinical study. *The Journal of Foot and Ankle Surgery : official publication of the American College of Foot and Ankle Surgeons*. 42(2): 99-104.
 - [20]. Katioz H, Bombaci H, Gorgec M (2003) Treatment of trimalleolar fractures. Is osteosynthesis needed in posterior malleolar fractures measuring less than 25% of the joint surface? *Acta Orthopaedica et Traumatologica Turcica* . 37(4): 299-303.
 - [21]. Hou Z, Zhang L, Zhang Q, Shuangquan Yaoemail, Jinshe Panemail, et al., (2012) The "communication line" suggests occult posterior malleolar fracture associated with a spiral tibial shaft fracture. *European Journal of Radiology*. 81(3): 594-597.
 - [22]. Stuermer EK, Stuermer KM (2008) Tibial shaft fracture and ankle joint injury. *Journal of Orthopaedic Trauma*. 22(2): 107-112.
 - [23]. Hou Z, Zhang Q, Zhang Y, Li S, Pan J, et al., (2009) A occult and regular combination injury: the posterior malleolar fracture associated with spiral tibial shaft fracture. *The Journal of Trauma*. 66(5): 1385-1390.
 - [24]. Purnell GJ, Glass ER, Altman DT, Sciulli RL, Muffly MT, et al., (2011) Results of a computed tomography protocol evaluating distal third tibial shaft fractures to assess noncontiguous malleolar fractures. *The Journal of Trauma*. 71(1): 163-168.
 - [25]. Gardner MJ, Demetrakopoulos D, Briggs SM, Helfet DL, Lorich DG (2006) Malreduction of the tibiofibular syndesmosis in ankle fractures. *Foot & Ankle International*. 27(10): 788-792.
 - [26]. Weening B, Bhandari M (2005) Predictors of functional outcome following transsyndesmotic screw fixation of ankle fractures. *Journal of Orthopaedic Trauma*. 19(2): 102-108.
 - [27]. Gardner MJ, Streubel PN, McCormick JJ, Sandra E. Klein, MD, Jeffrey E. Johnson, et al., (2011) Surgeon practices regarding operative treatment of posterior malleolus fractures. *Foot & Ankle International*. 32(4): 385-393.
 - [28]. Harper MC (1989) Posterior instability of the talus: an anatomic evaluation. *Foot & Ankle* 10(1): 36-39.
 - [29]. Macko VW, Matthews LS, Zwirkoski P, Goldstein SA (1991) The joint-contact area of the ankle. The contribution of the posterior malleolus. *The Journal of Bone and Joint Surgery, American volume*. 73(3): 347-351.
 - [30]. Jaskulka RA, Ittner G, Schedl R (1989) Fractures of the posterior tibial margin: their role in the prognosis of malleolar fractures. *The Journal of Trauma*. 29(11): 1565-1570.
 - [31]. Pakarinen H (2012) Stability-based classification for ankle fracture management and the syndesmosis injury in ankle fractures due to a supination external rotation mechanism of injury. *Acta Orthopaedica Supplementum*. 83(347): 1-26.
 - [32]. Donken CC, Goorden AJ, Verhofstad MH, Edwards MJ, van Laarhoven CJ (2011) The outcome at 20 years of conservatively treated 'isolated' posterior malleolar fractures of the ankle: a case series. *The Journal of Bone and Joint Surgery, British volume*. 93(2): 1621-5.
 - [33]. Bois AJ, Dust W (2008) Posterior fracture dislocation of the ankle: technique and clinical experience using a posteromedial surgical approach. *Journal of Orthopaedic Trauma* 22(9): 629-636.
 - [34]. Xu HL, Wang TB, Chen JH, et al., (2012) Bioabsorbable screws for the treatment of fractures of ankle joint. *Chin J Orthop Trauma* 14: 113-116.
 - [35]. Carmont MR, Davies MB (2008) Buttress plate stabilisation of posterior malleolar ankle fractures: a familiar technique through an unfamiliar approach. *Curr Orthop* 22(5): 359-364.
 - [36]. Yang JJ, Lin LC, Chao KH, et al., (2013) Risk factors for nonunion in patients with intracapsular femoral neck fractures treated with three cannulated screws placed in either a triangle or an inverted triangle configuration. *JBJS (Am)* 95(1): 61-69.